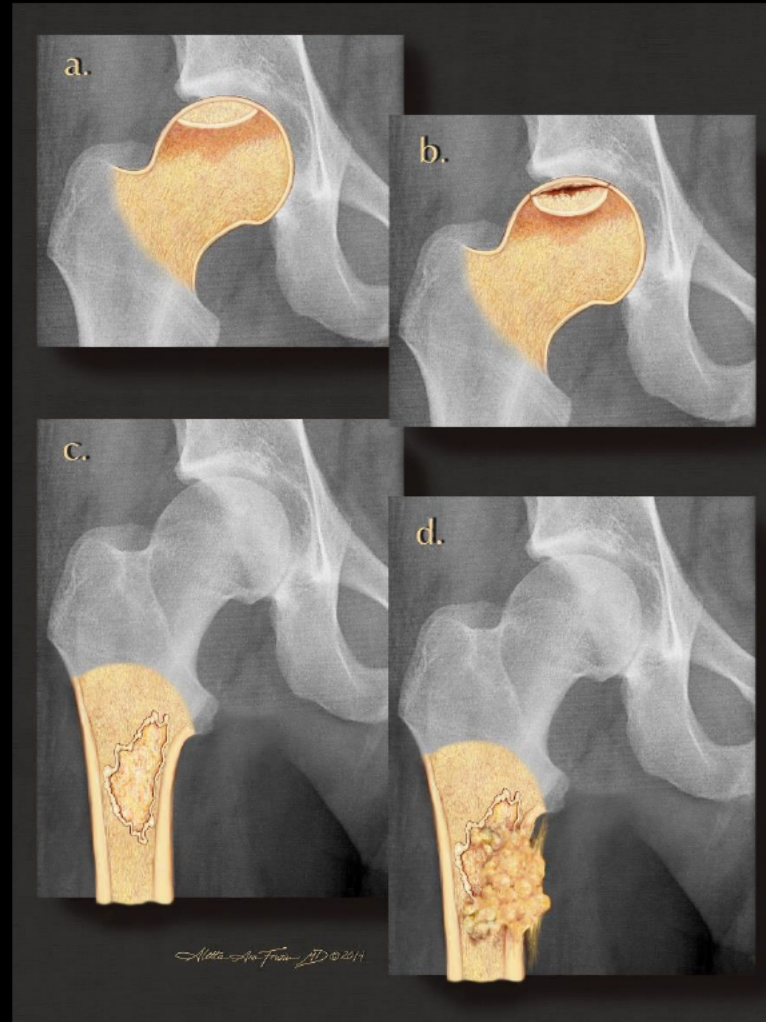


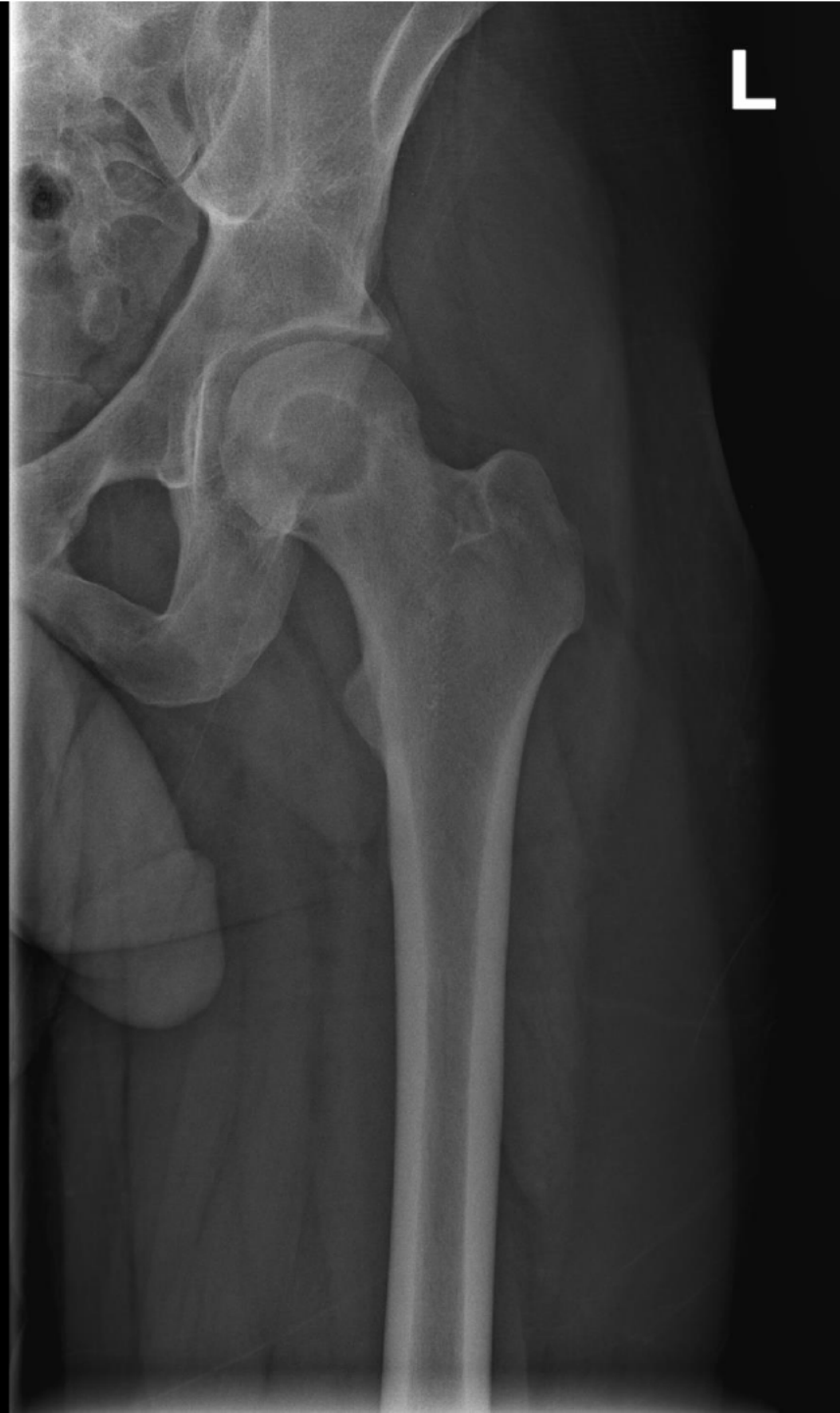# Musculoskeletal Best Case

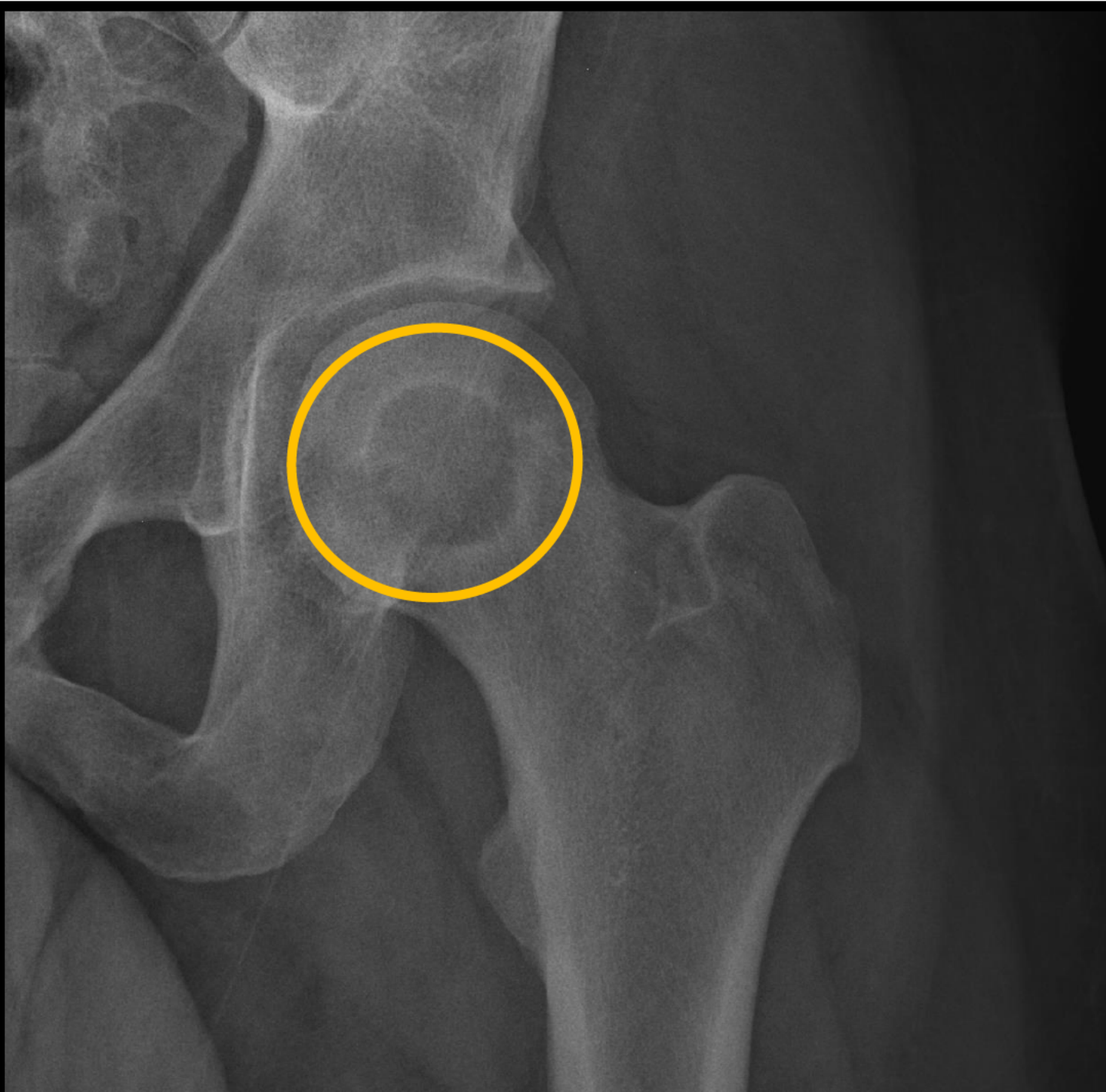


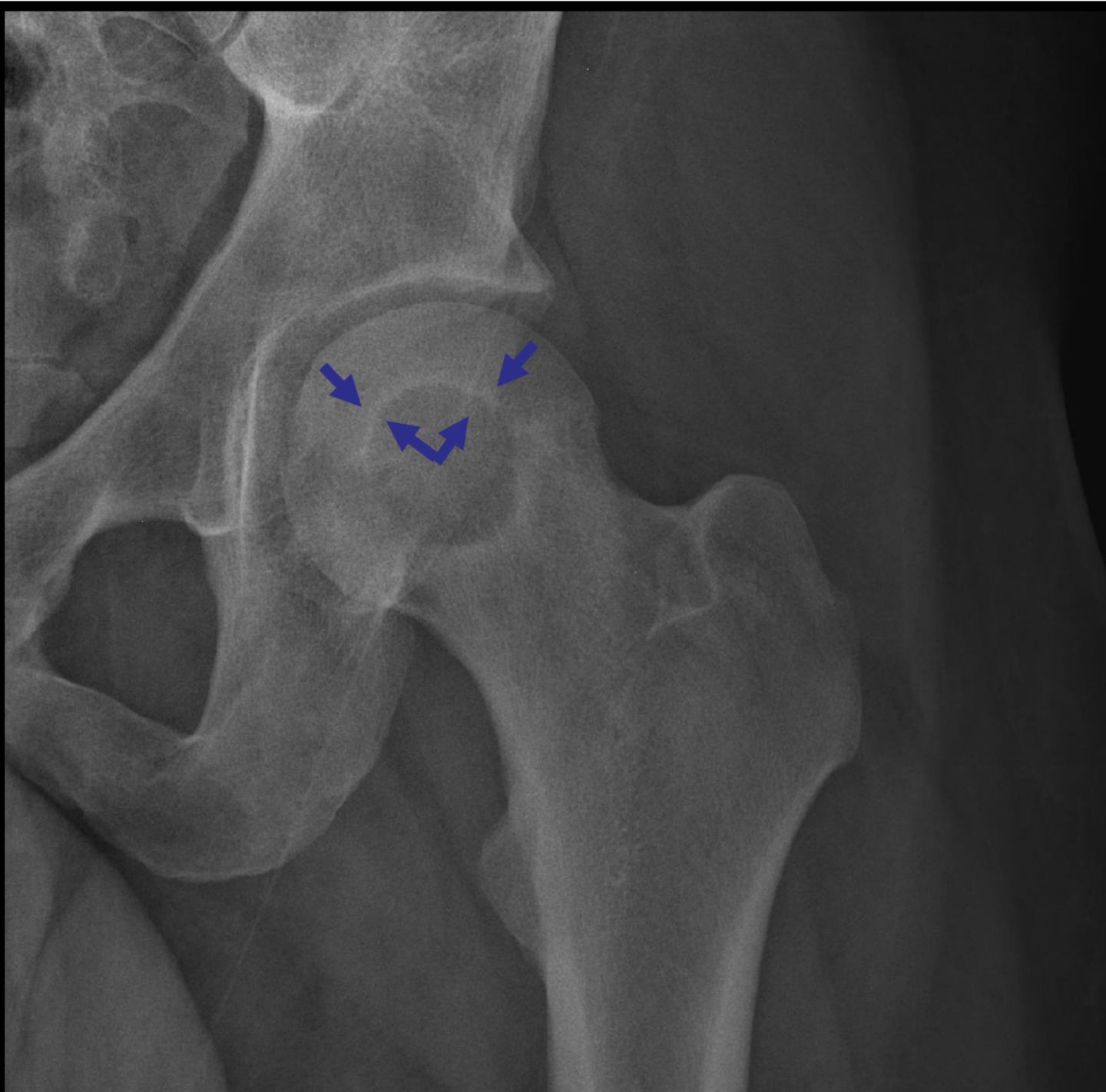
# Clinical information

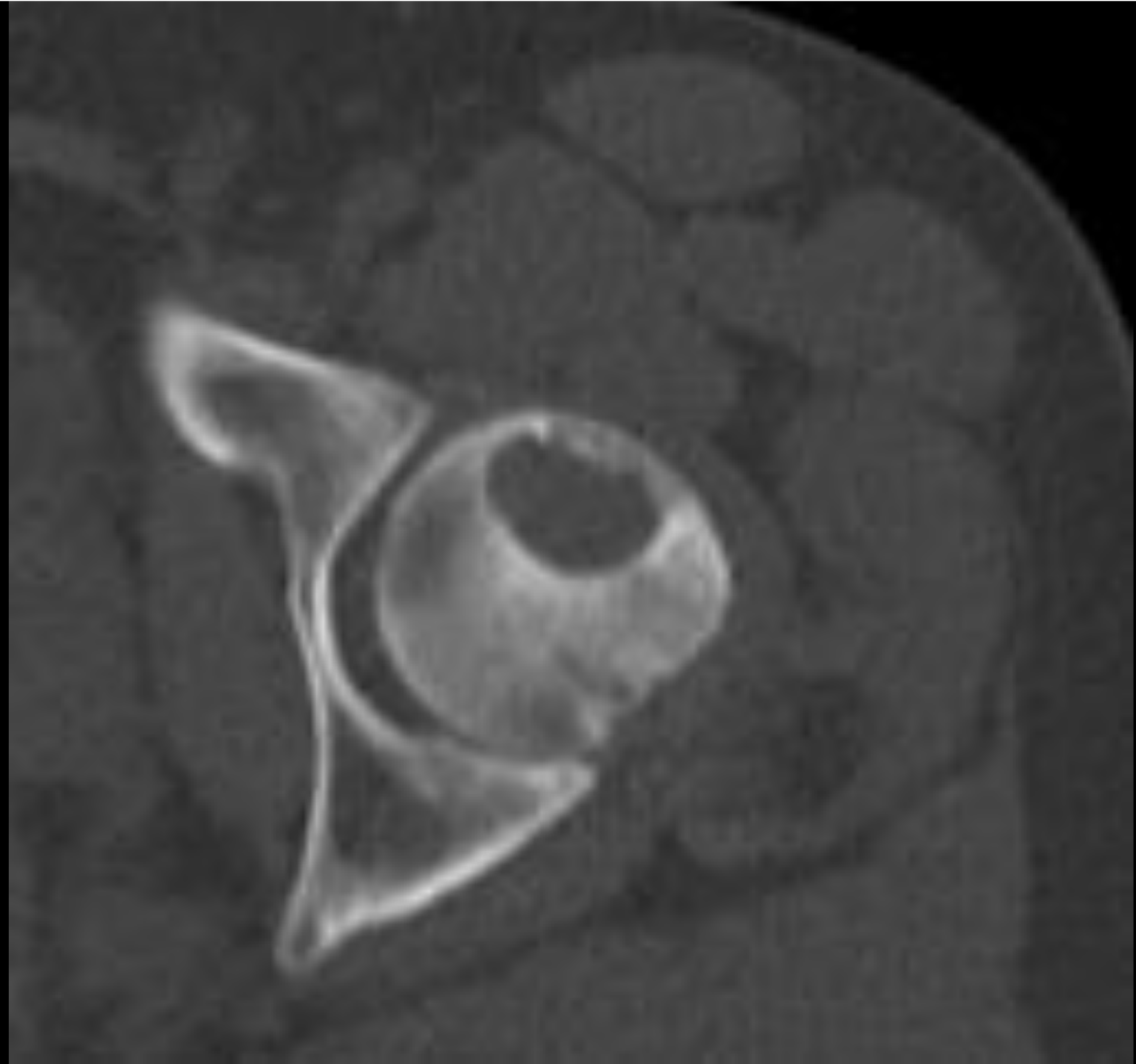
**36-year-old male with progressively worsening left hip pain**

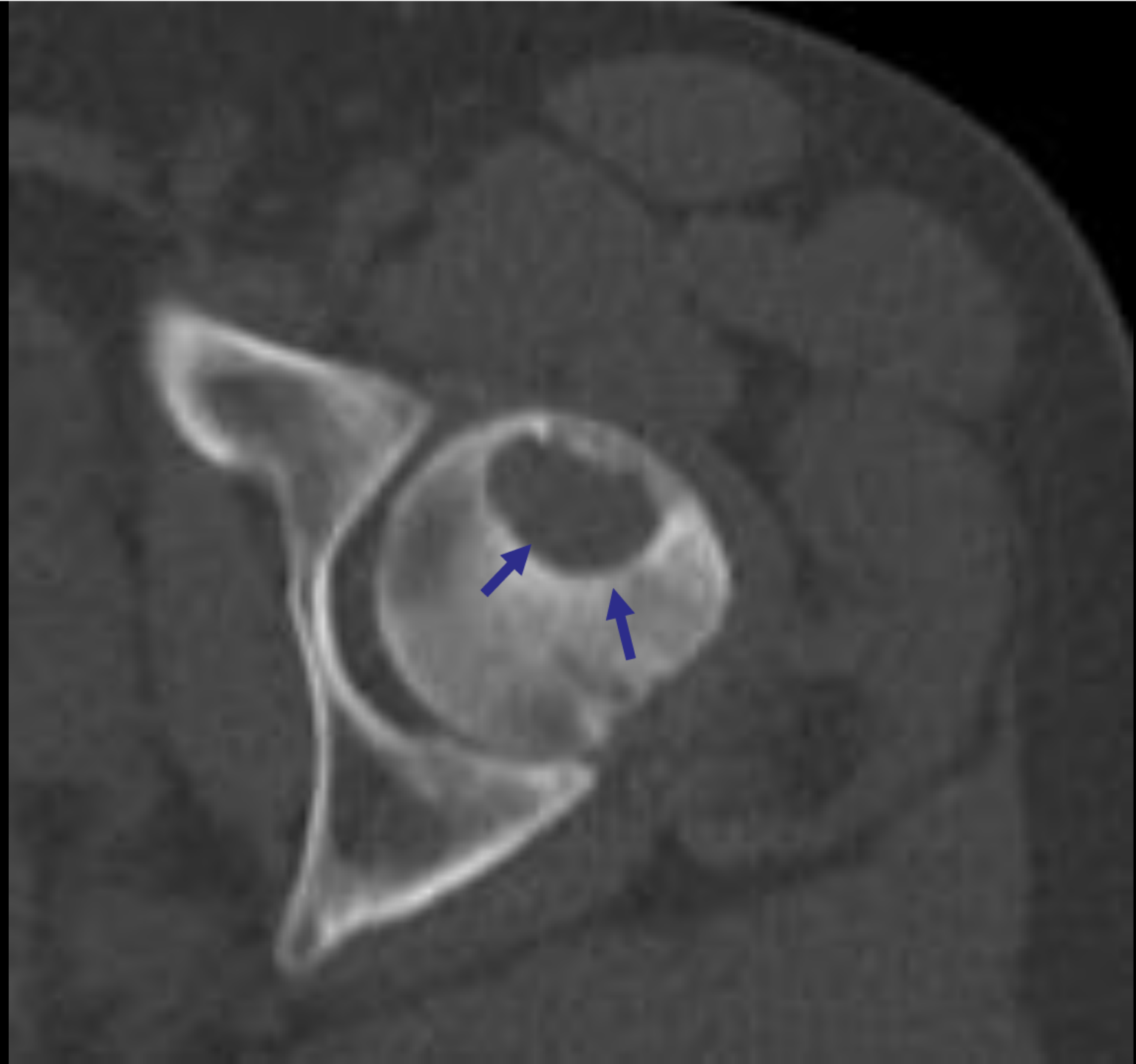


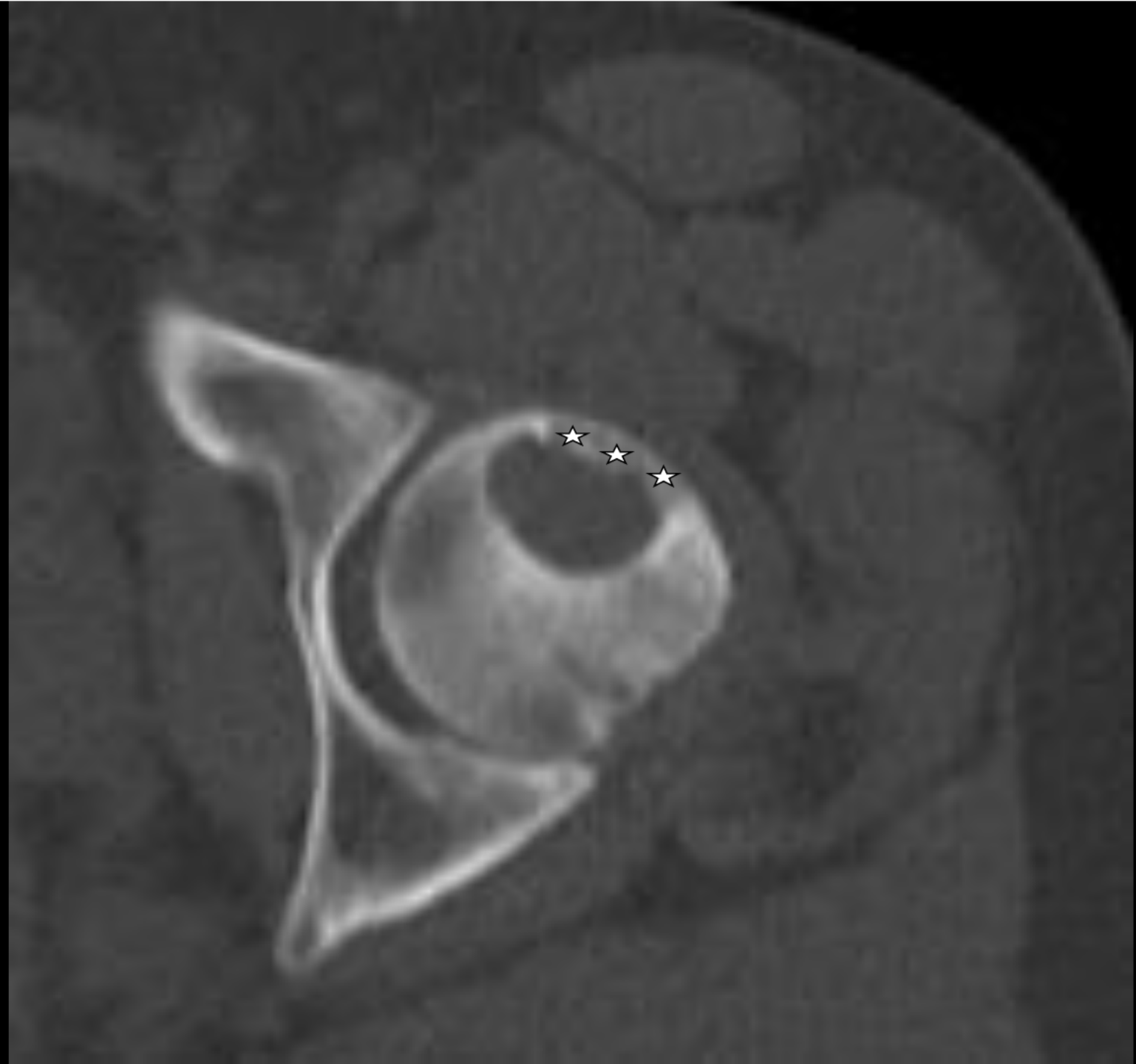






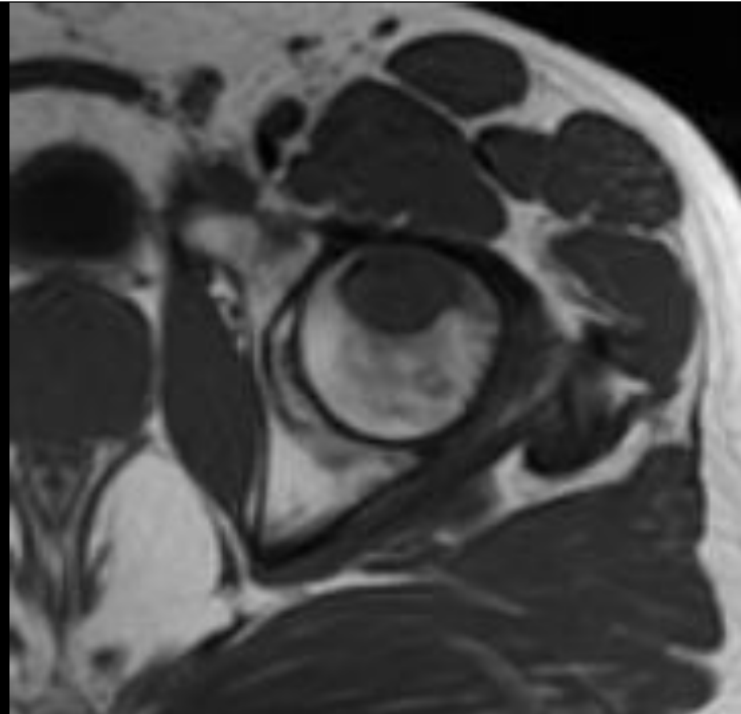




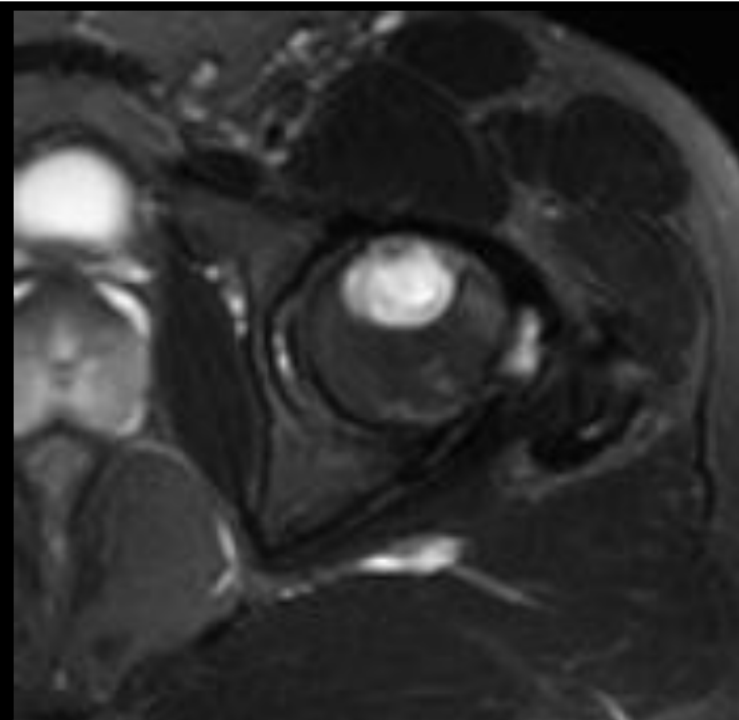




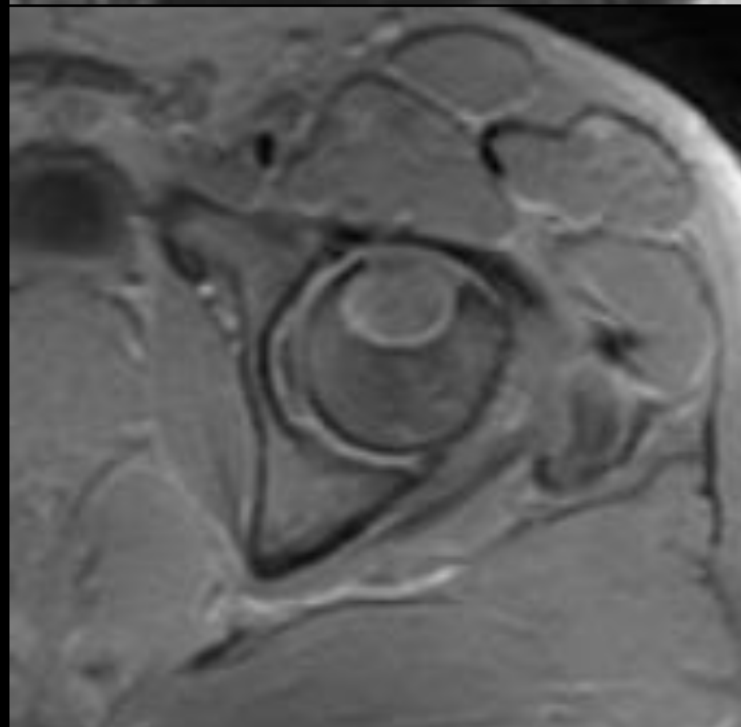
**Axial T1**



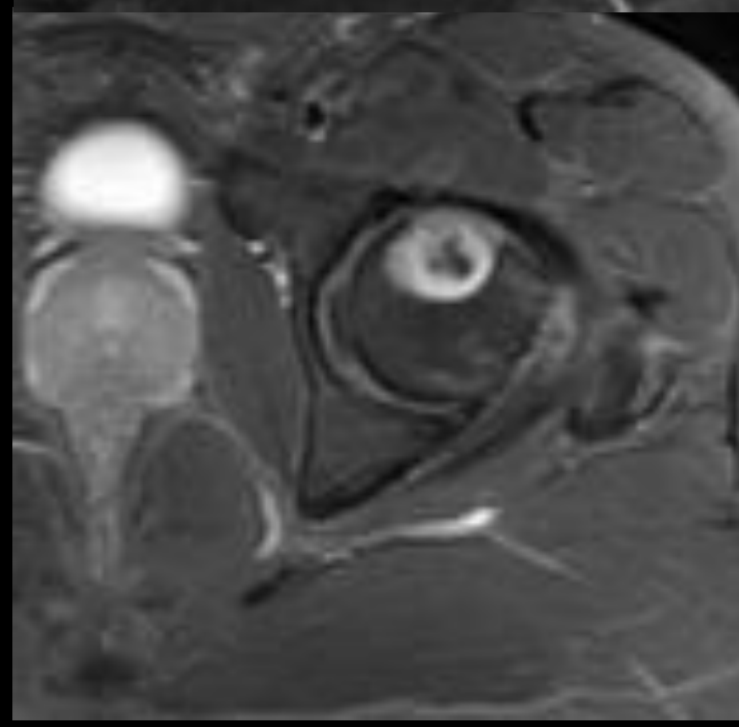
**Axial T2FS**



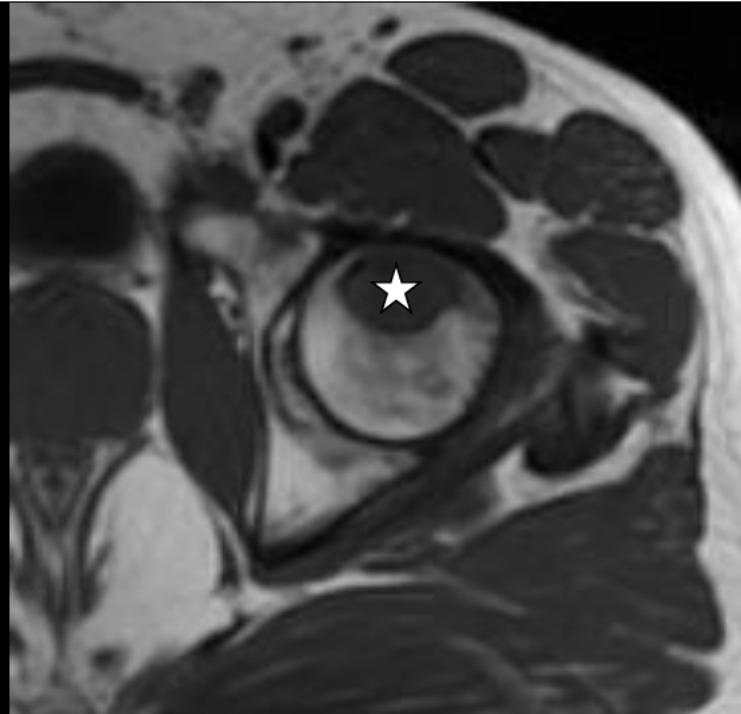**Axial T1 FS**



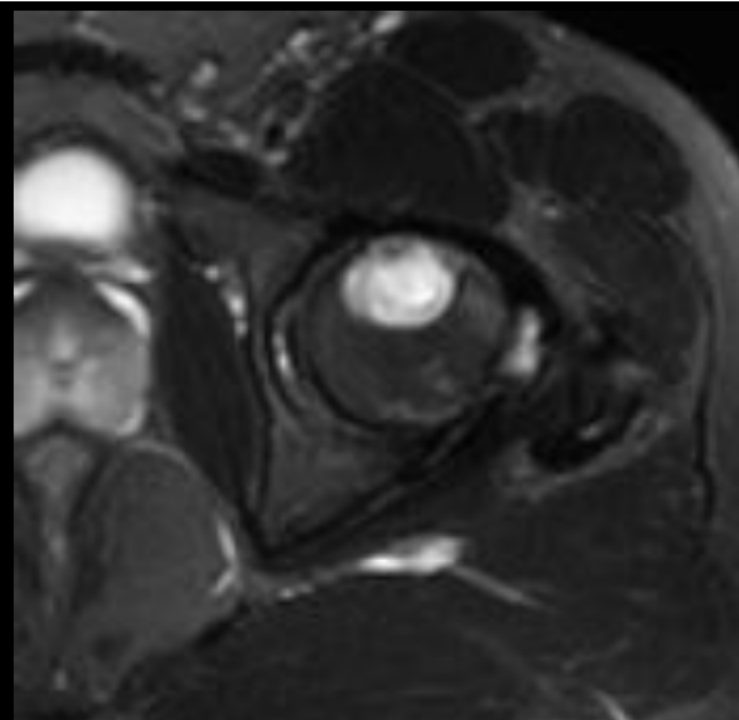
**Axial T1 FS post**



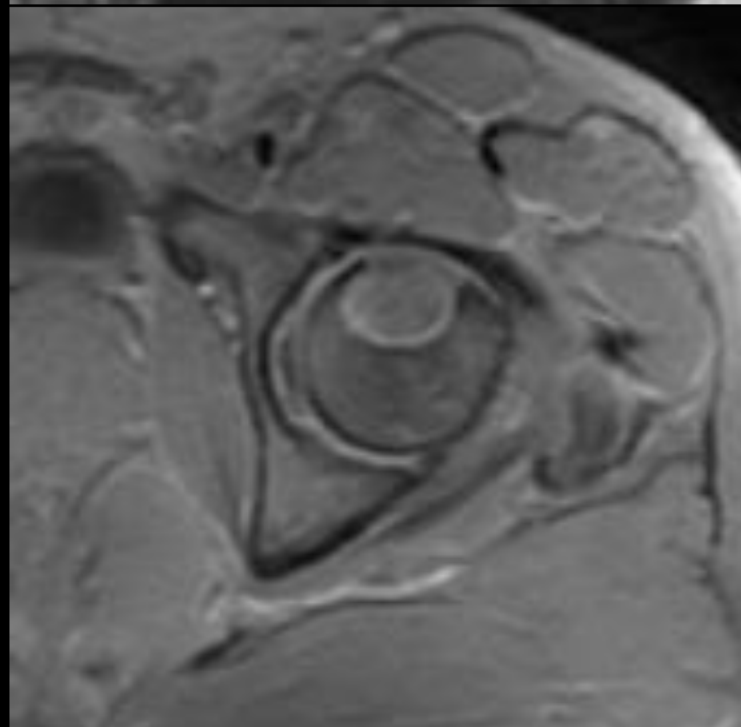
**Axial T1**



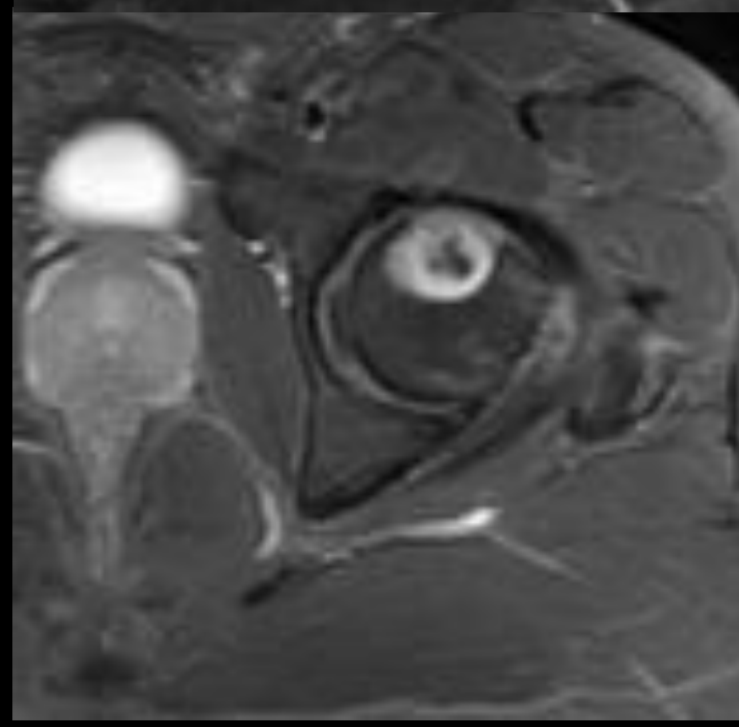
**Axial T2FS**



**Axial T1 FS**

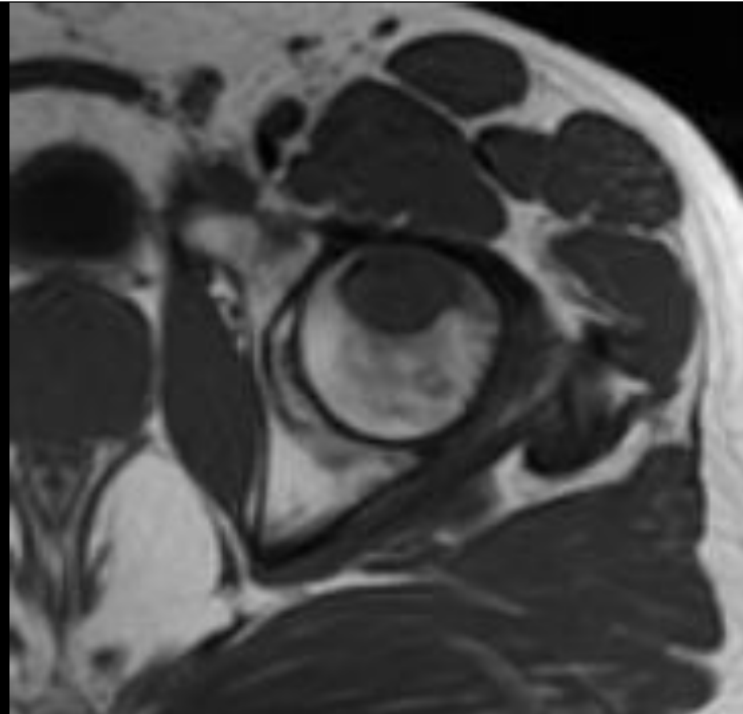


**Axial T1 FS post**

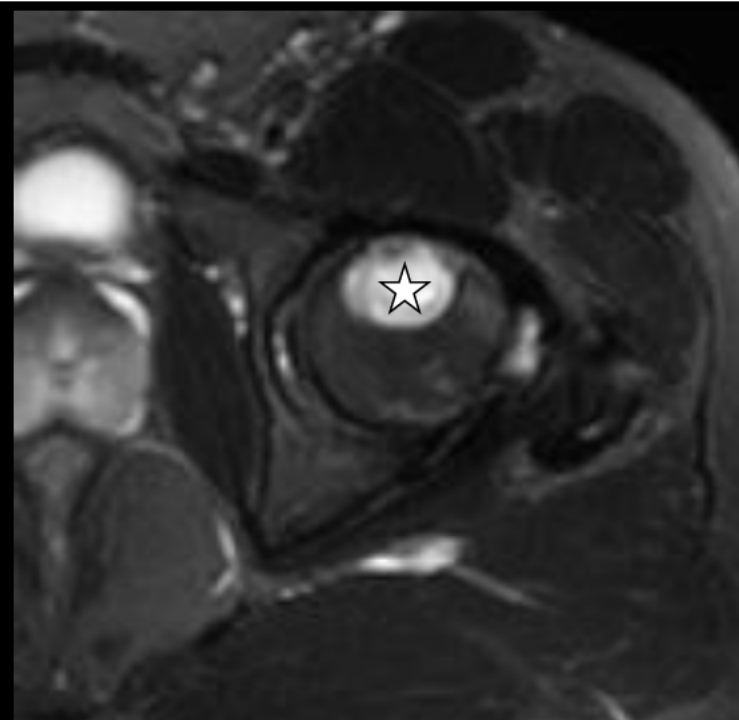




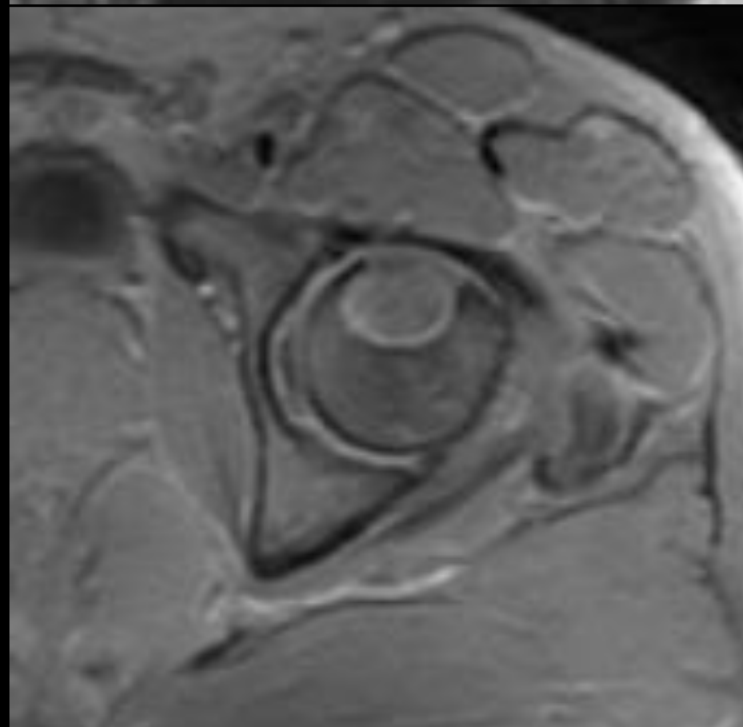
**Axial T1**



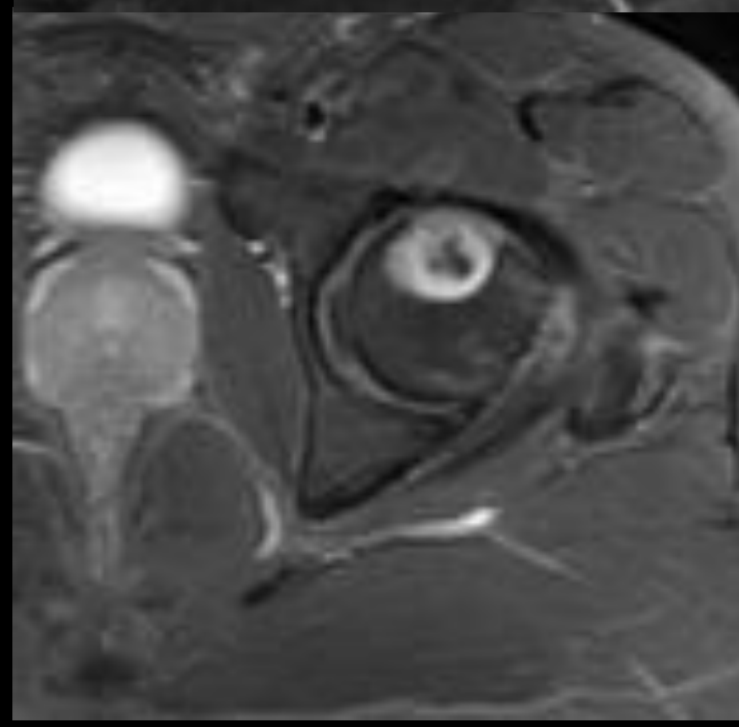
**Axial T2FS**



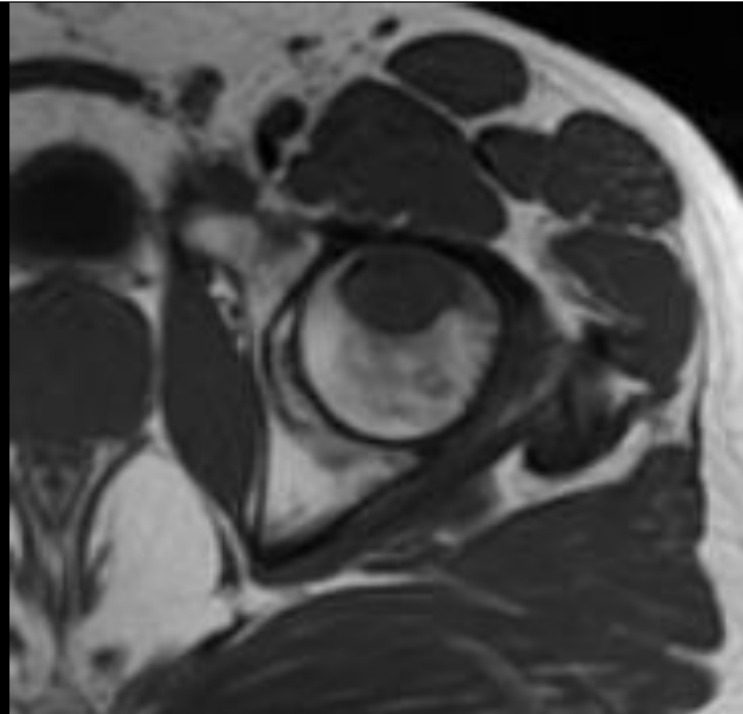
**Axial T1 FS**



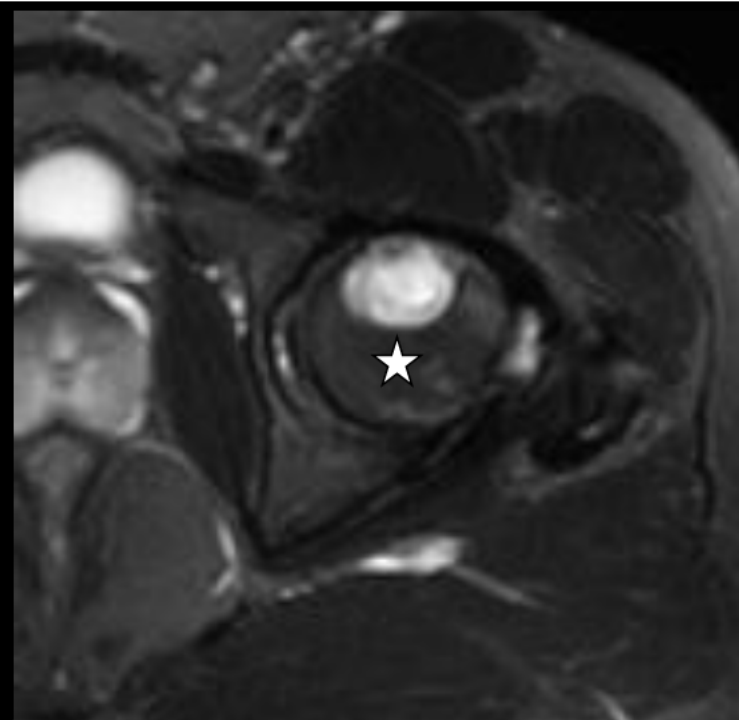
**Axial T1 FS post**



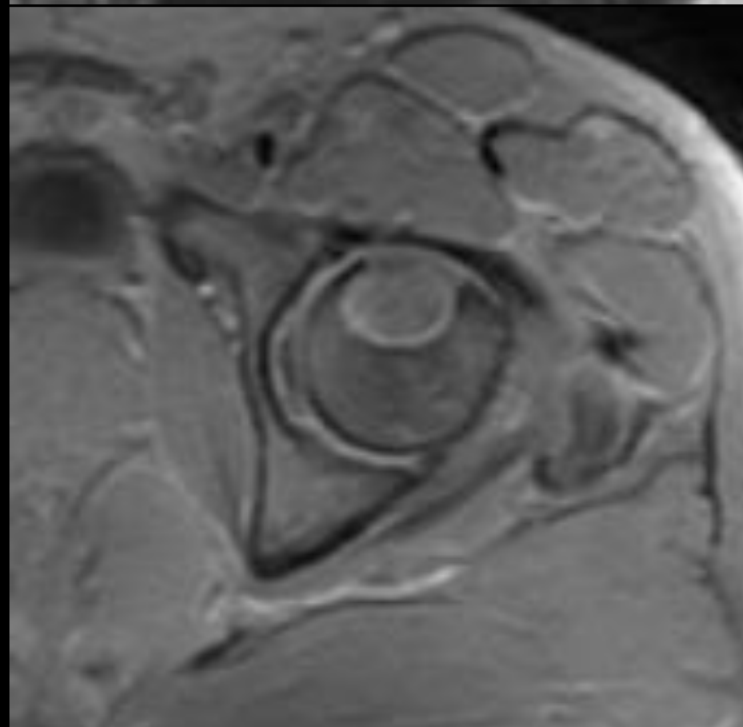
**Axial T1**



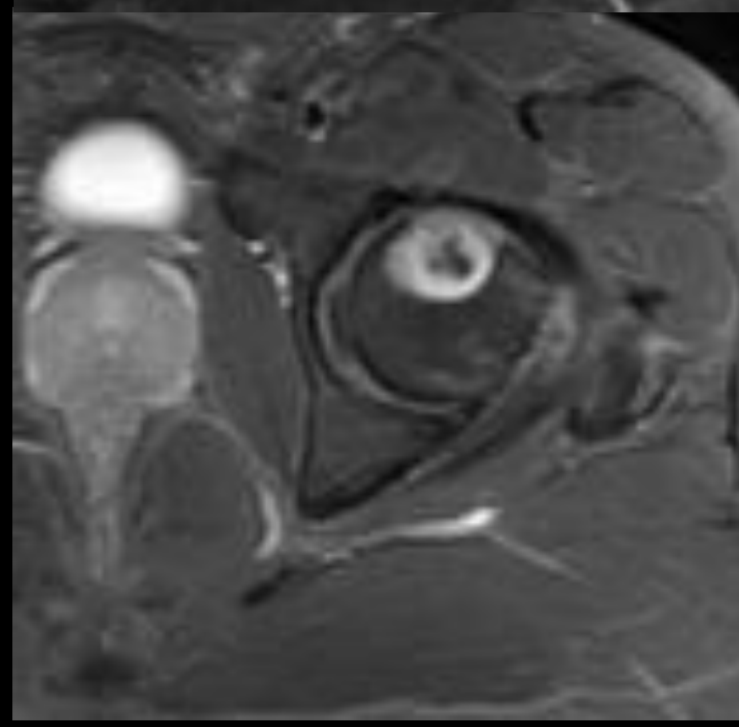
**Axial T2FS**



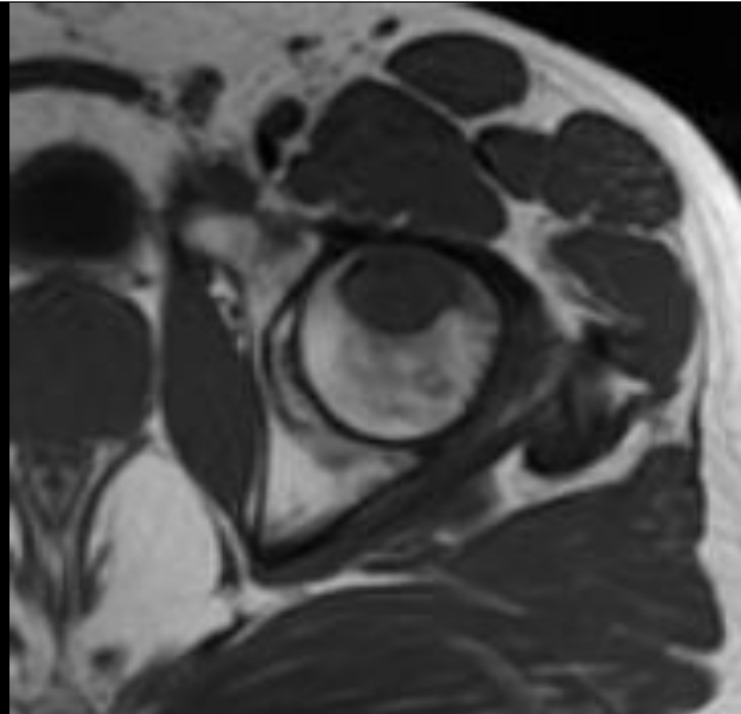
**Axial T1 FS**



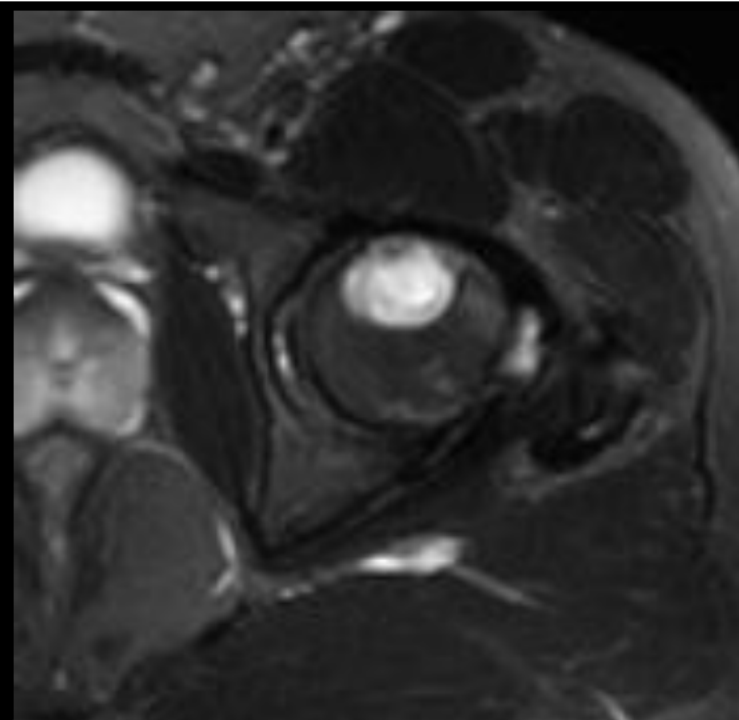
**Axial T1 FS post**



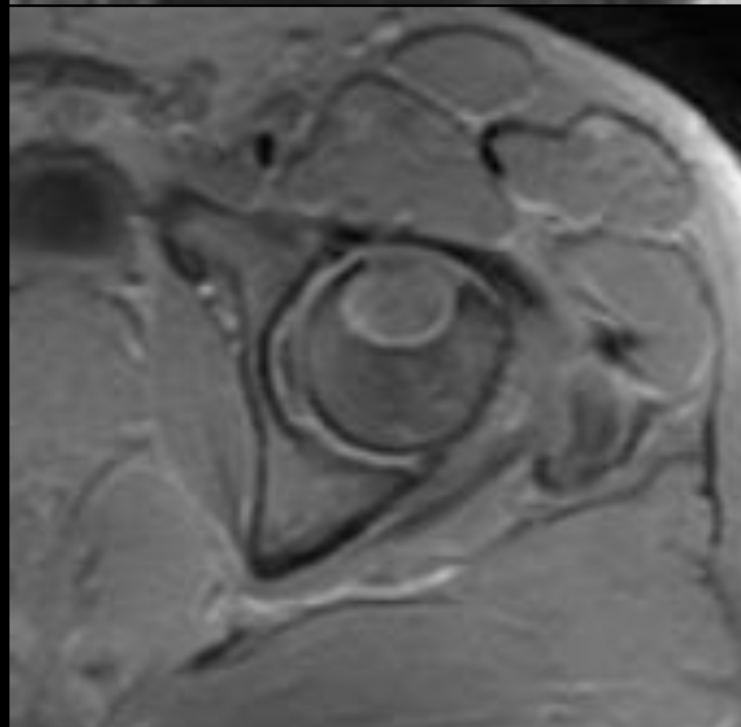
**Axial T1**



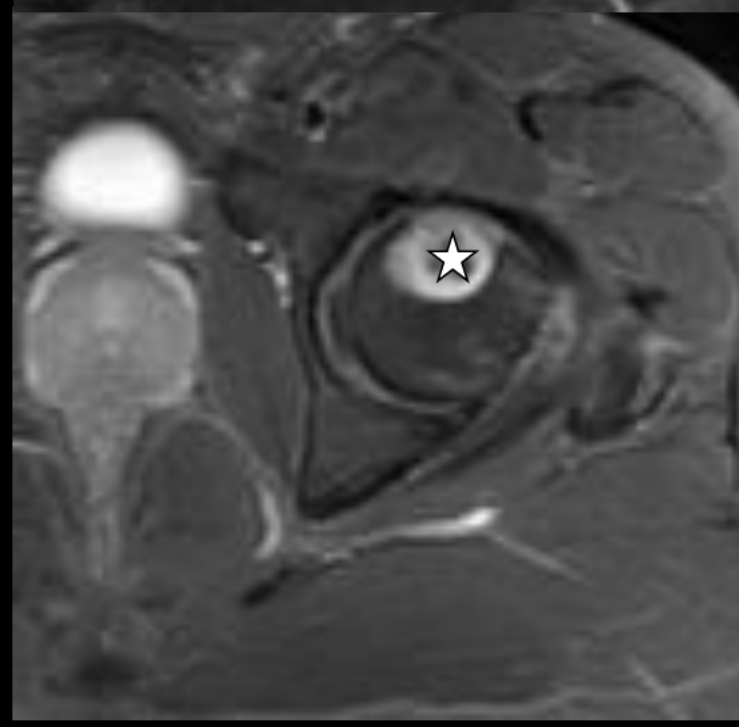
**Axial T2FS**

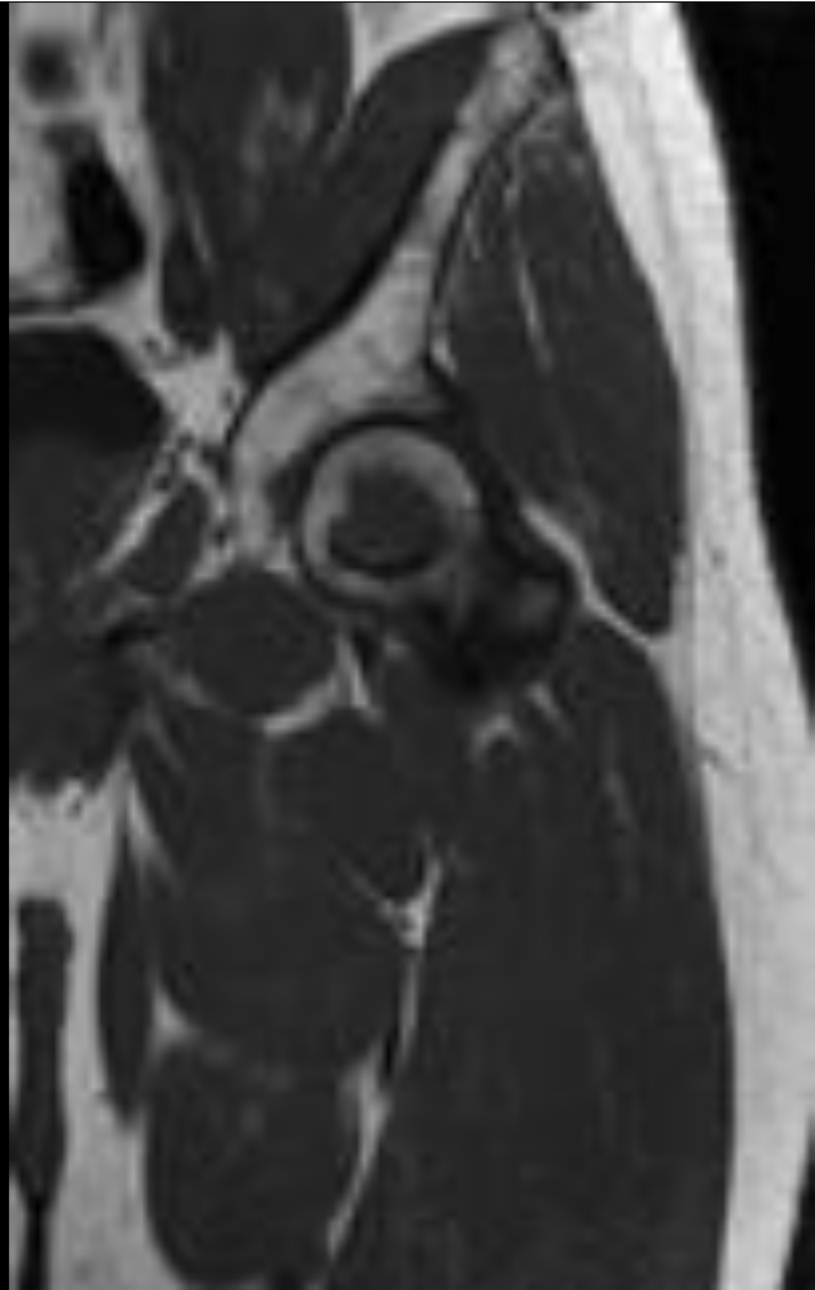

**Axial T1 FS**

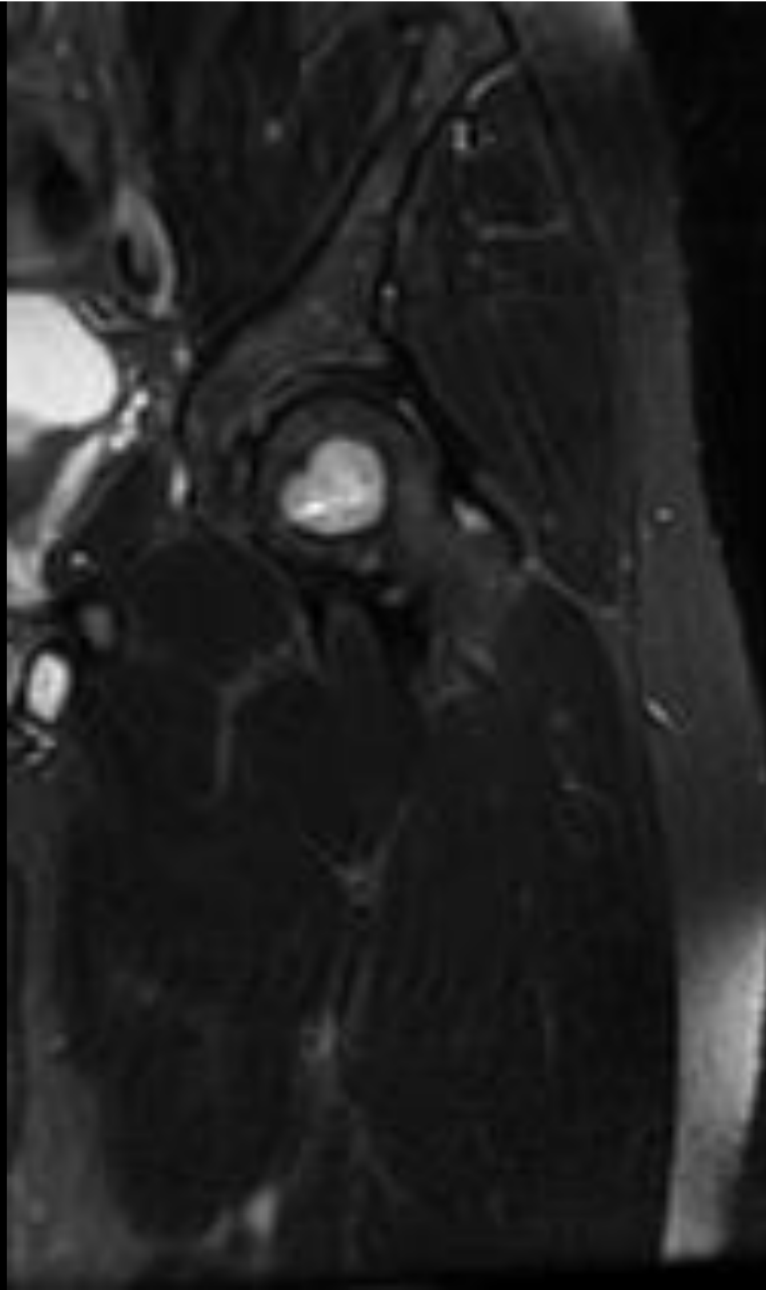


**Axial T1 FS post**

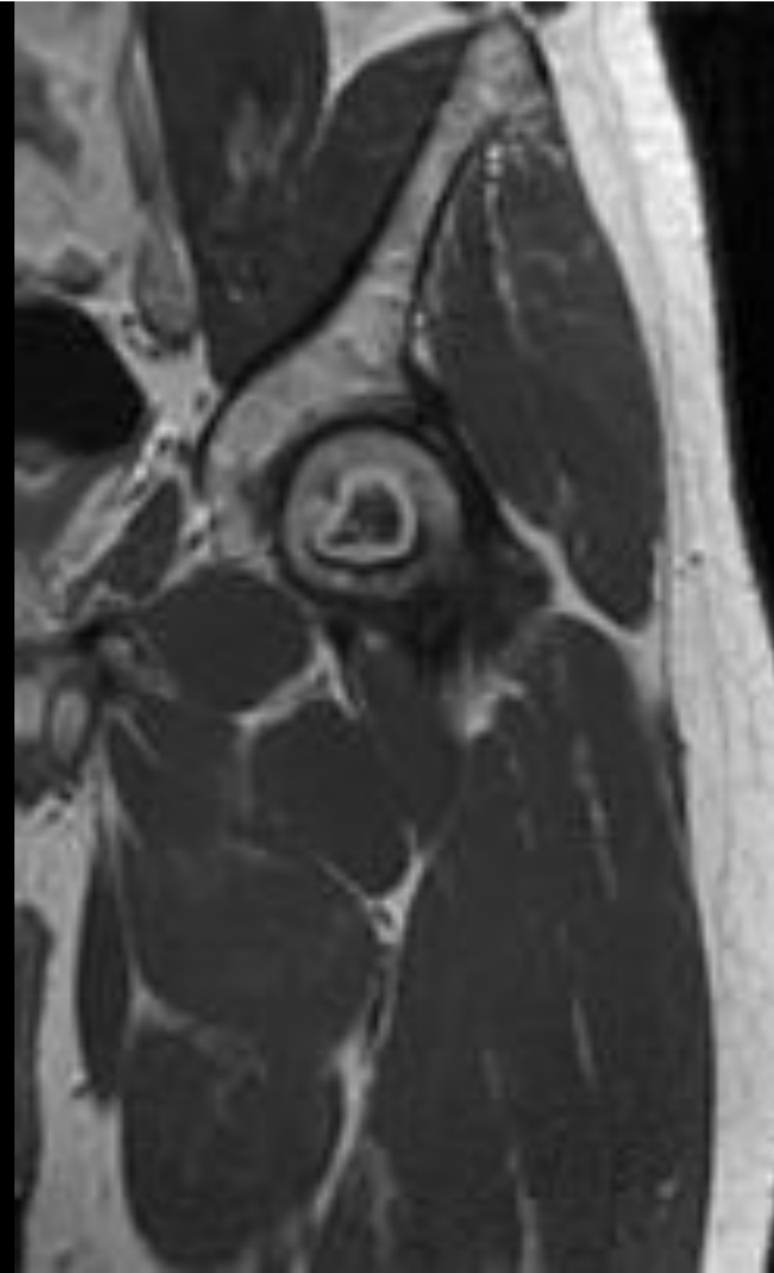




**Coronal T1**

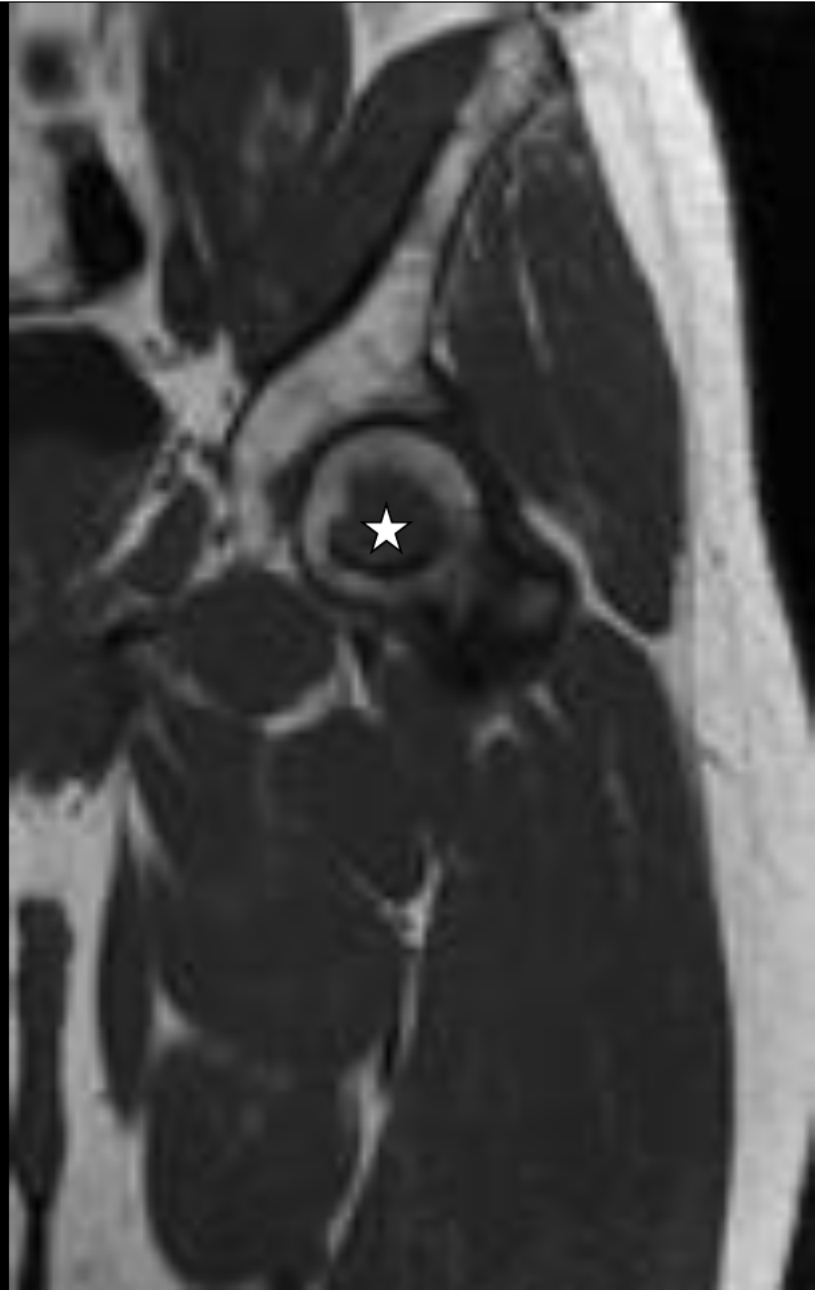

**Coronal T2FS**

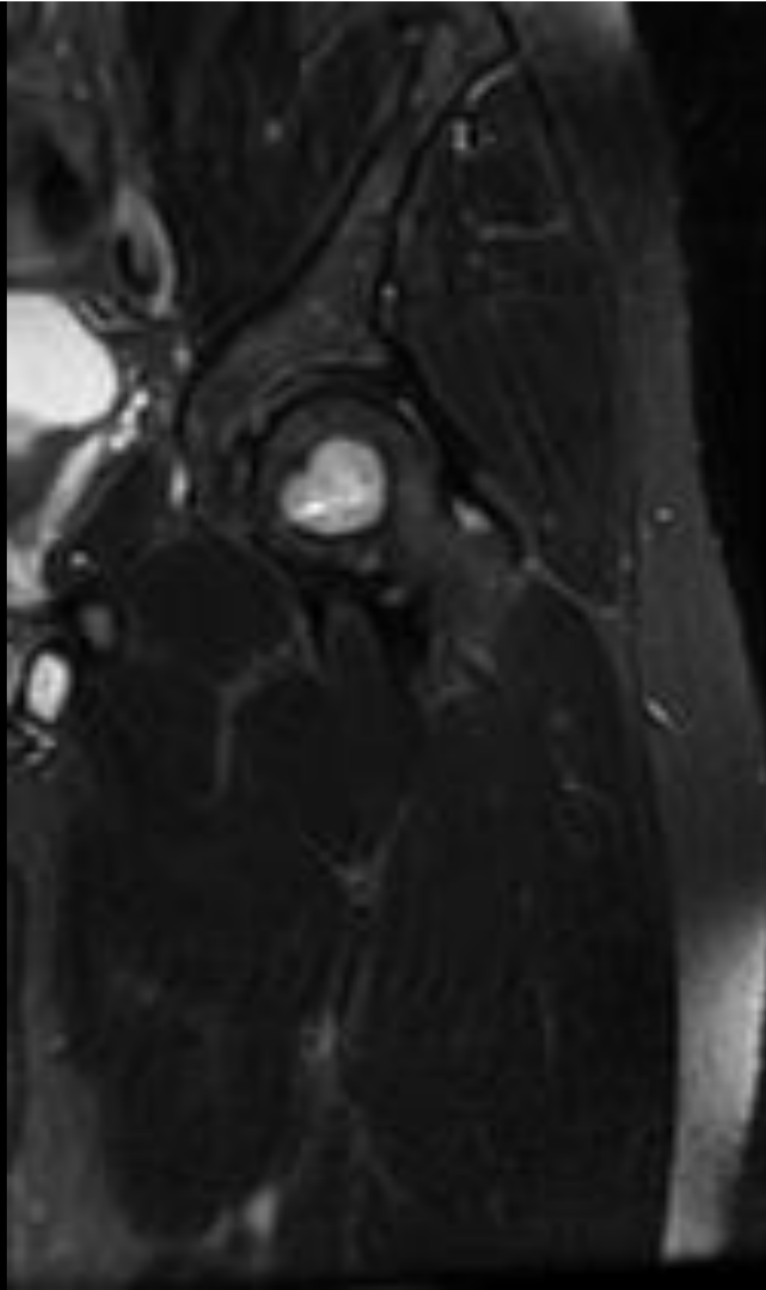


**Coronal T1FS +C**

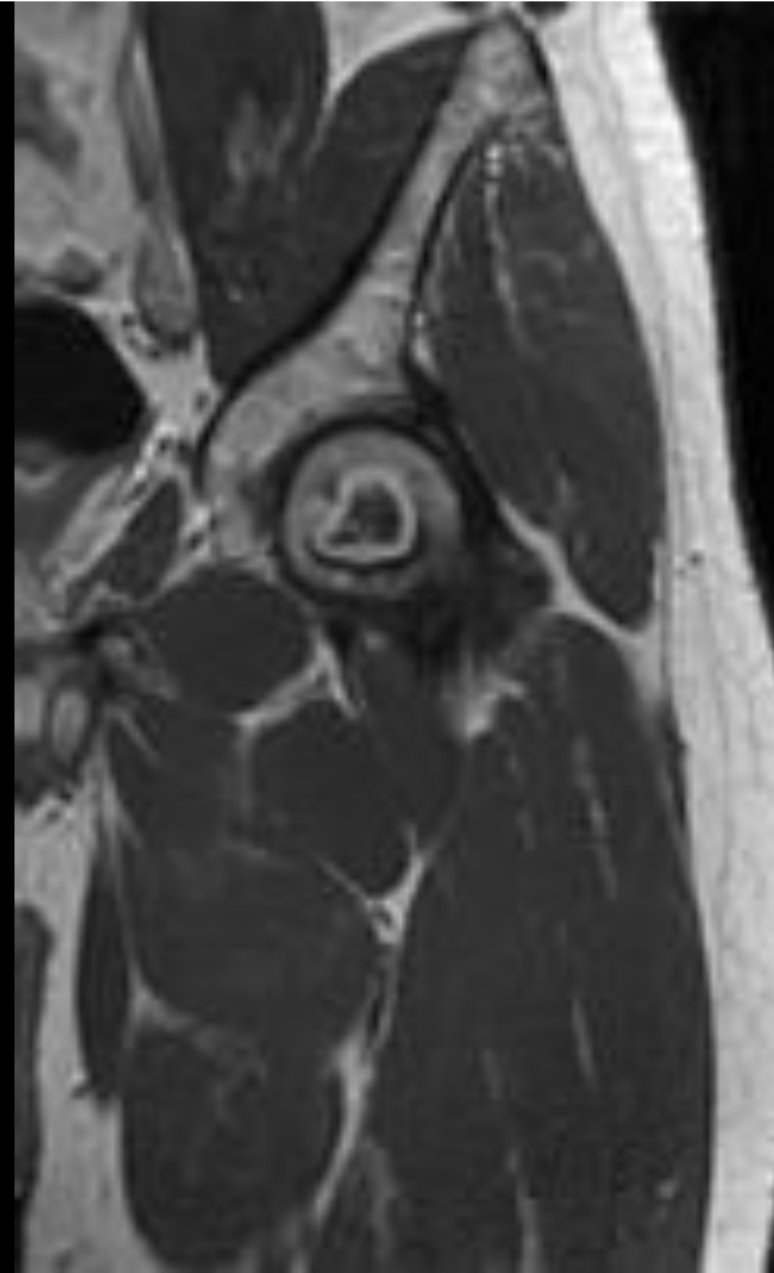




**Coronal T1**



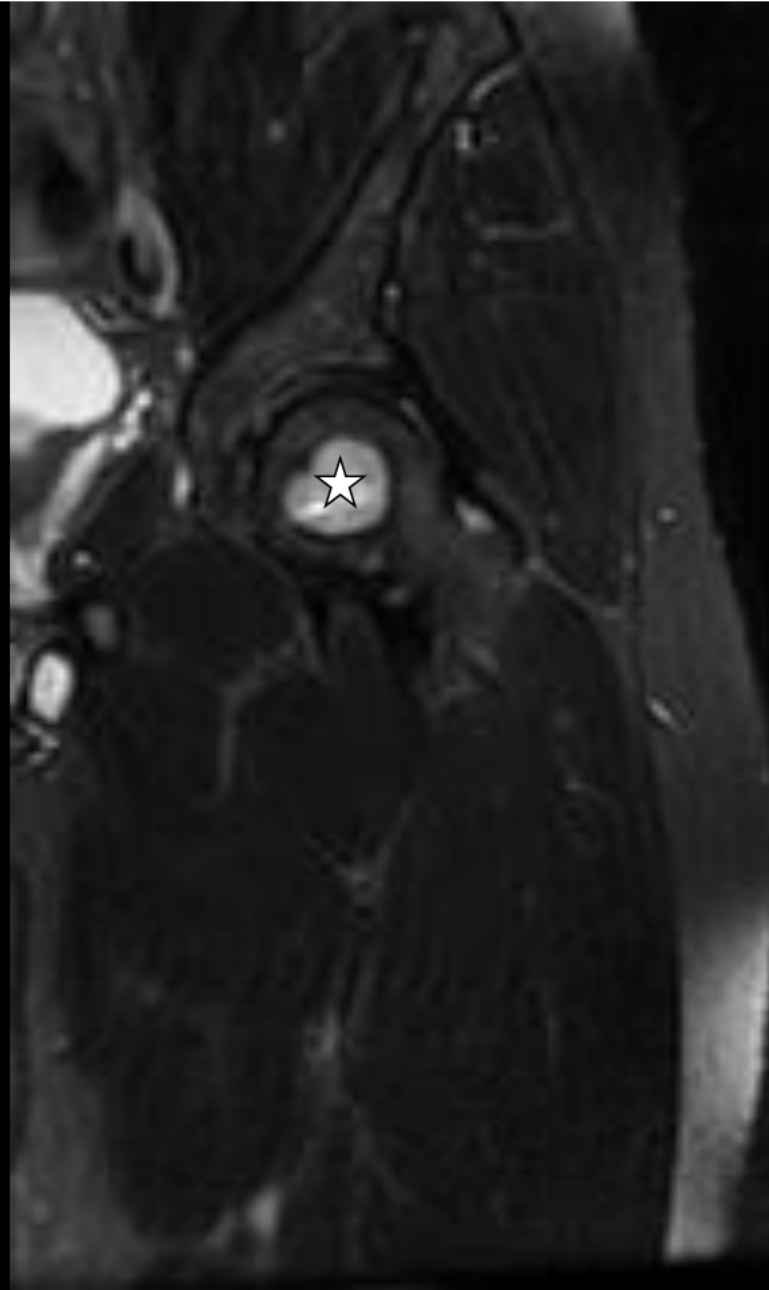
**Coronal T2FS**



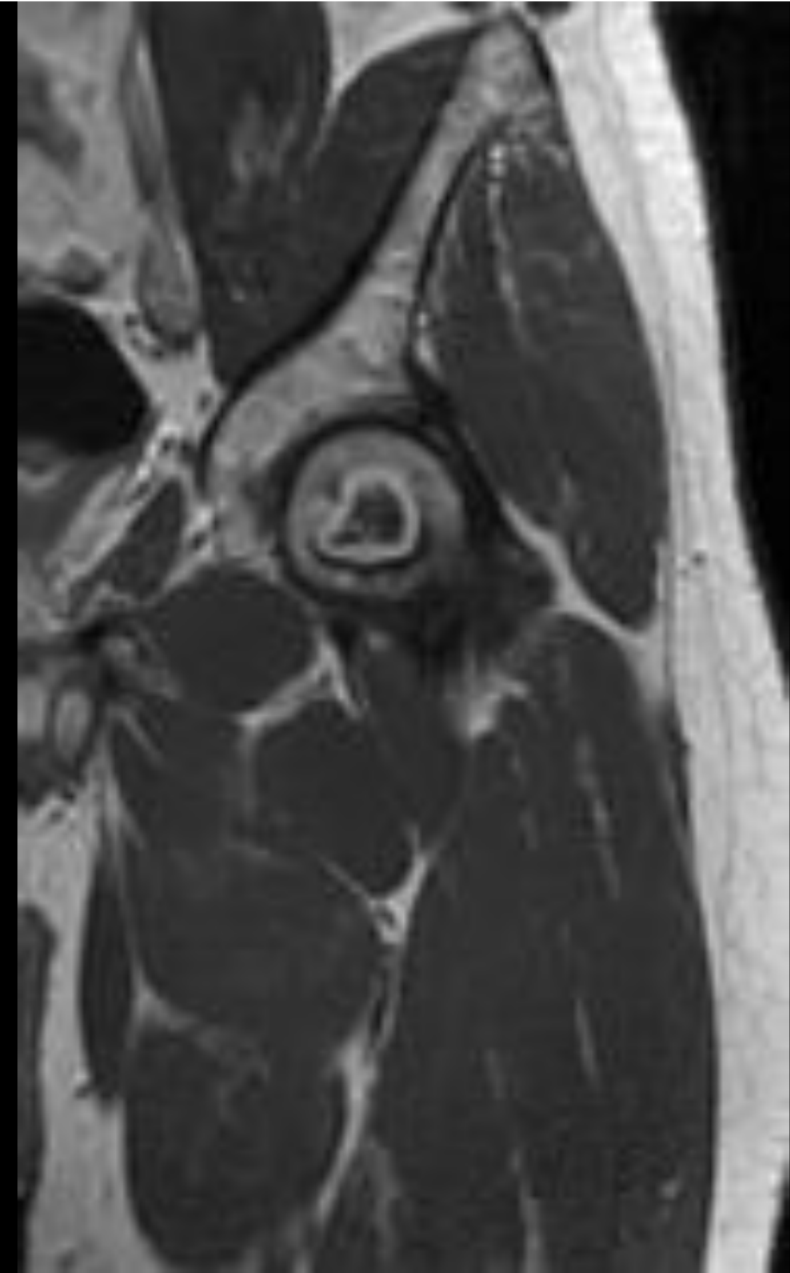
**Coronal T1FS +C**



**Coronal T1**



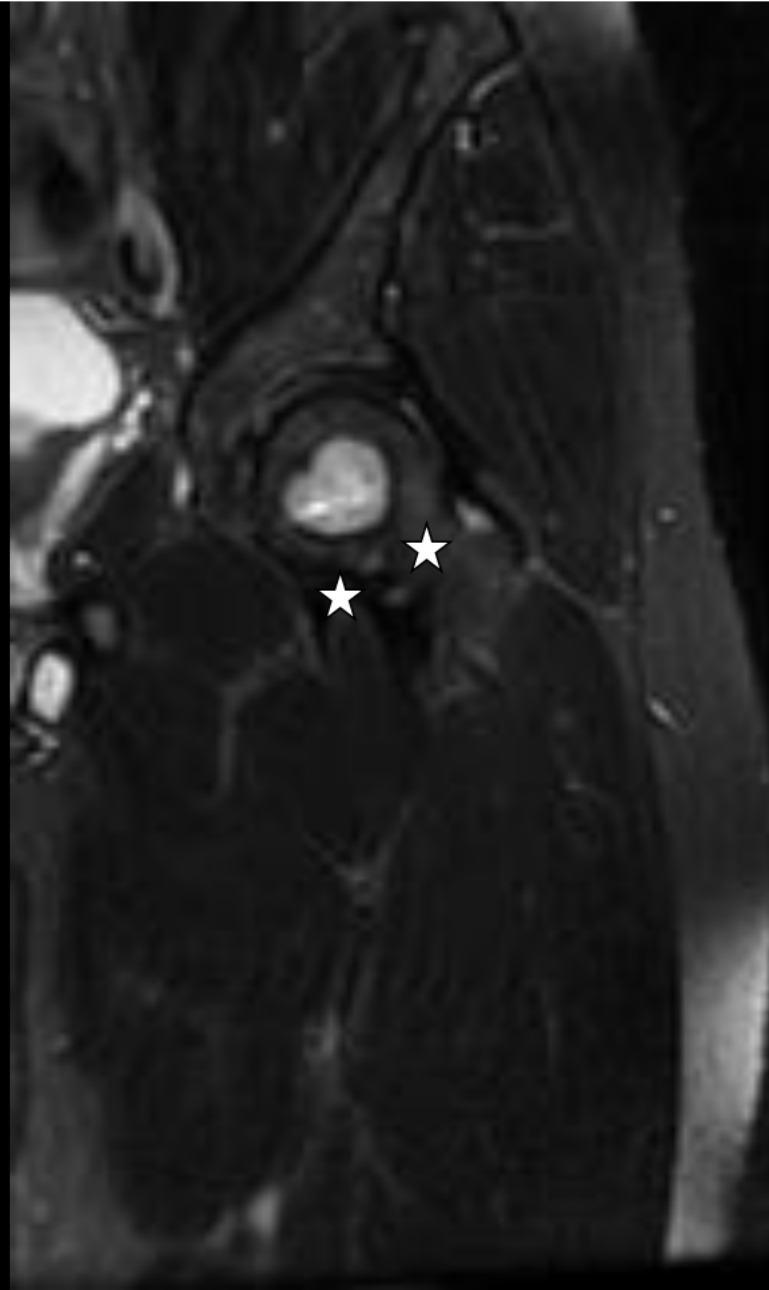
**Coronal T2FS**



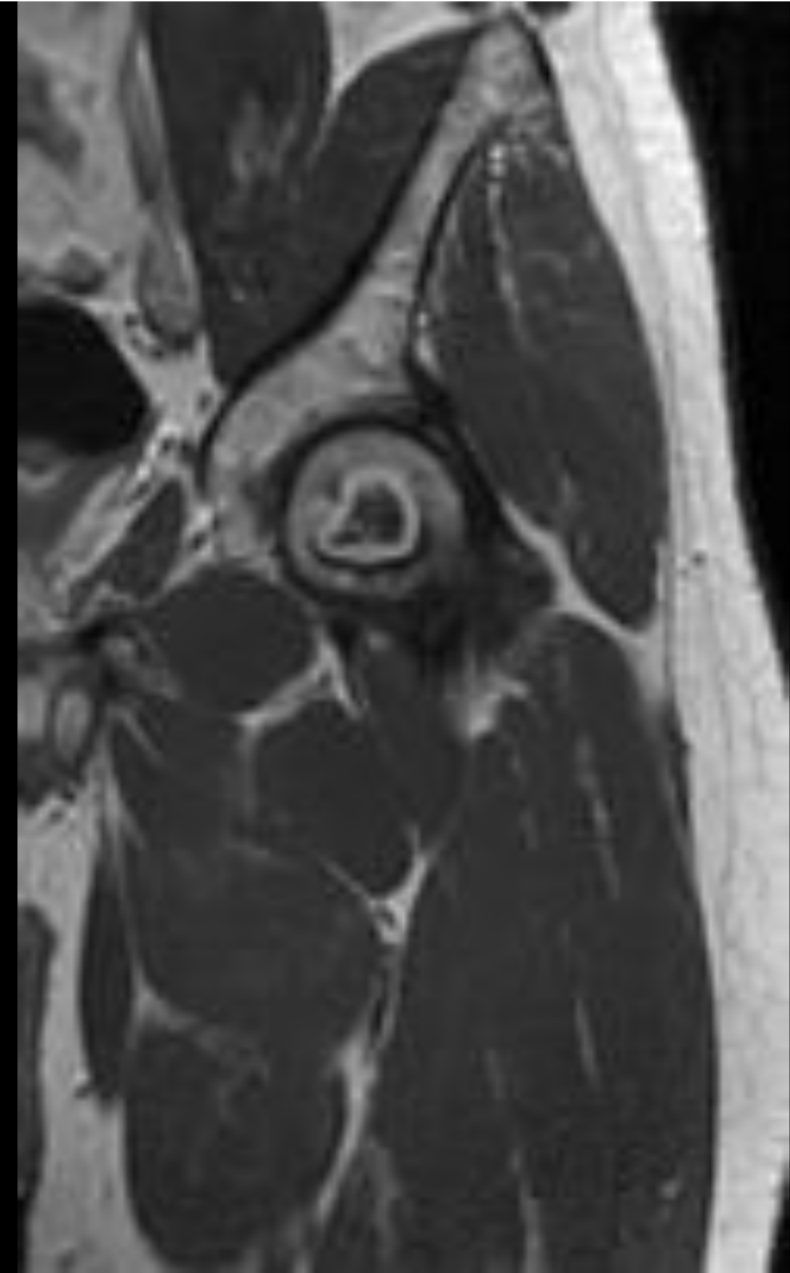
**Coronal T1FS +C**



**Coronal T1**



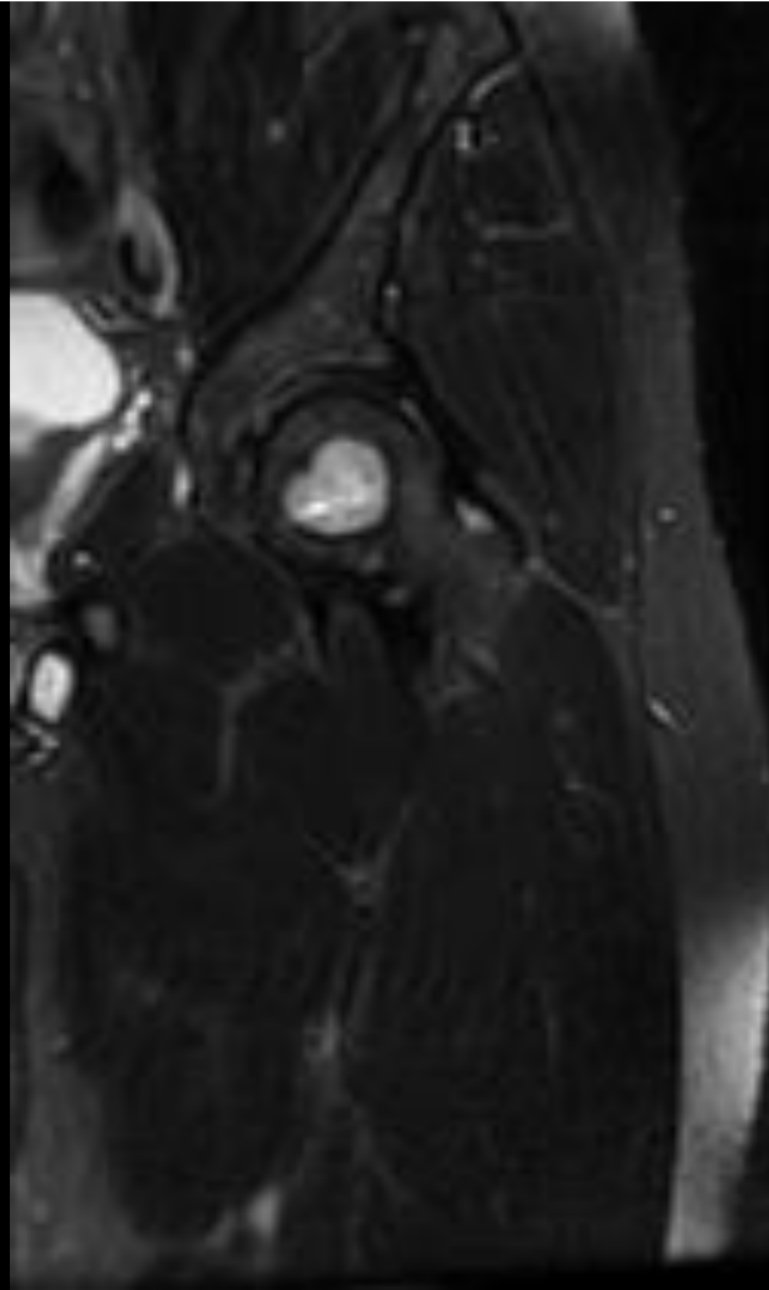
**Coronal T2FS**



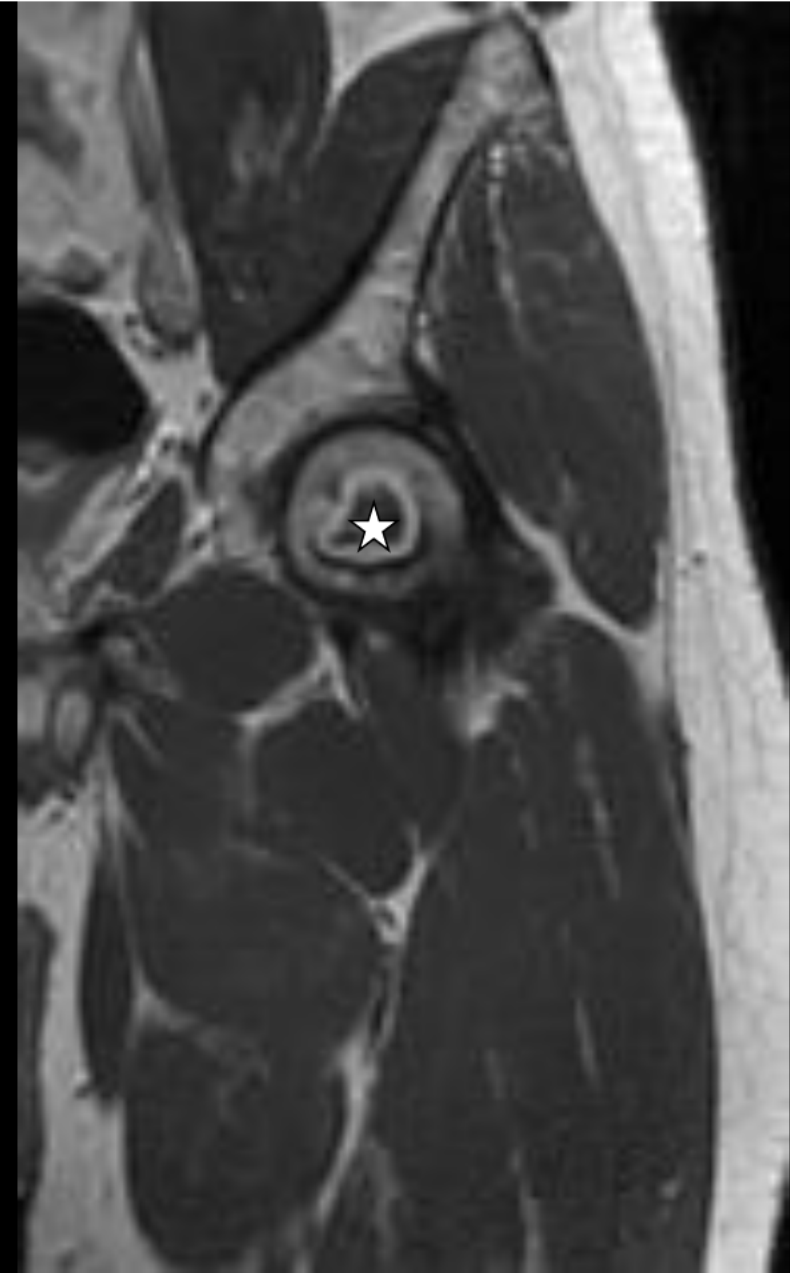
**Coronal T1FS +C**



**Coronal T1**

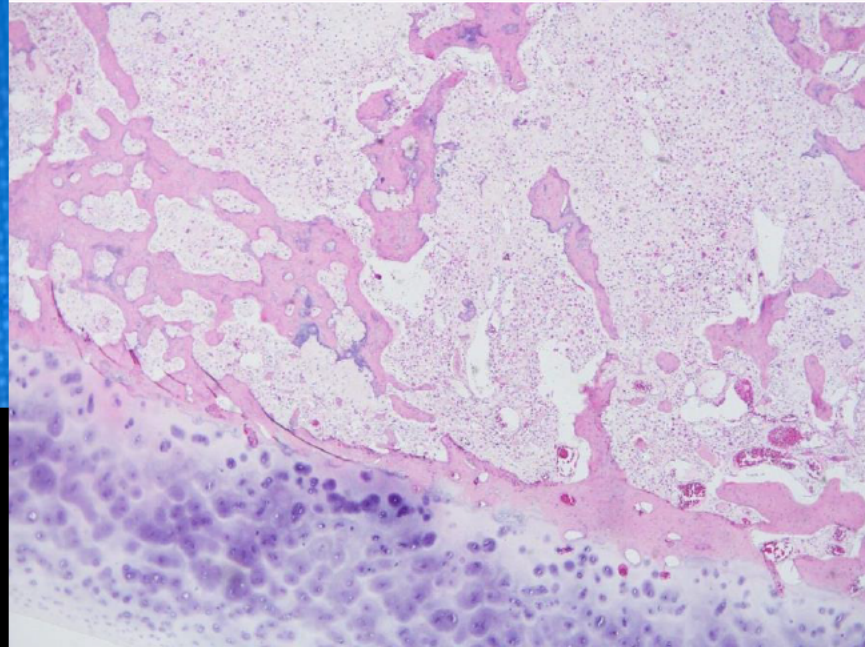
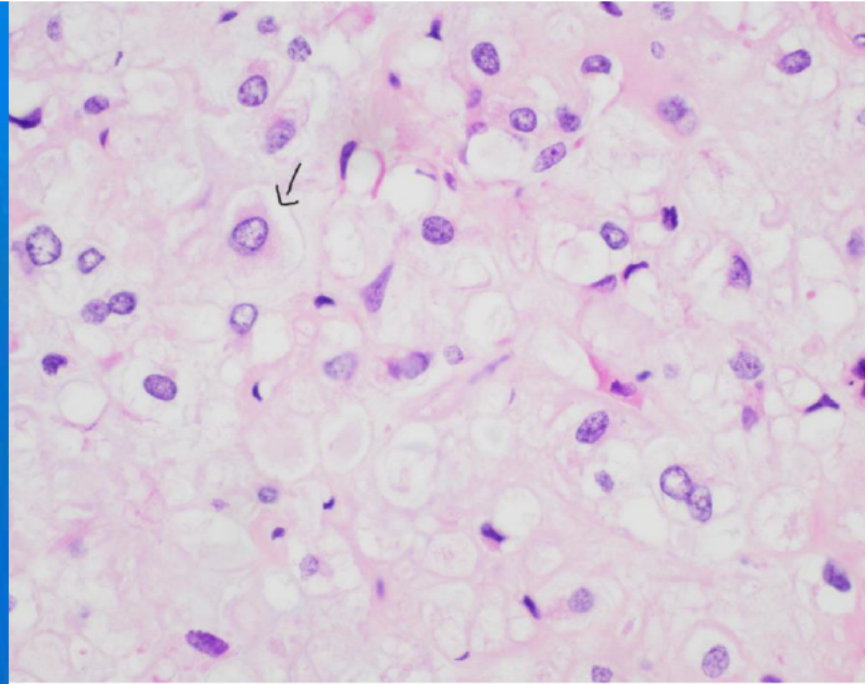
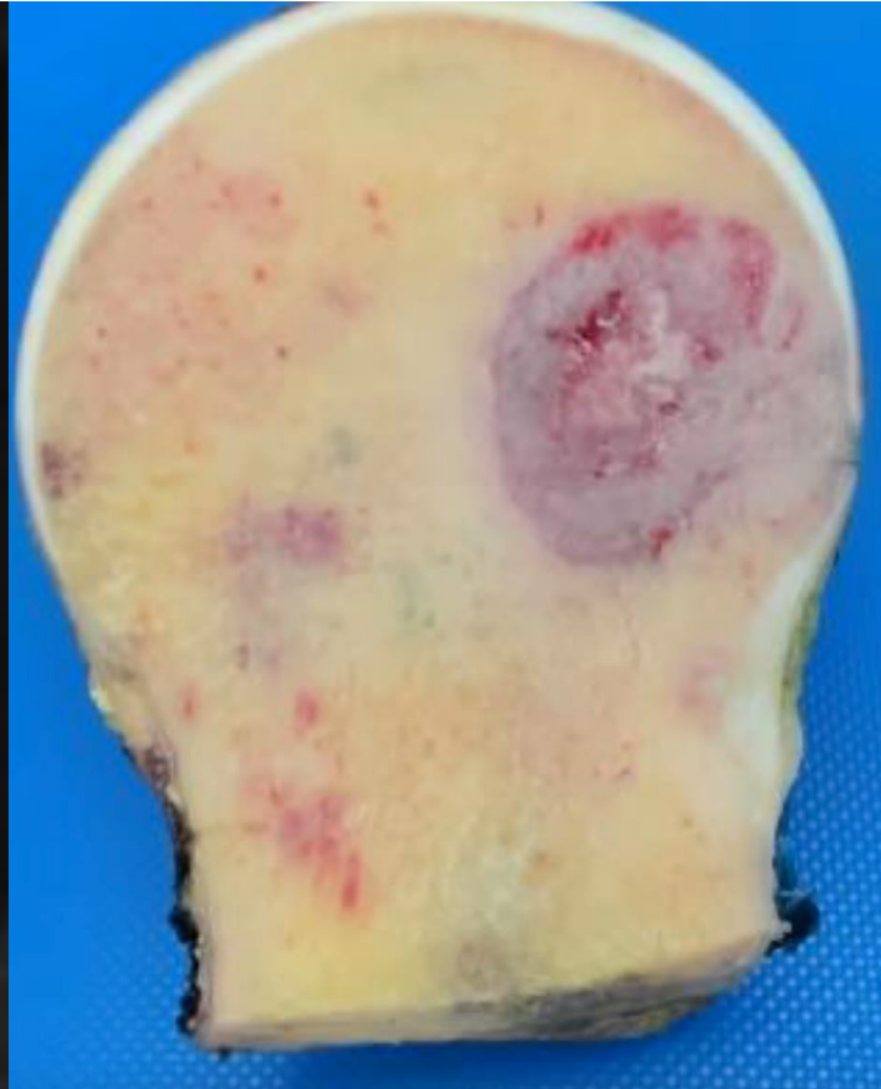
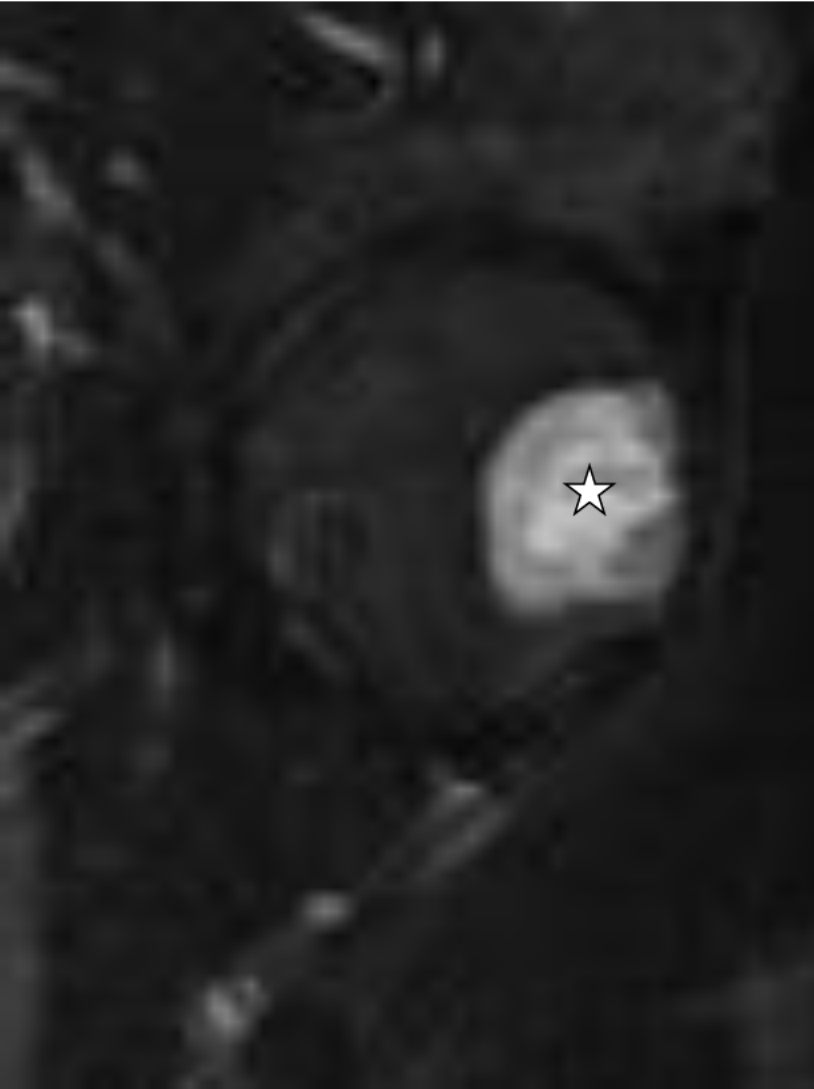


**Coronal T2FS**



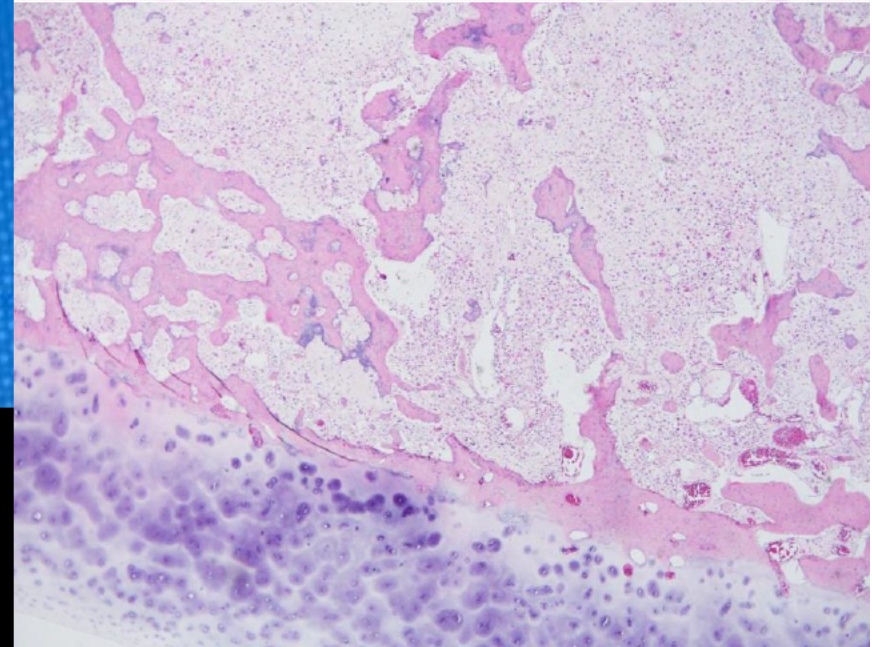
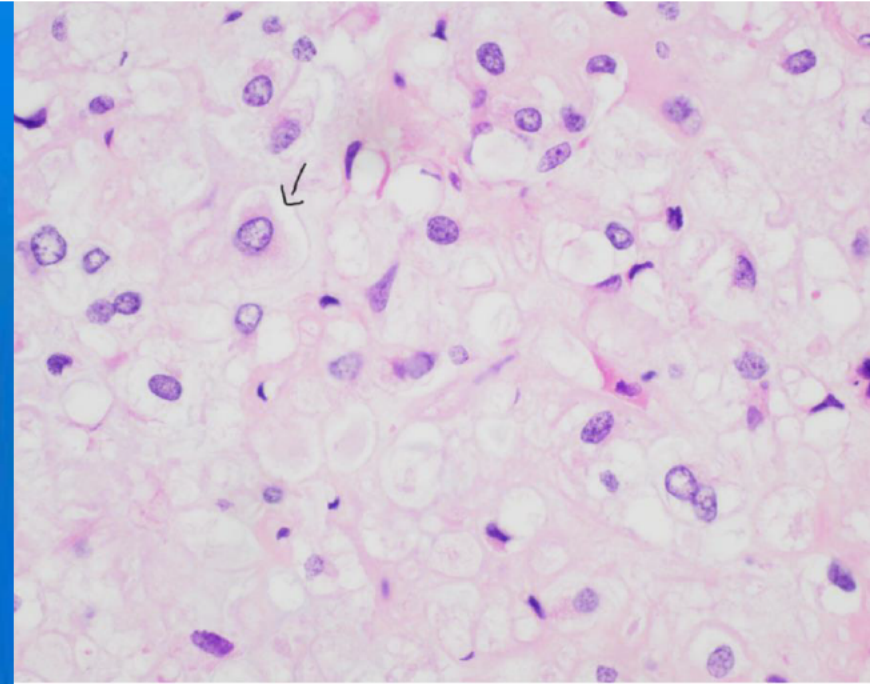
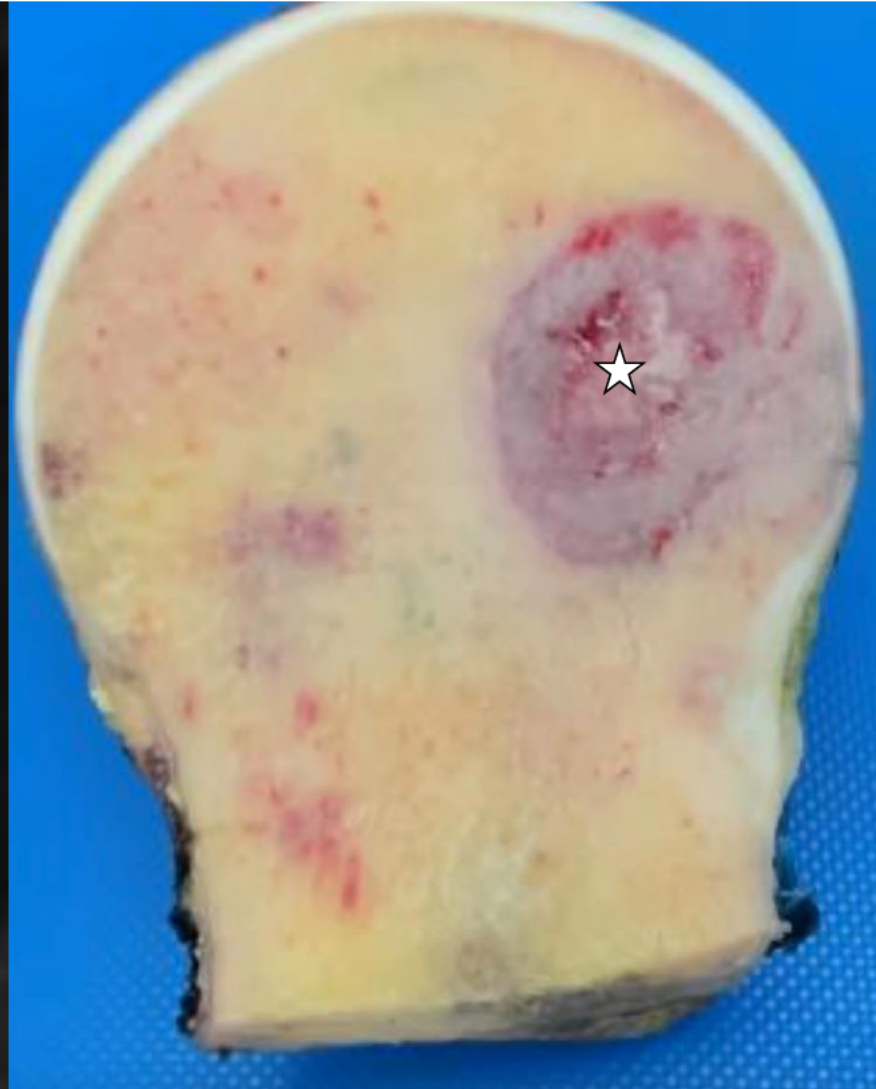
**Coronal T1FS +C**





**Sagittal T2FS**



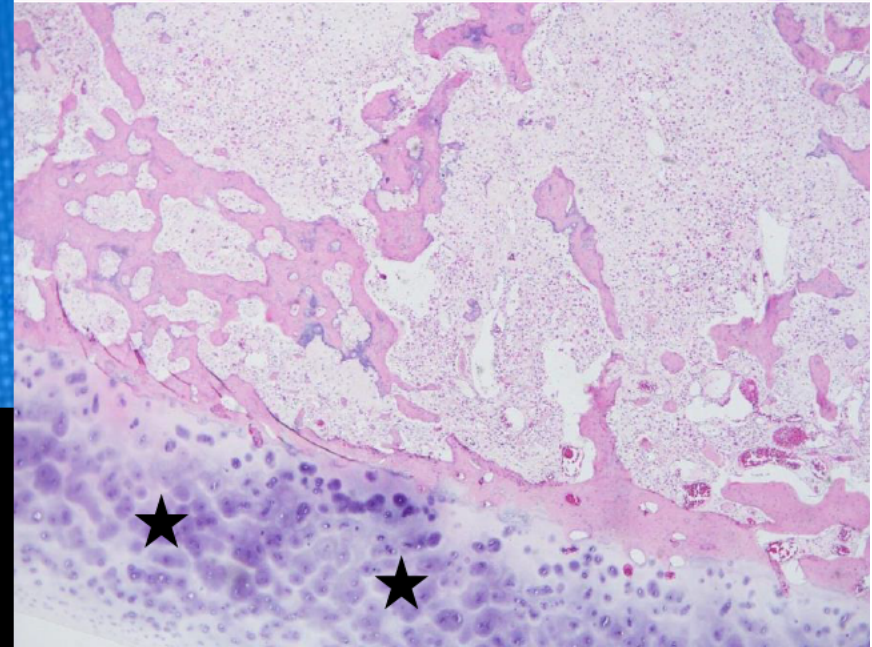
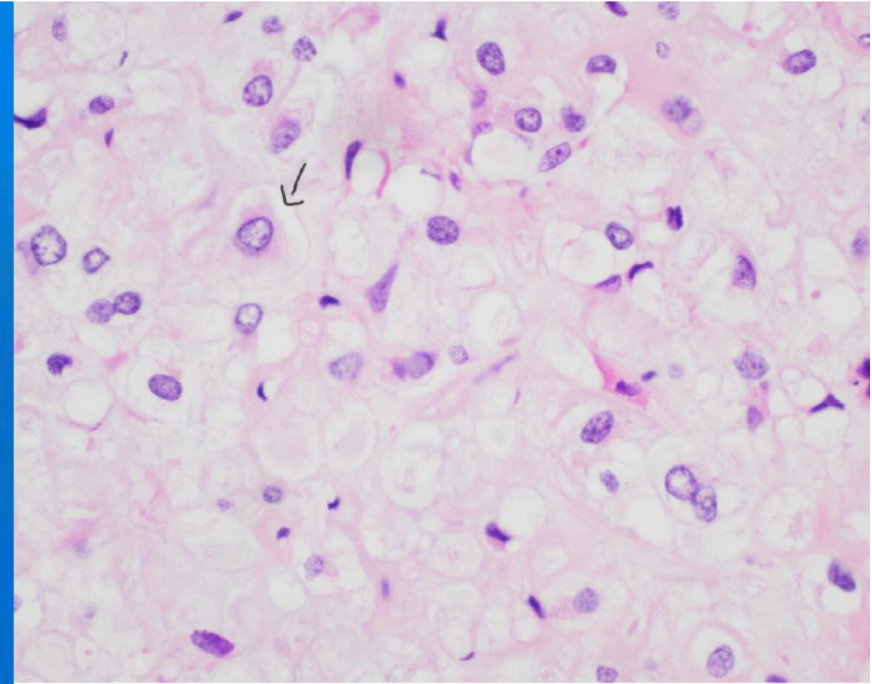
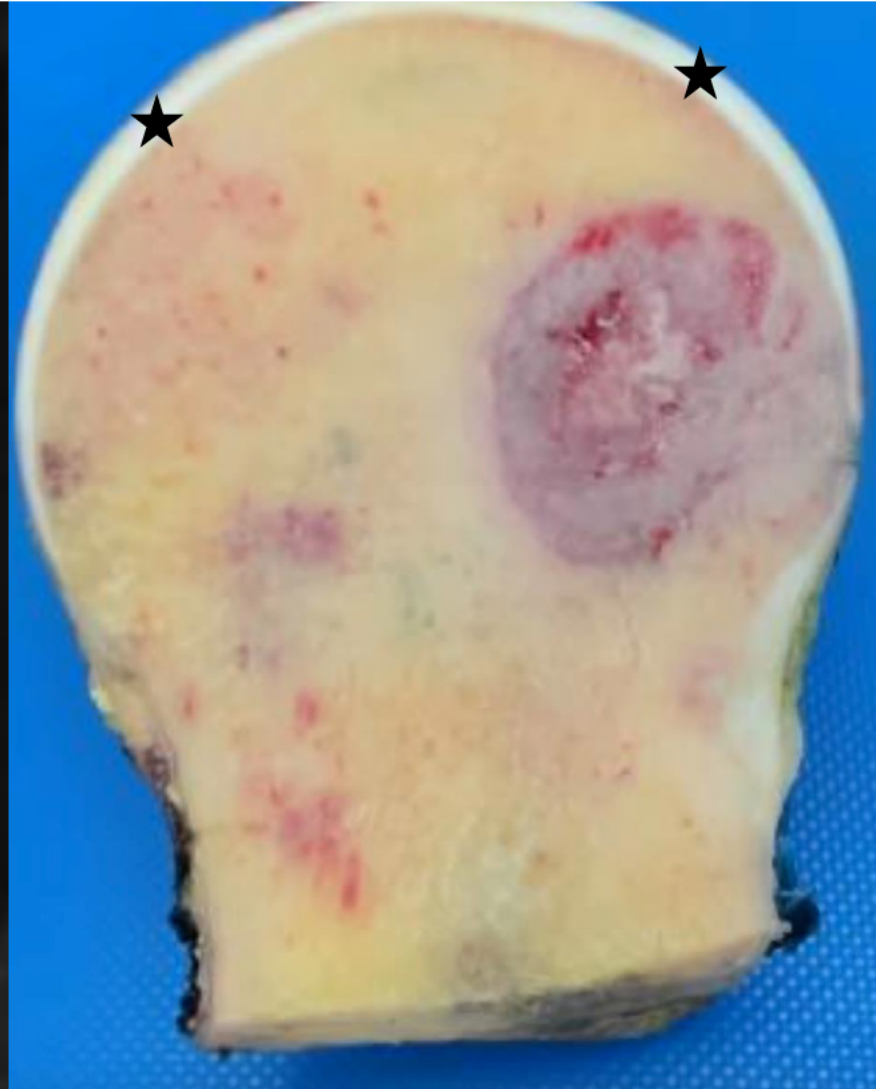


**Sagittal T2FS**

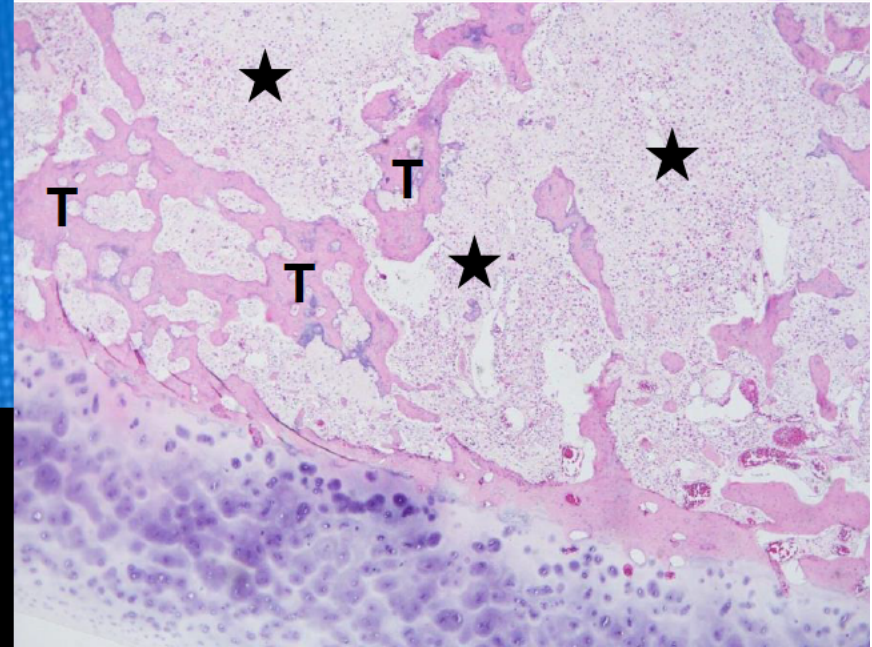
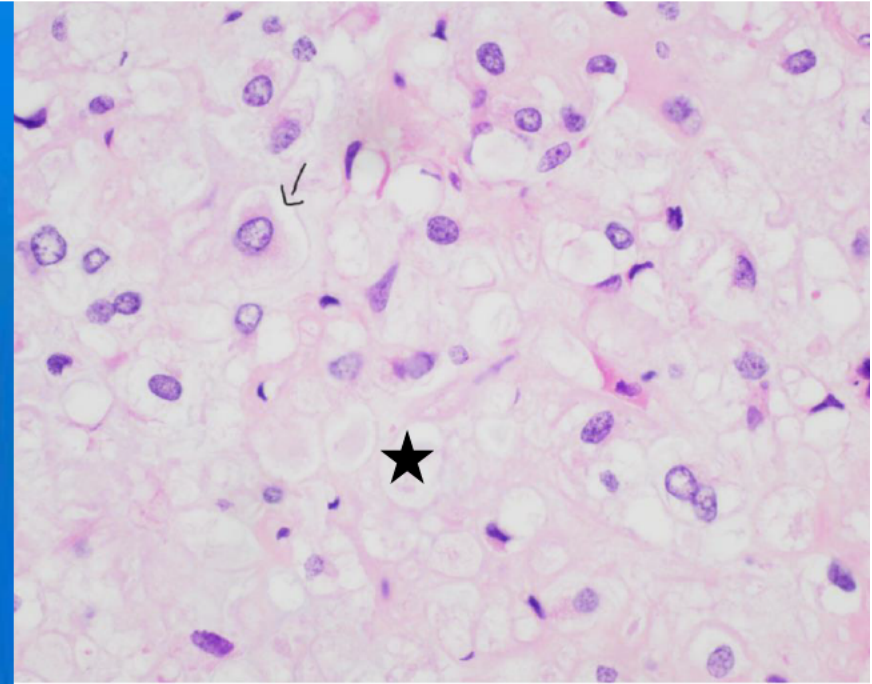
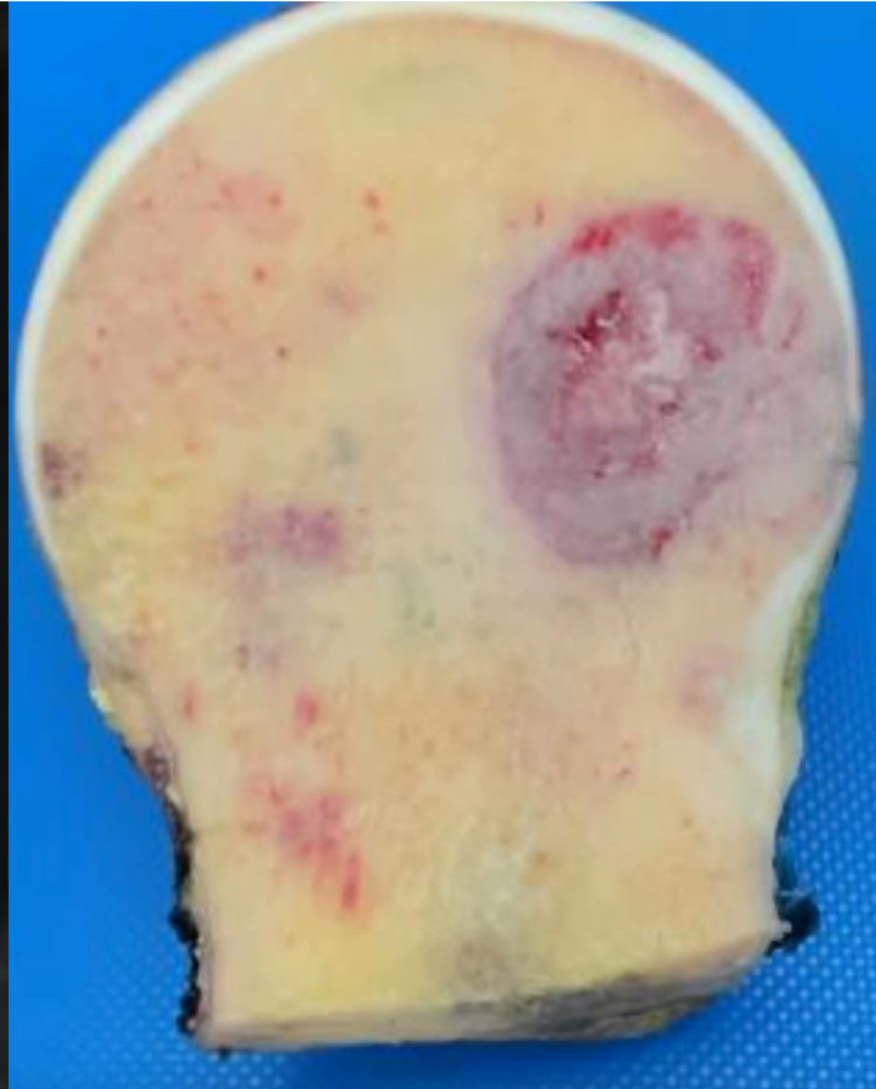




Sagittal T2FS

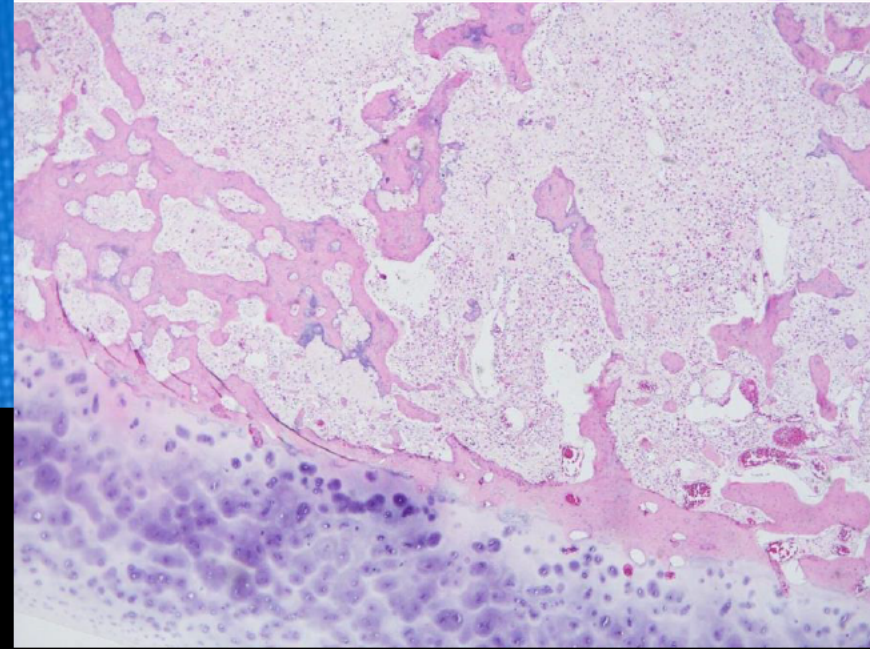
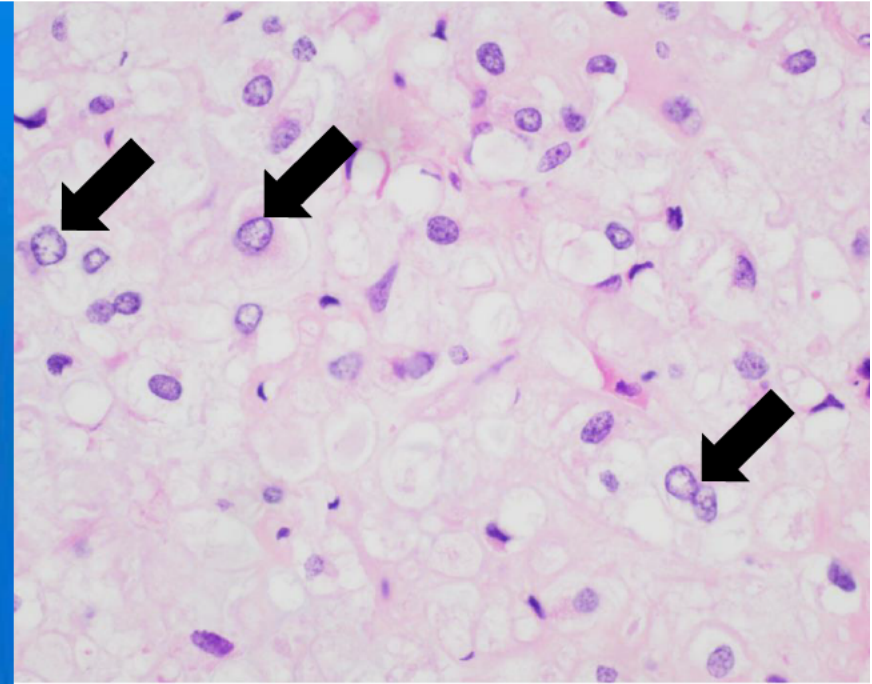
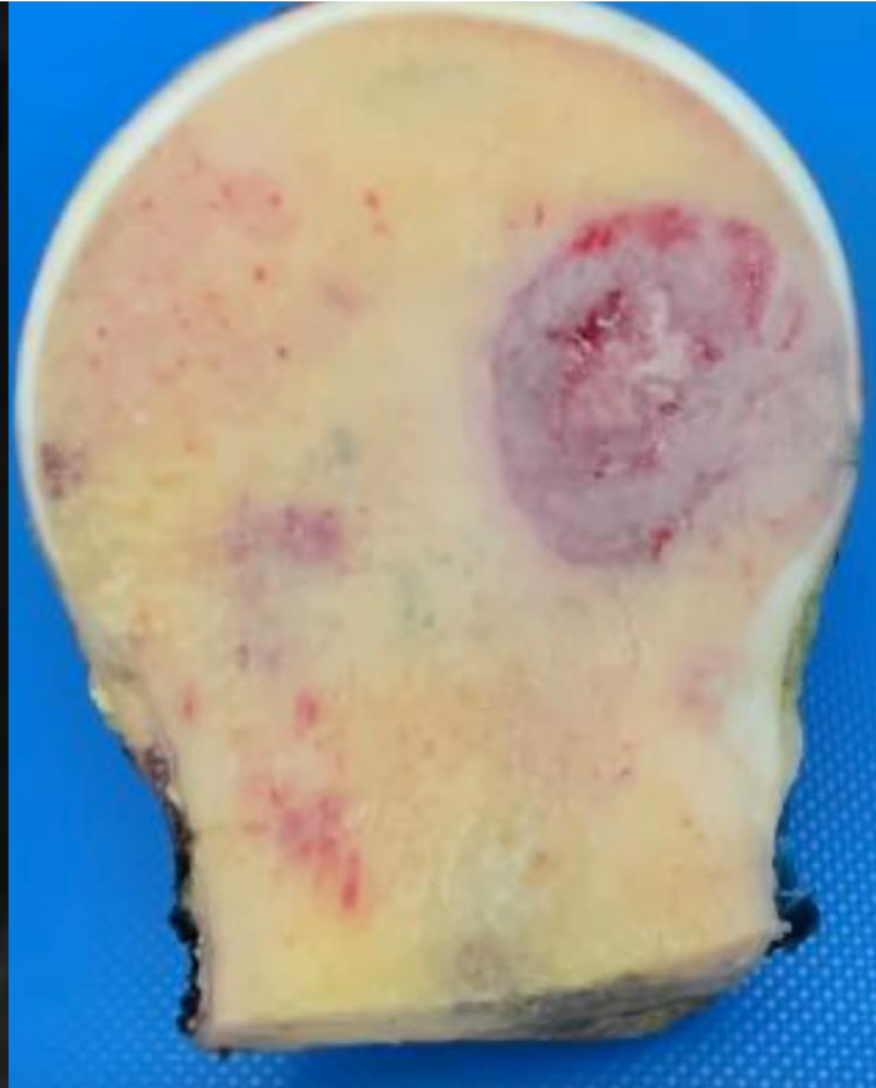






Sagittal T2FS





**Sagittal T2FS**

# Clear Cell Chondrosarcoma



ACR INSTITUTE FOR  
RADIOLOGIC PATHOLOGY