



Display Techniques for Virtual Colonoscopy

Matthew Barish, MD

Assistant Professor

Stony Brook University

Director, International Symposia on VC

Director, Body Imaging & MRI

Stony Brook University Medical Center

Virtual Colonoscopy - Definition

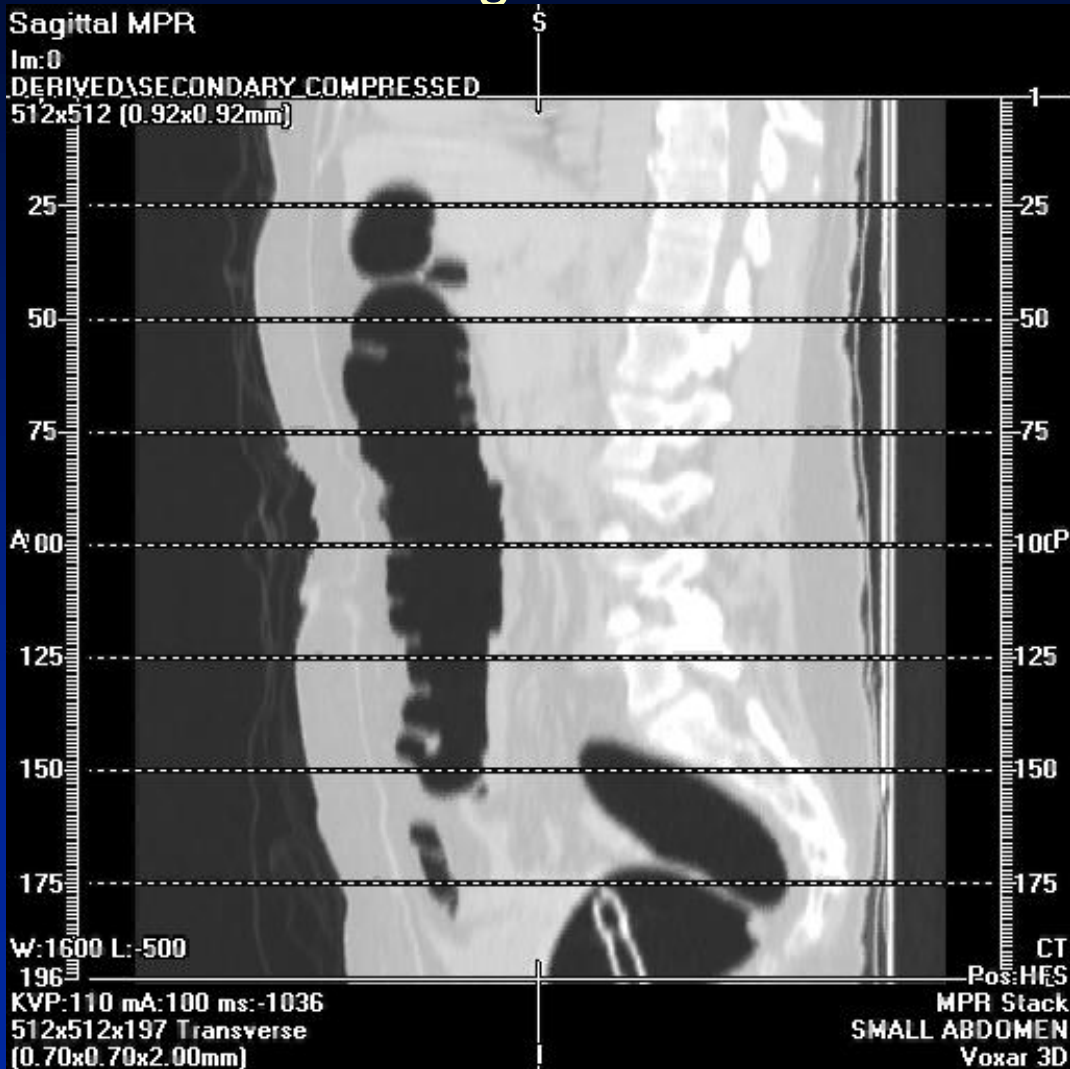


- ◆ Thin Section Helical CT
- ◆ Gas Distended
- ◆ Cleansed Colon
- ◆ Image Reconstruction
- ◆ Image Review / Interpretation

Perception of Virtual Colonoscopy



Axial CT images are obtained



And then converted into ...

Virtual Colonoscopy





- ◆ Purpose of Reconstruction and Review
 - Detection of suspect lesions
 - Determines sensitivity -
Increase True Positives &
Reduce False Negatives
 - Characterization of detected lesions
 - Determines specificity -
Reduce false positives

Detection of Suspect Lesions



- ◆ Display method should allow:
 - Easy means for navigation through the colon
 - Display lesion on screen for sufficient detection time
 - Differentiate polyps from normal features of colon
 - Visualize the entire colonic mucosa
 - Detection beneath obscuring fluid, tagged stool, etc.
 - Integration of CAD targets

Virtual Colonoscopy



◆ Detection - Display Methods

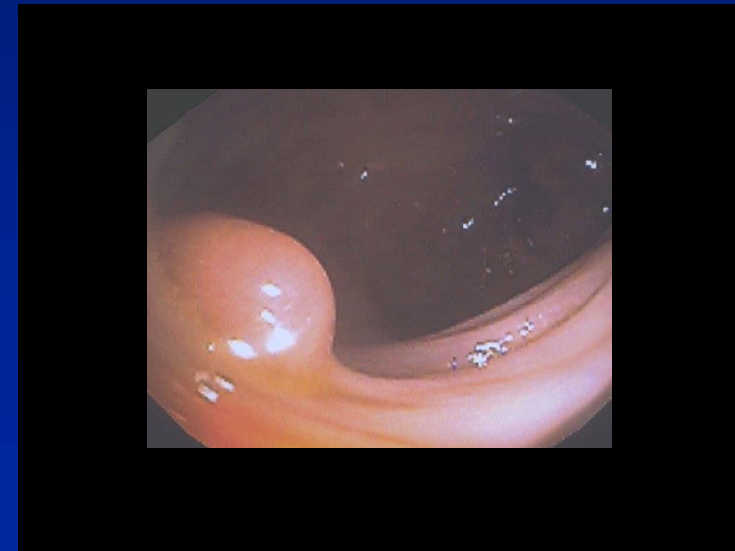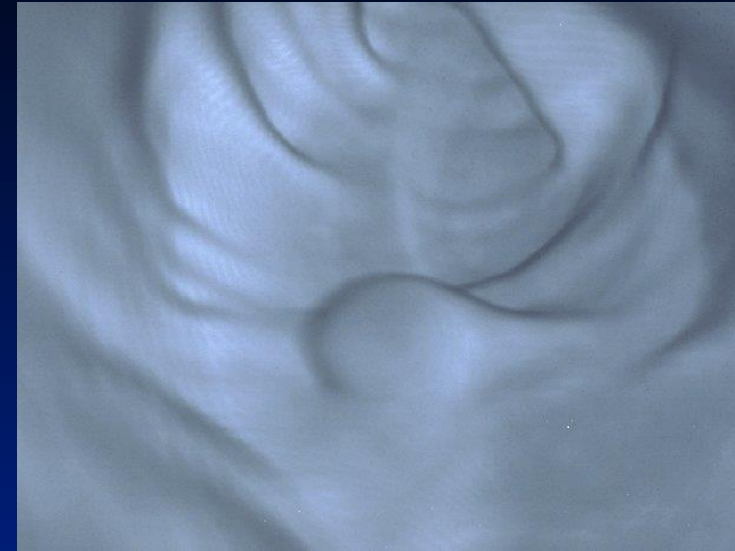
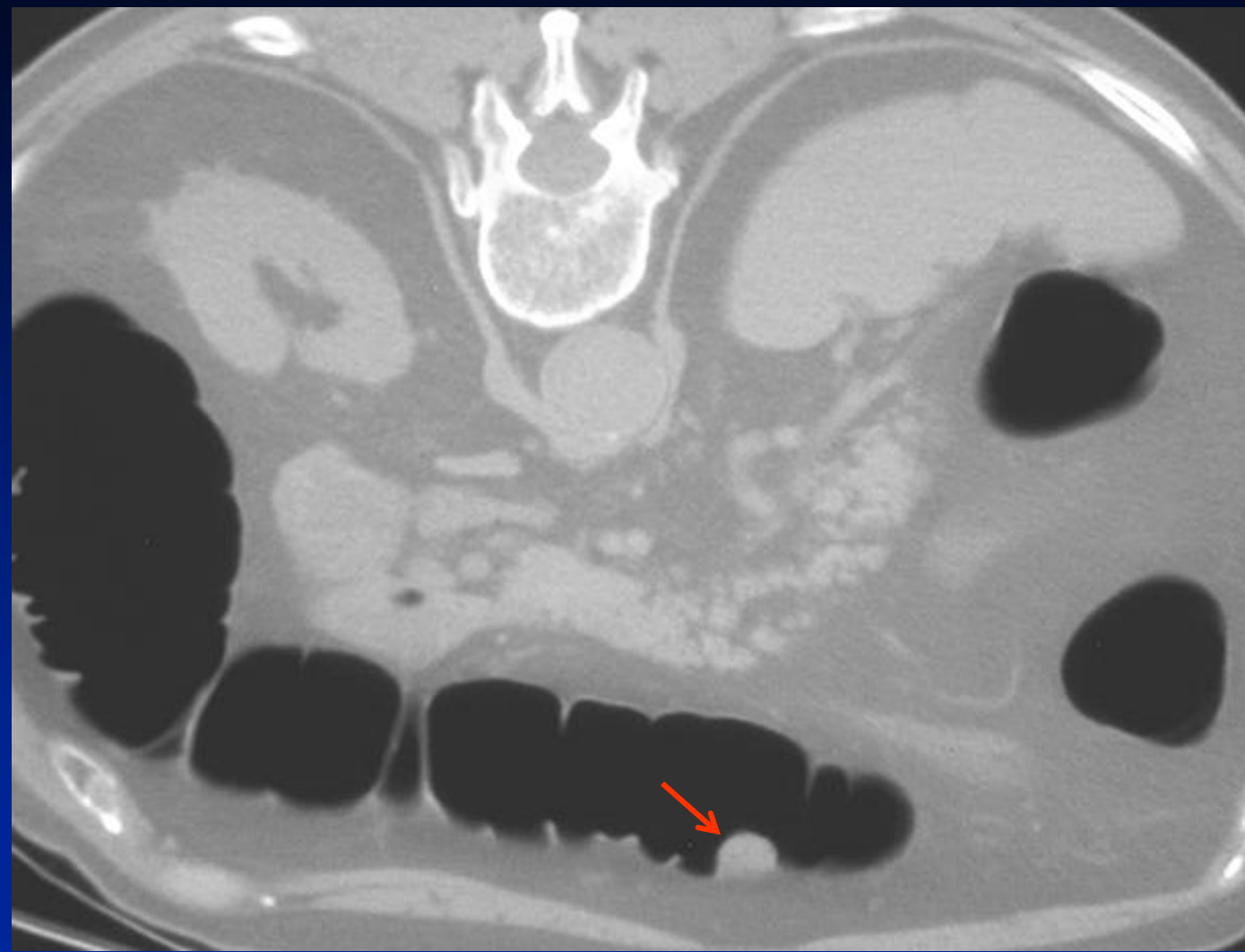
– 2D

- Lumen tracking
- 3D Problem solving

– 3D methods

- 3D cube
- Fly-through
- Unfolded cube
- Fillet
- Flattened

2D Detection

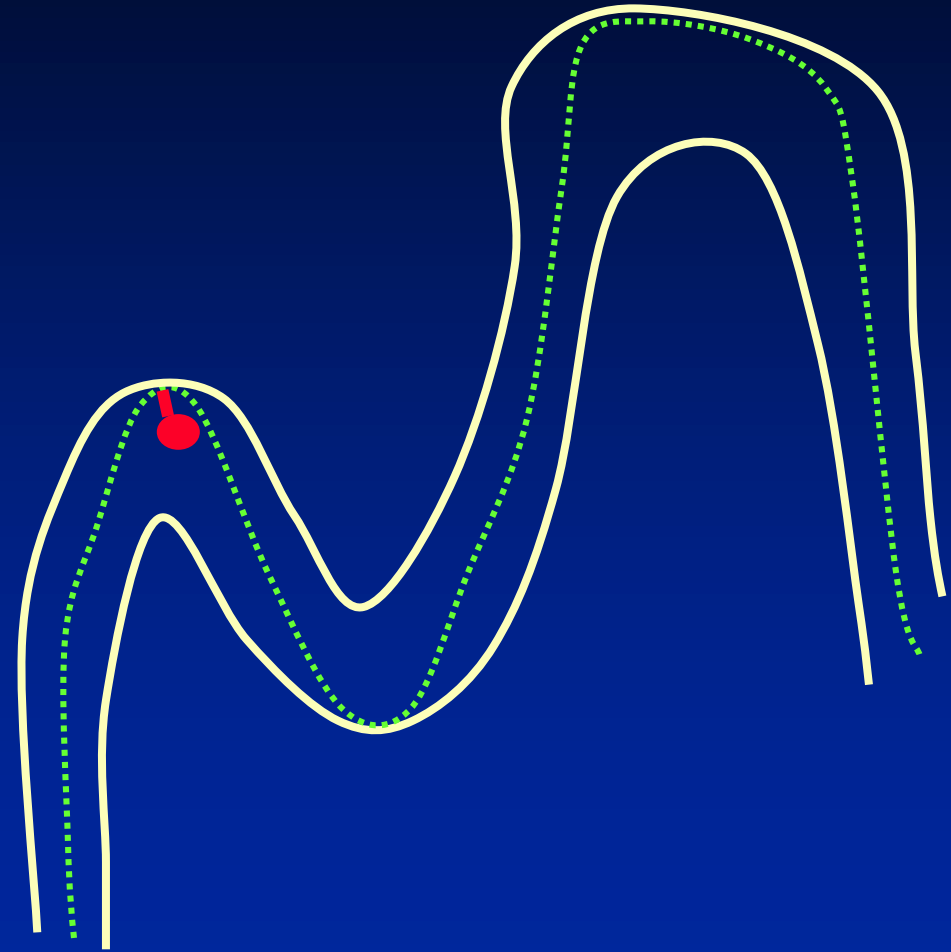
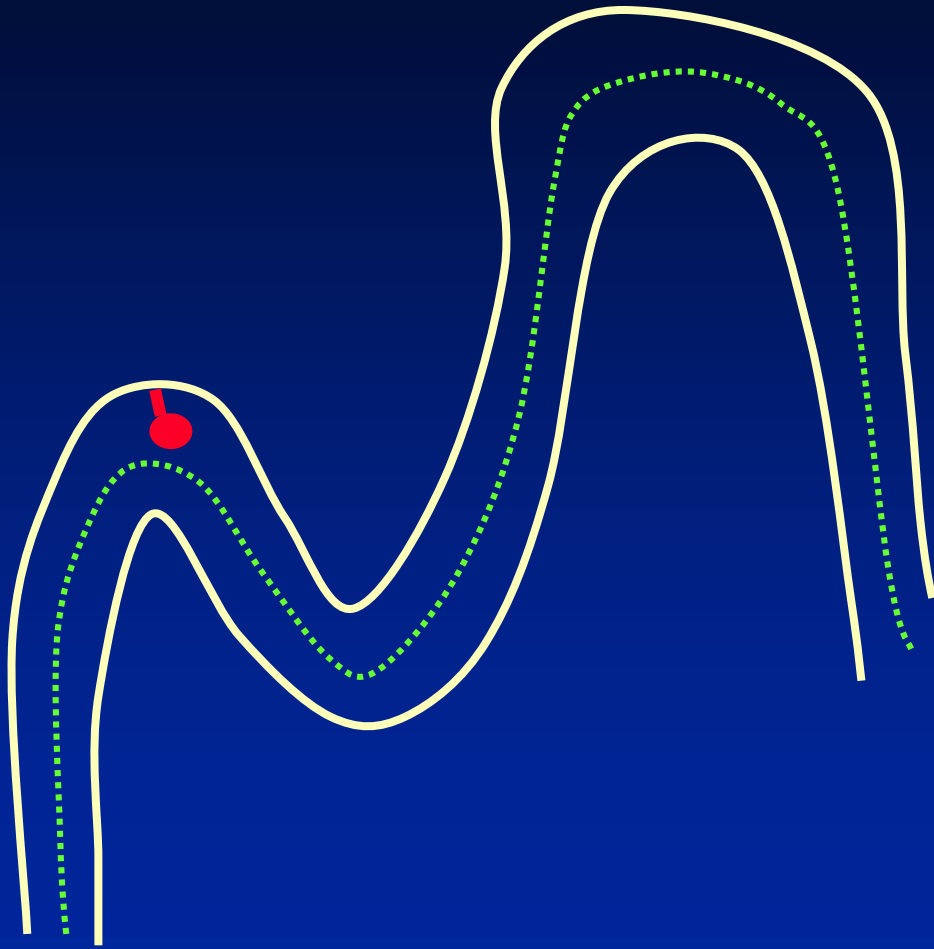


Initial 2D Interpretation

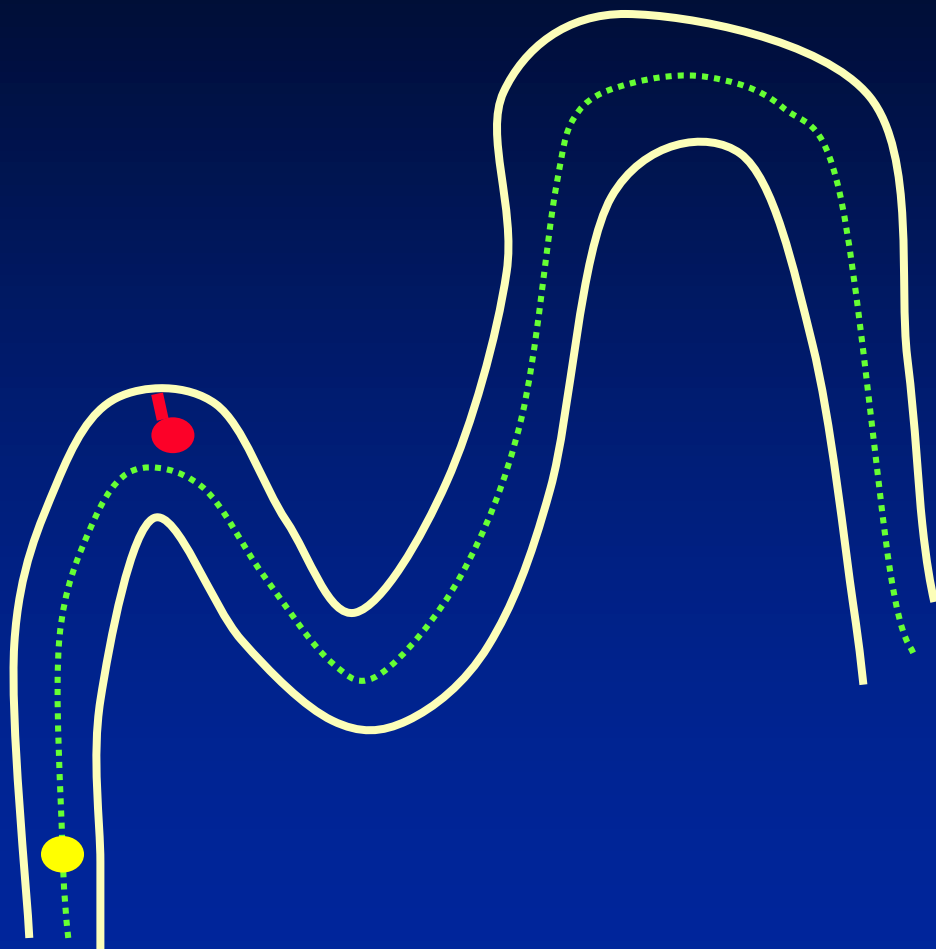


- ◆ Stack mode – 2D Cine
- ◆ Lumen tracking:
 - The colonic lumen is followed on serial axial images from rectum to cecum
 - The entire lumen is viewed, NOT just along the centerline


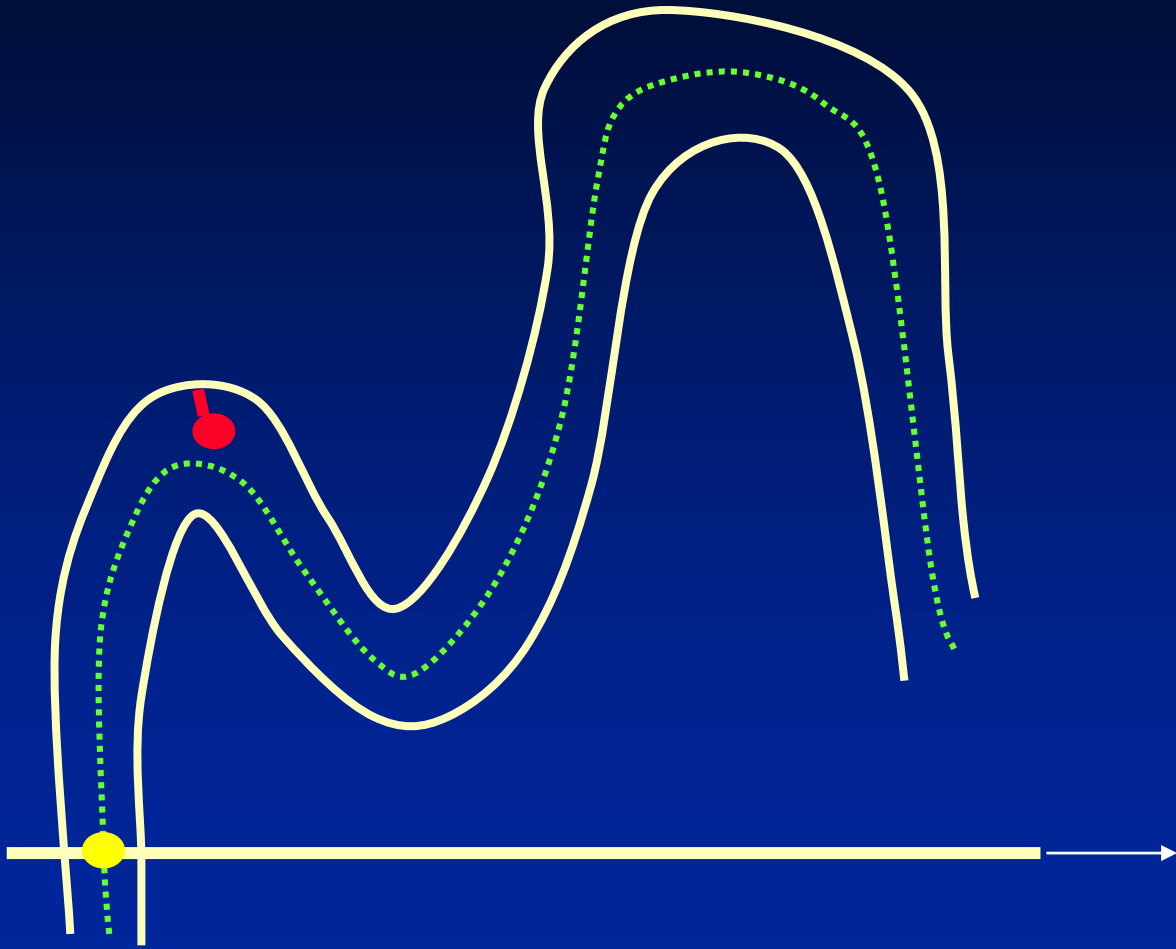
Center Tracking vs. Lumen Tracking




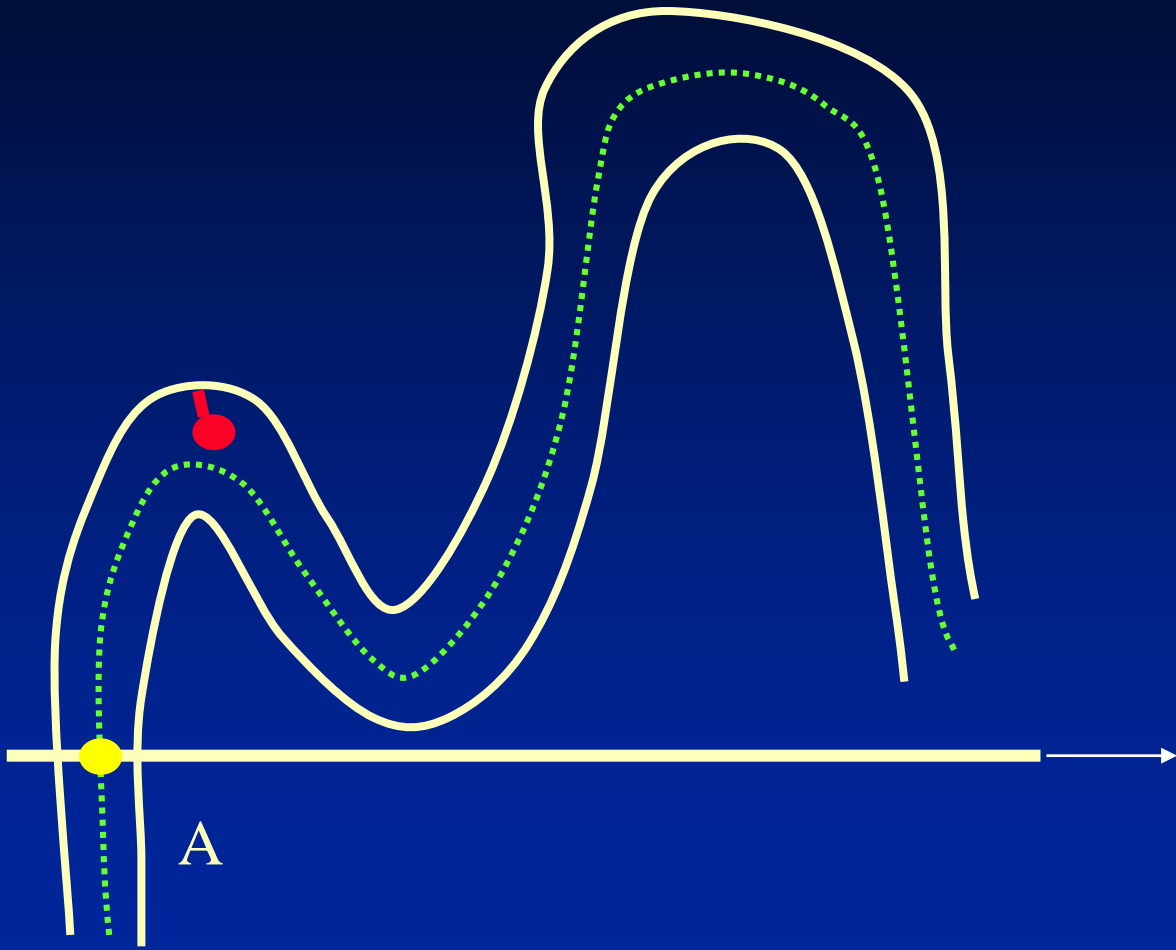
Center Tracking



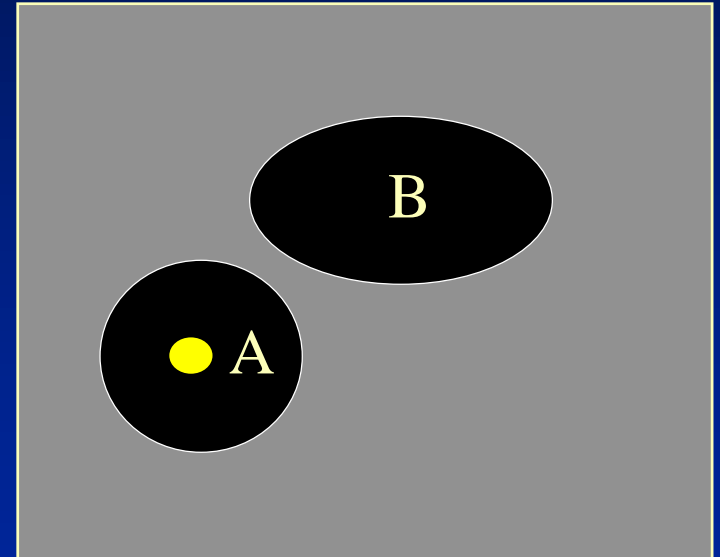
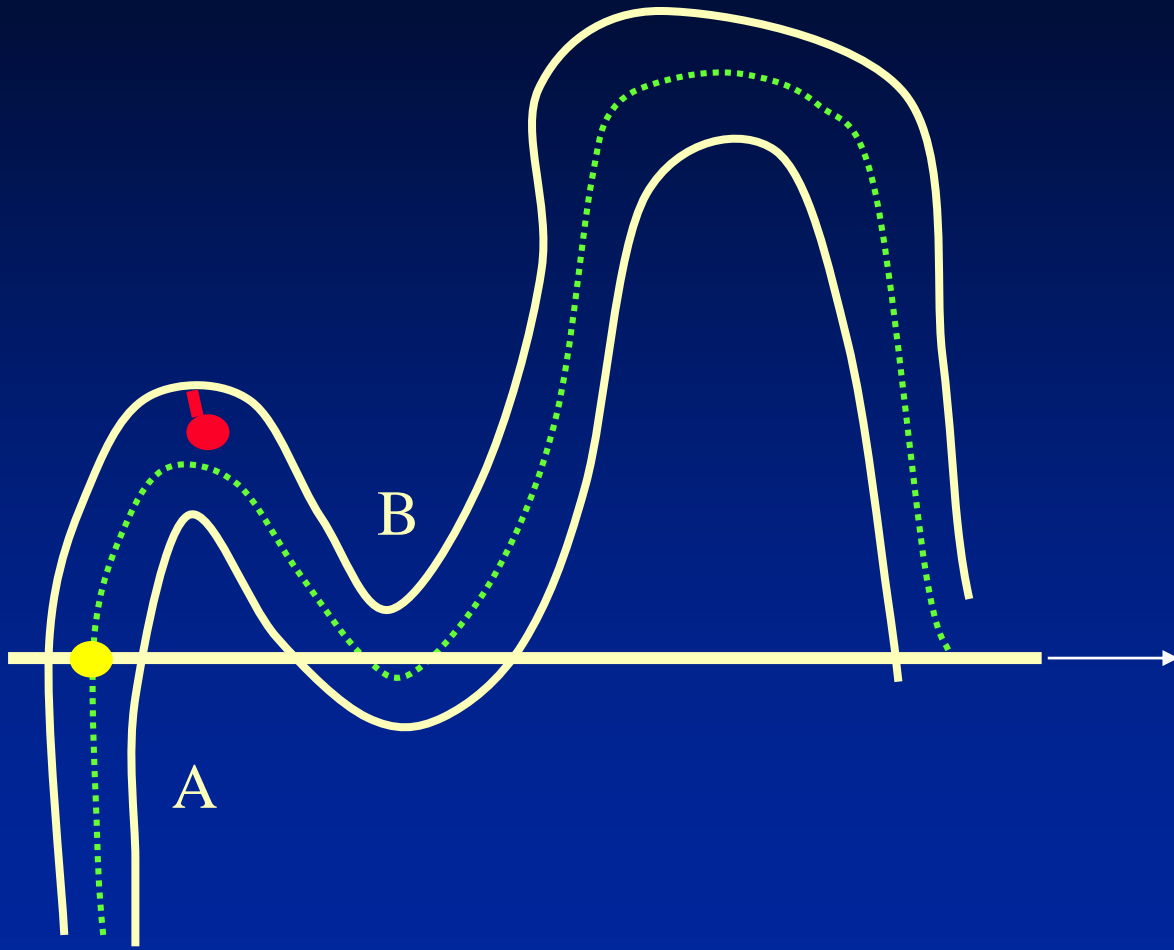
Center Tracking



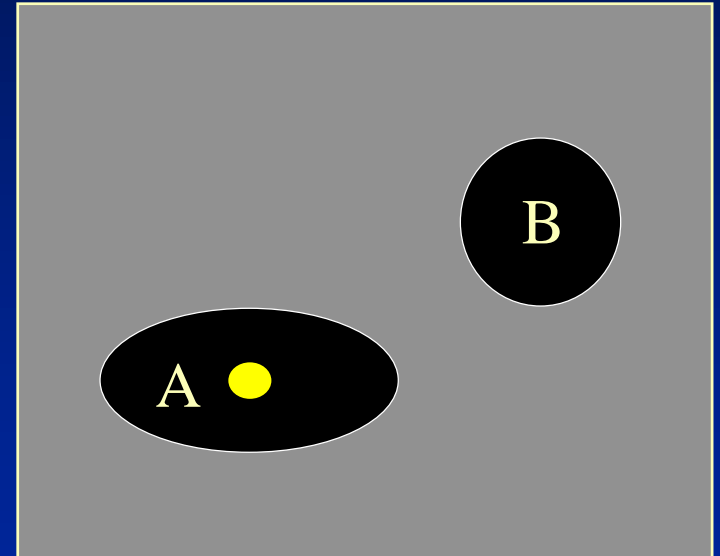
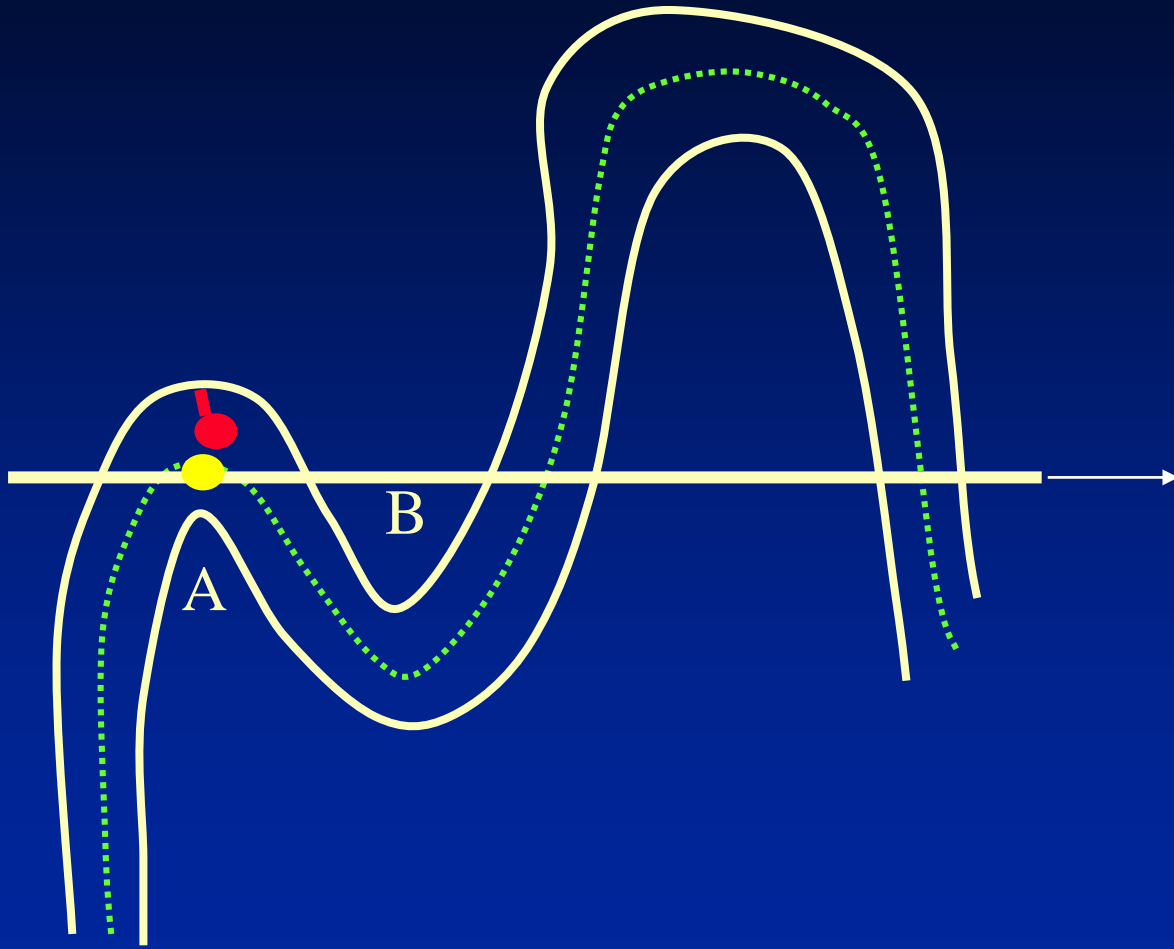
Center Tracking



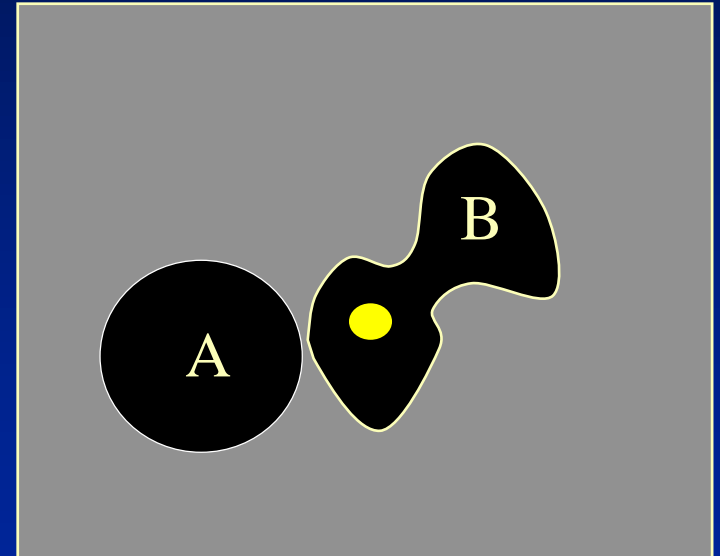
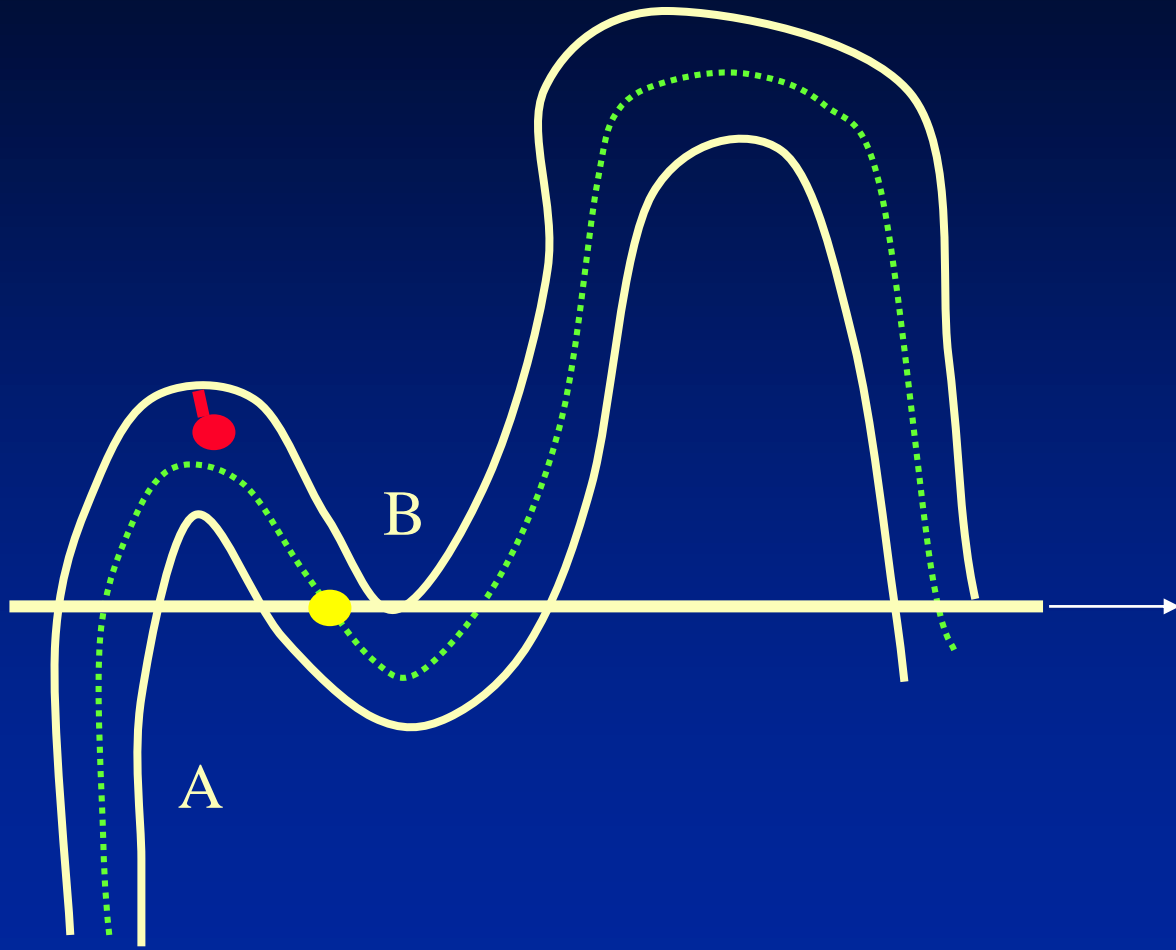
Center Tracking




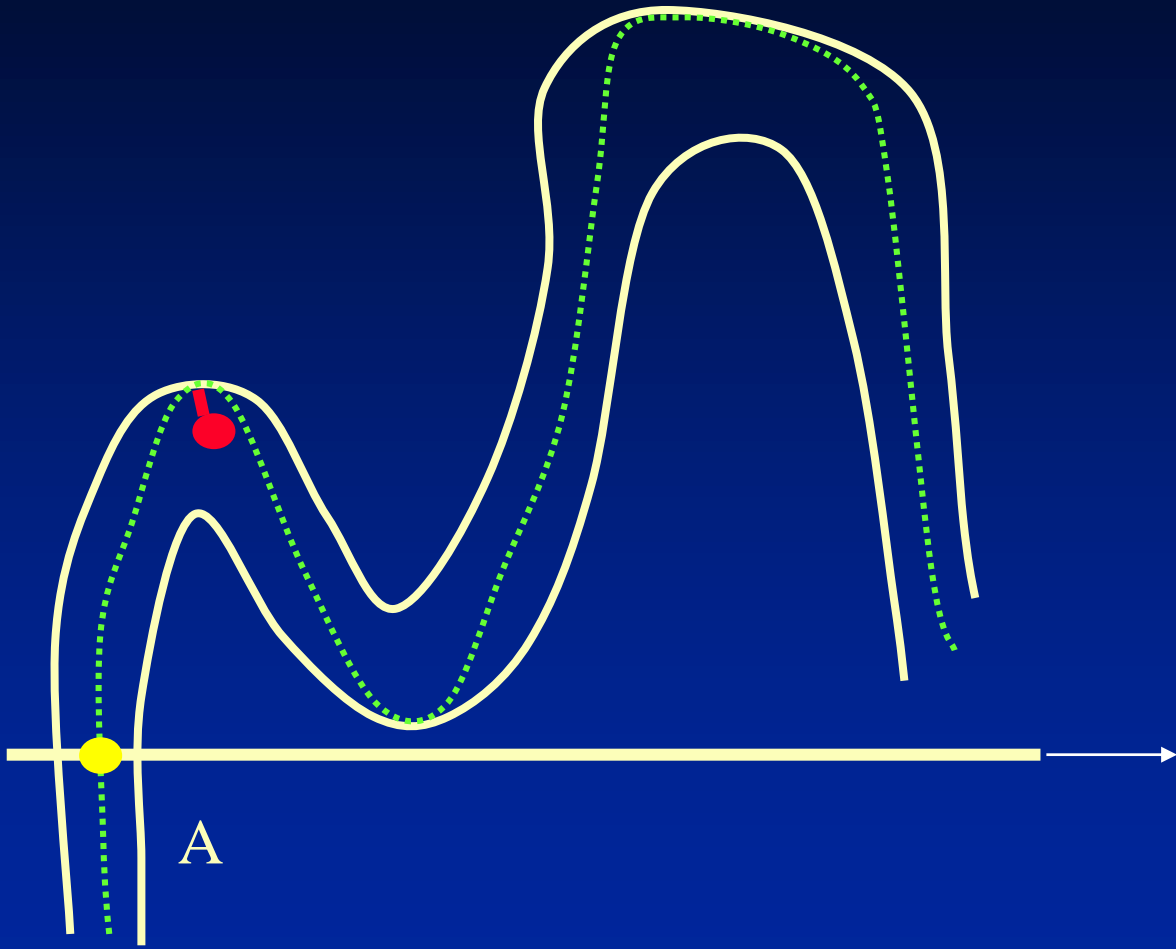
Center Tracking



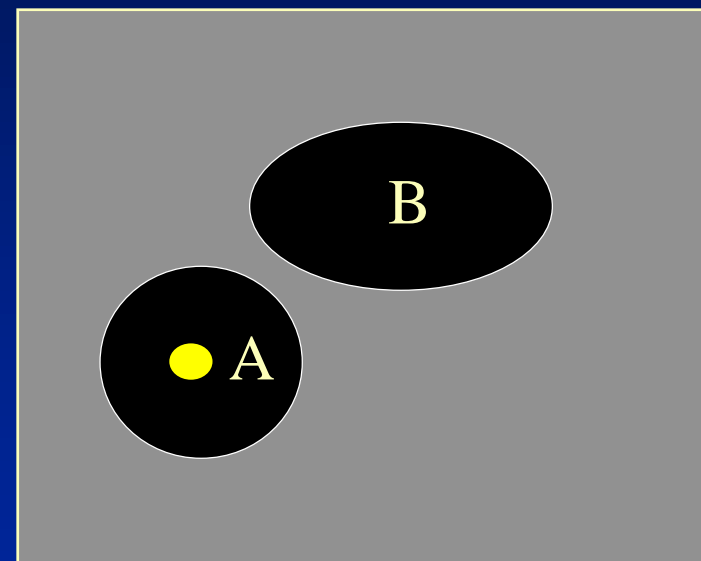
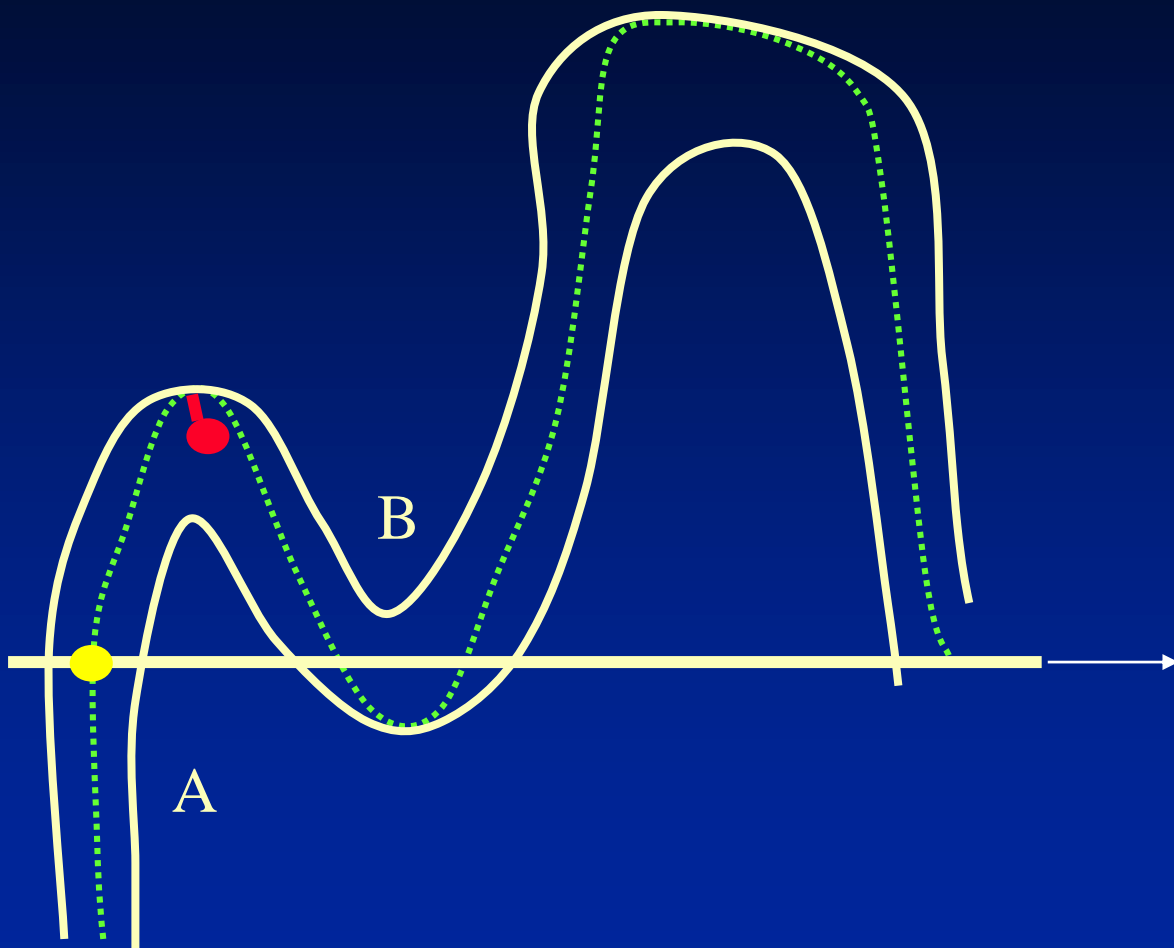
Center Tracking



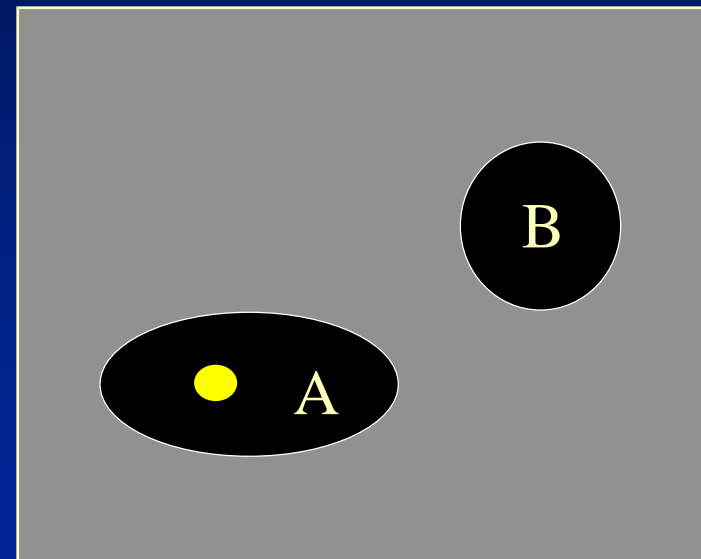
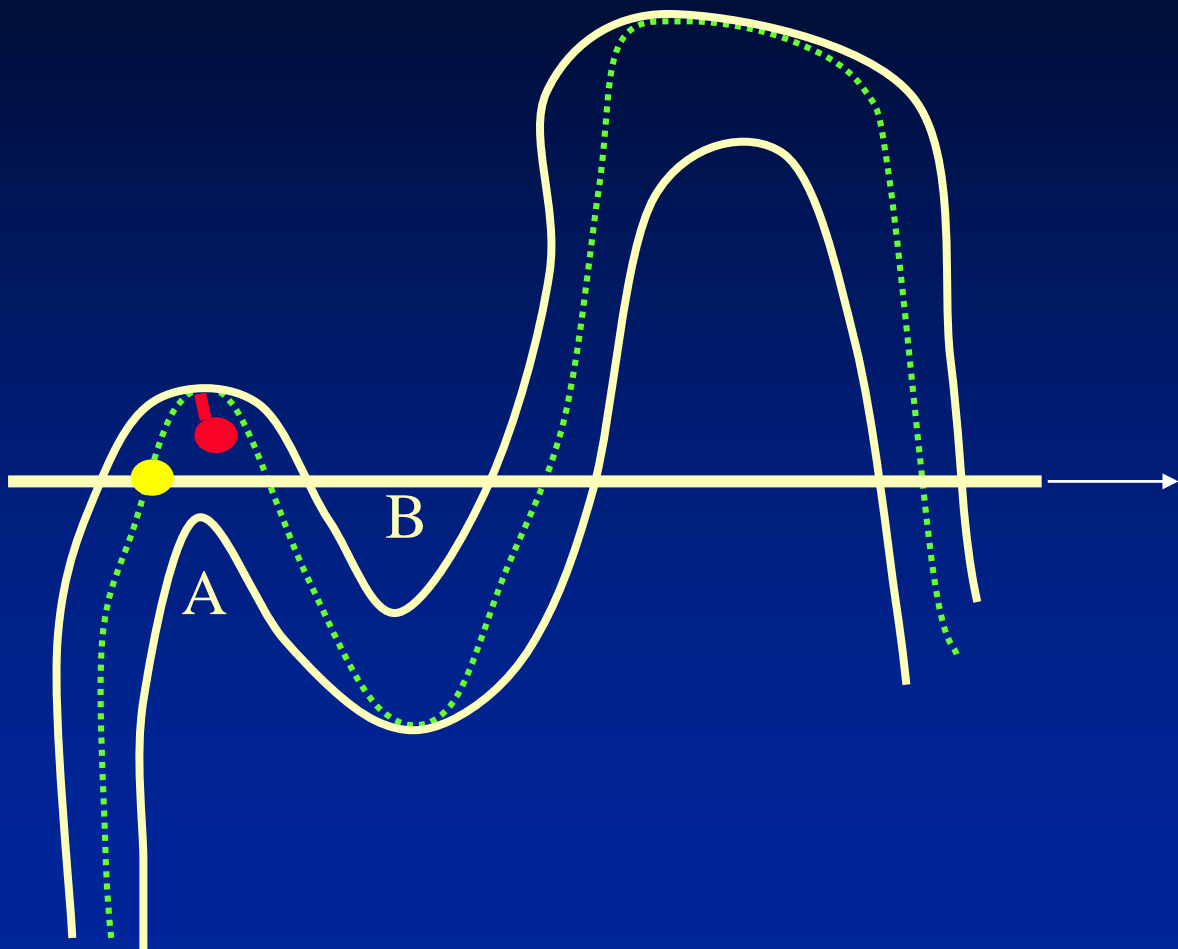
Lumen Tracking



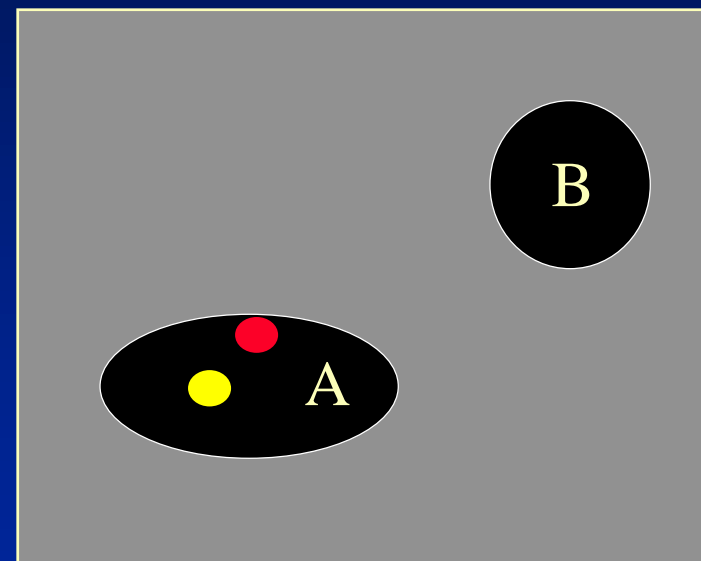
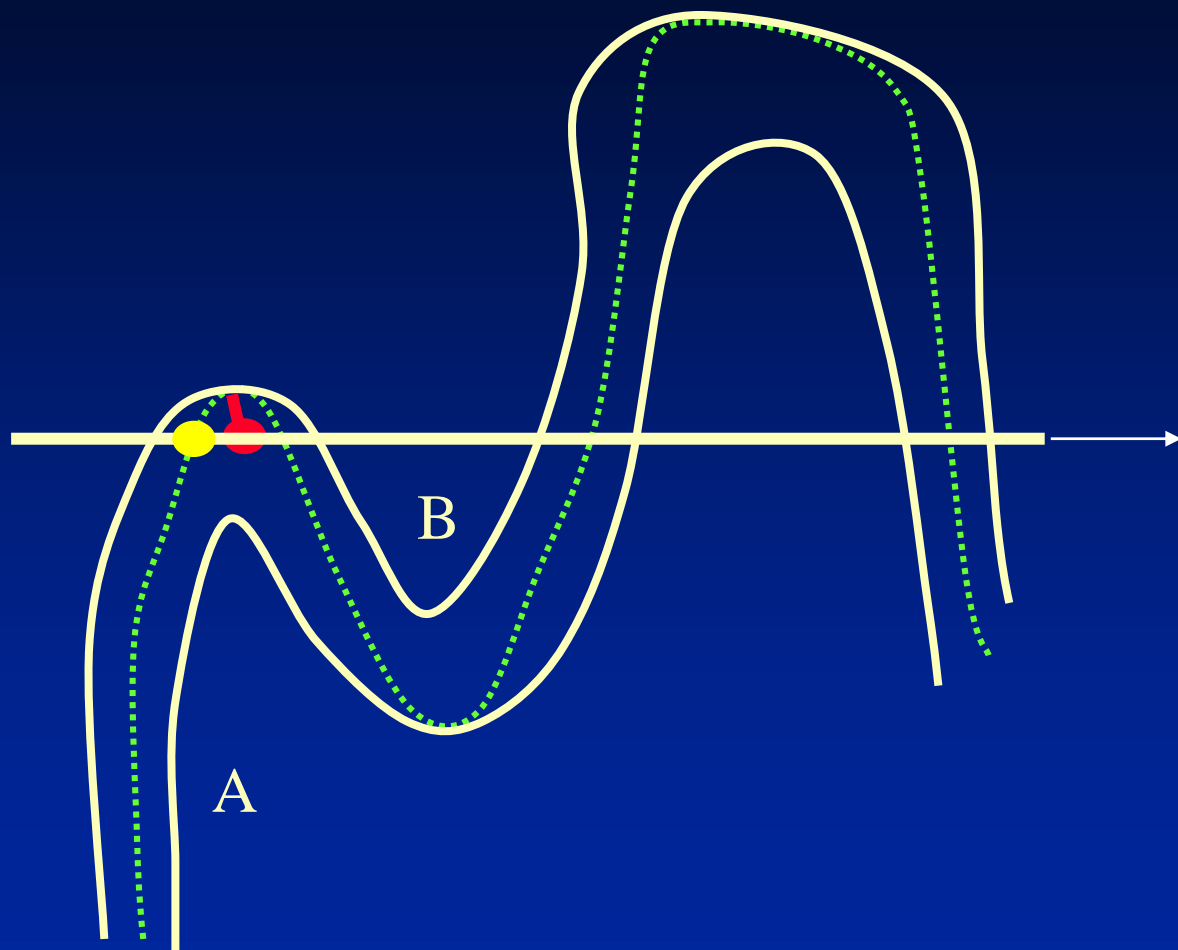
Lumen Tracking



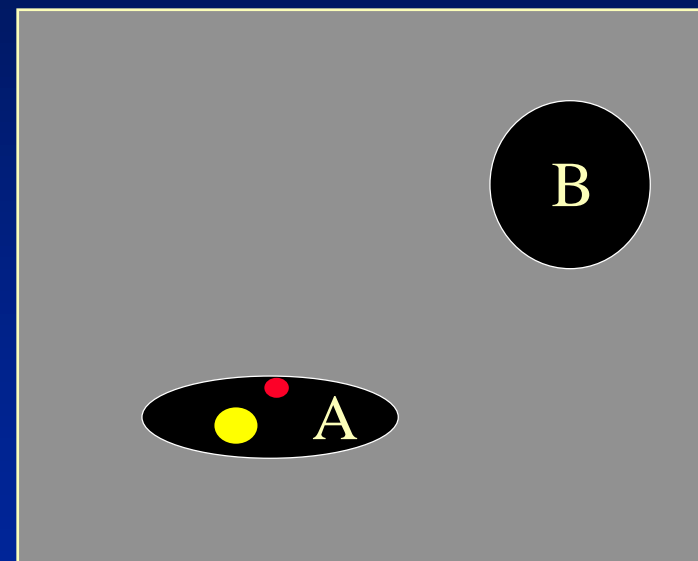
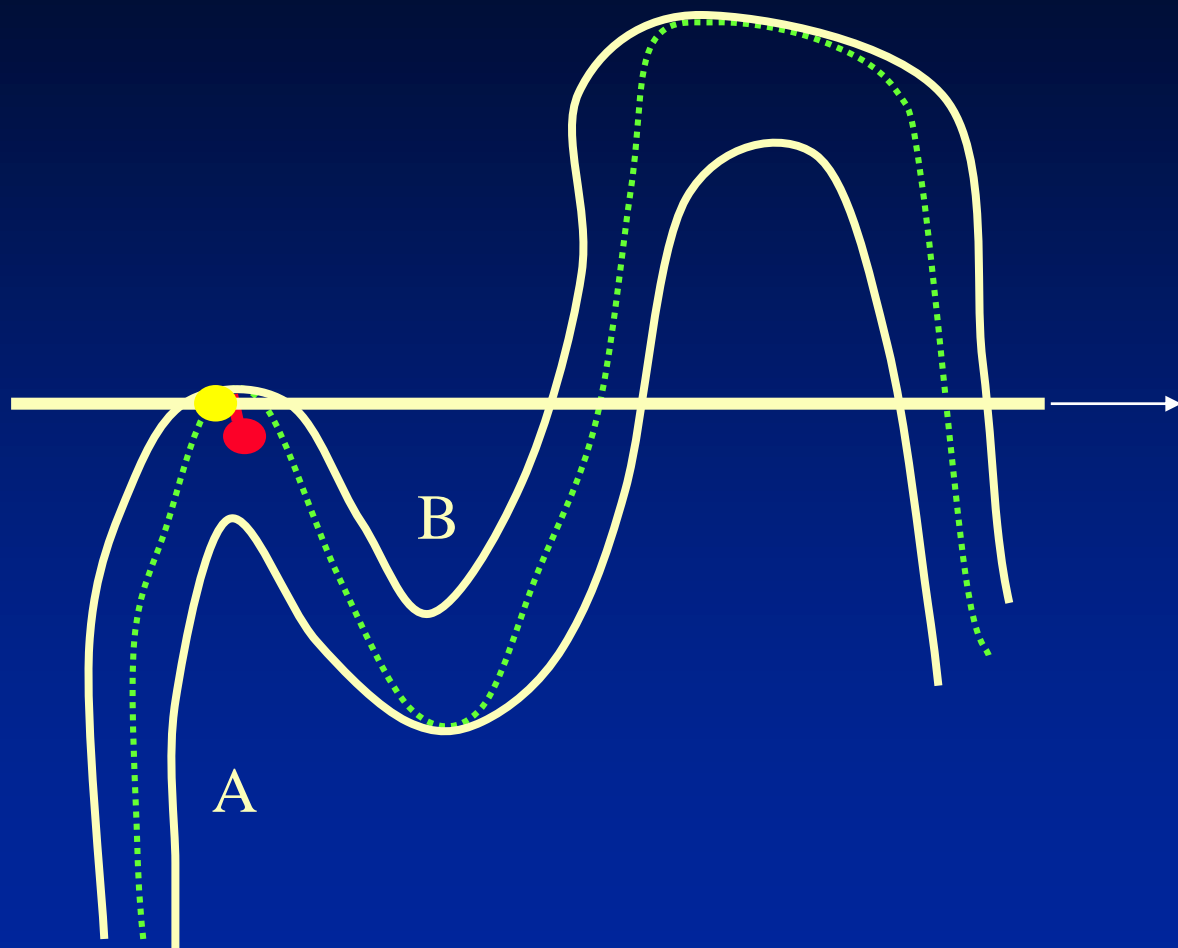
Lumen Tracking



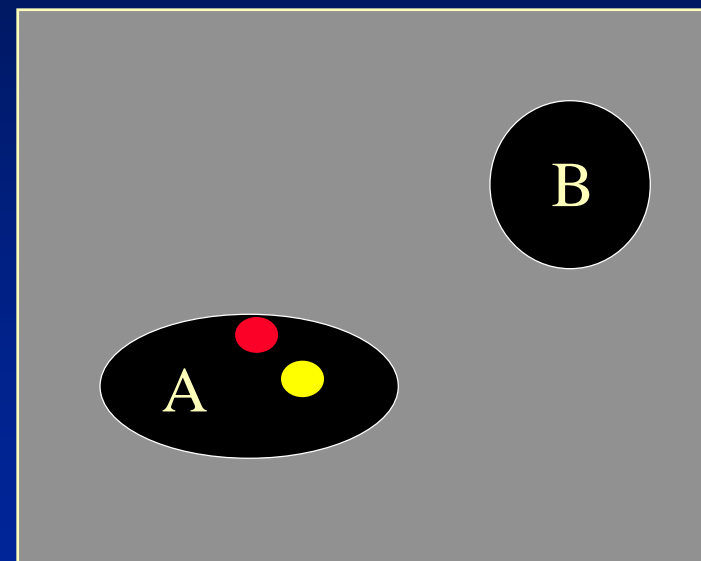
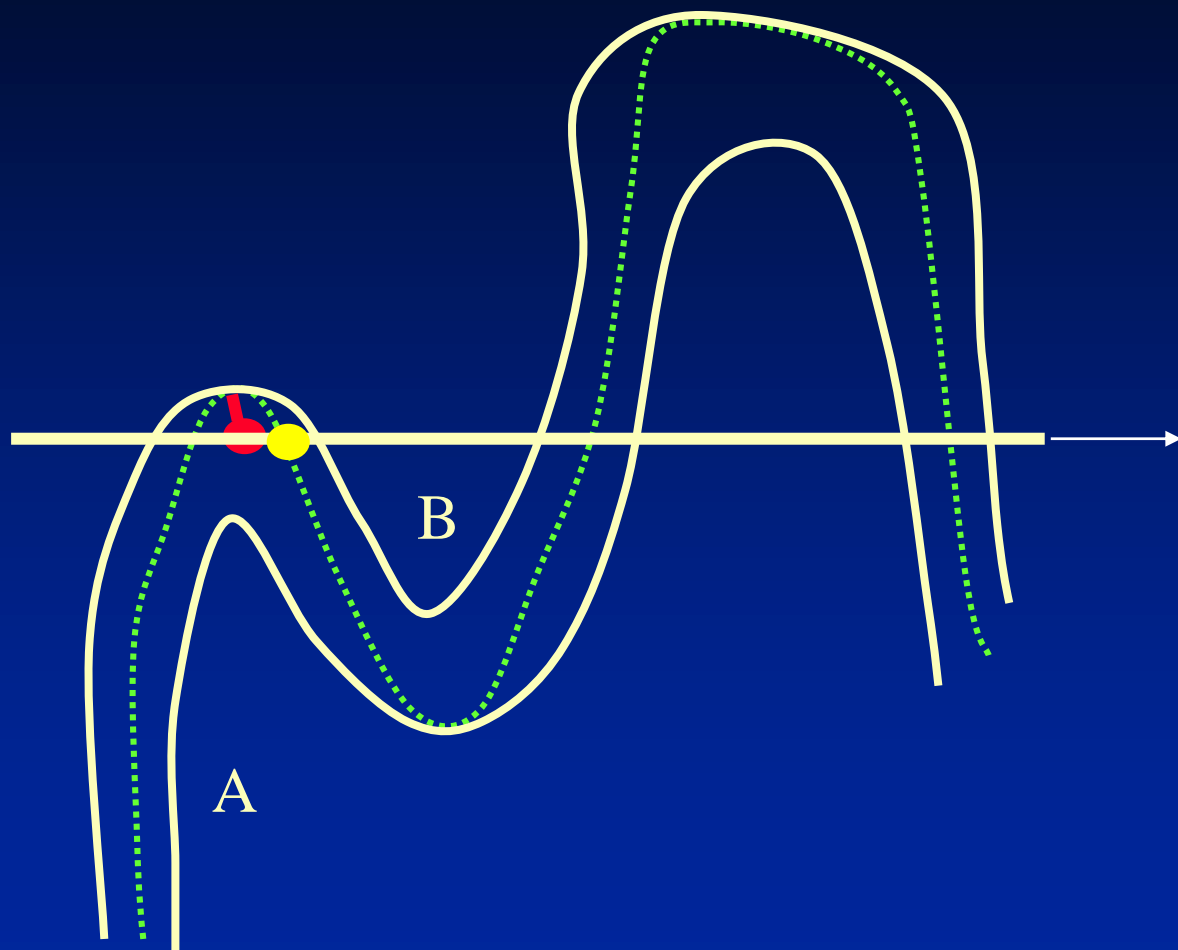
Lumen Tracking



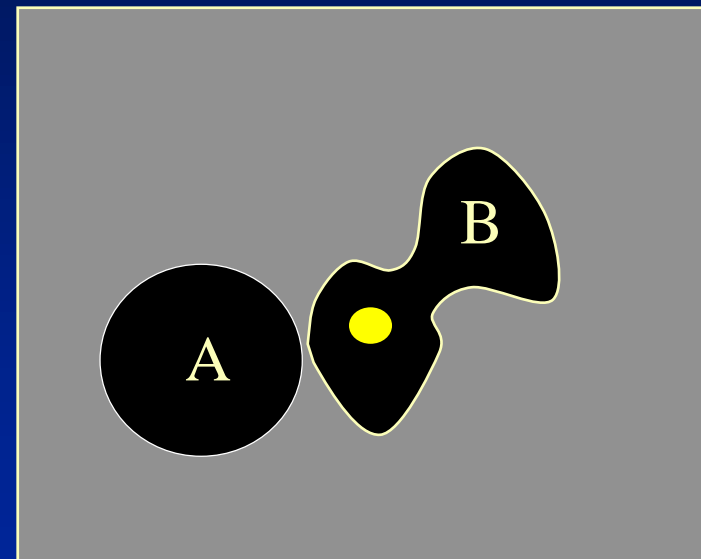
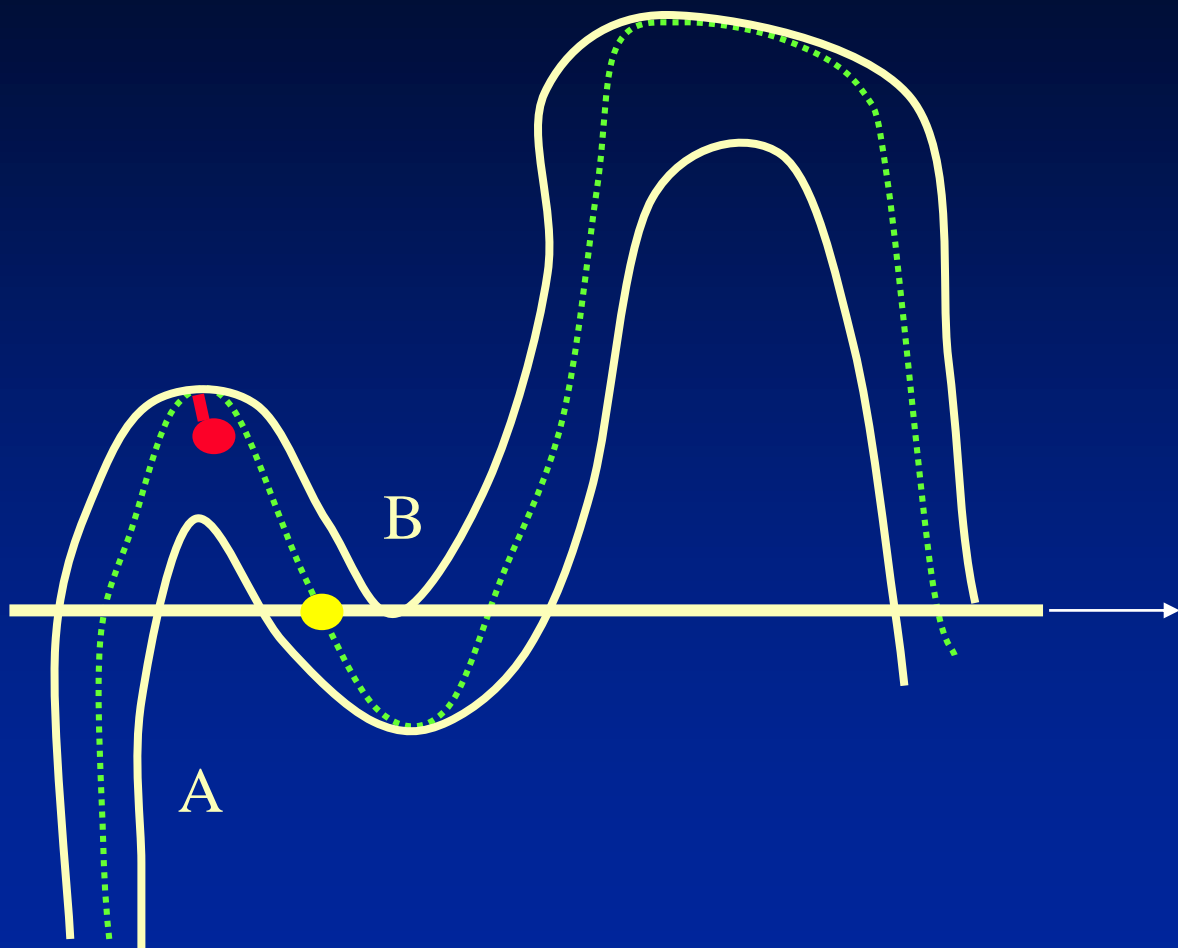
Lumen Tracking



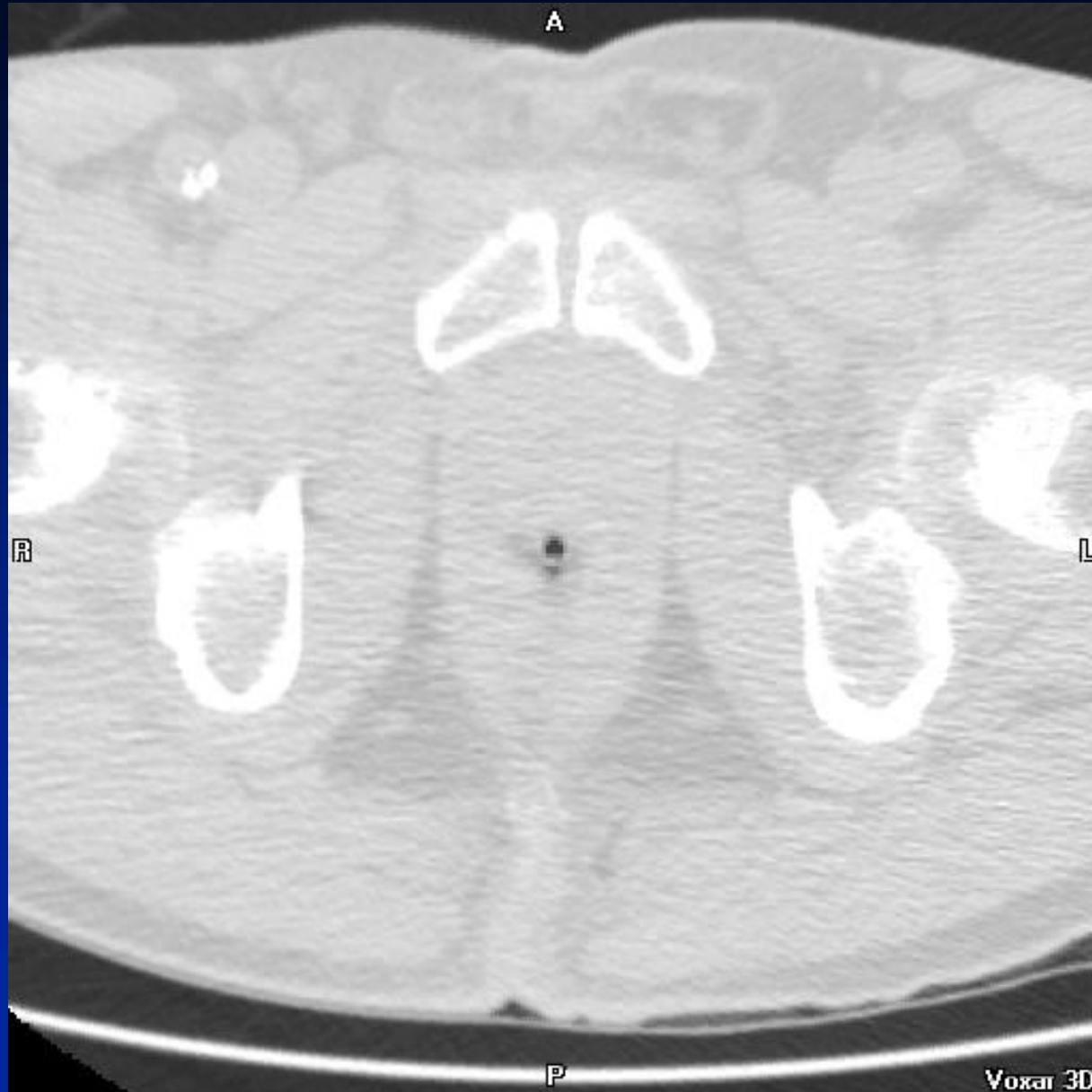Lumen Tracking



Lumen Tracking



Lumen Tracking - Manual

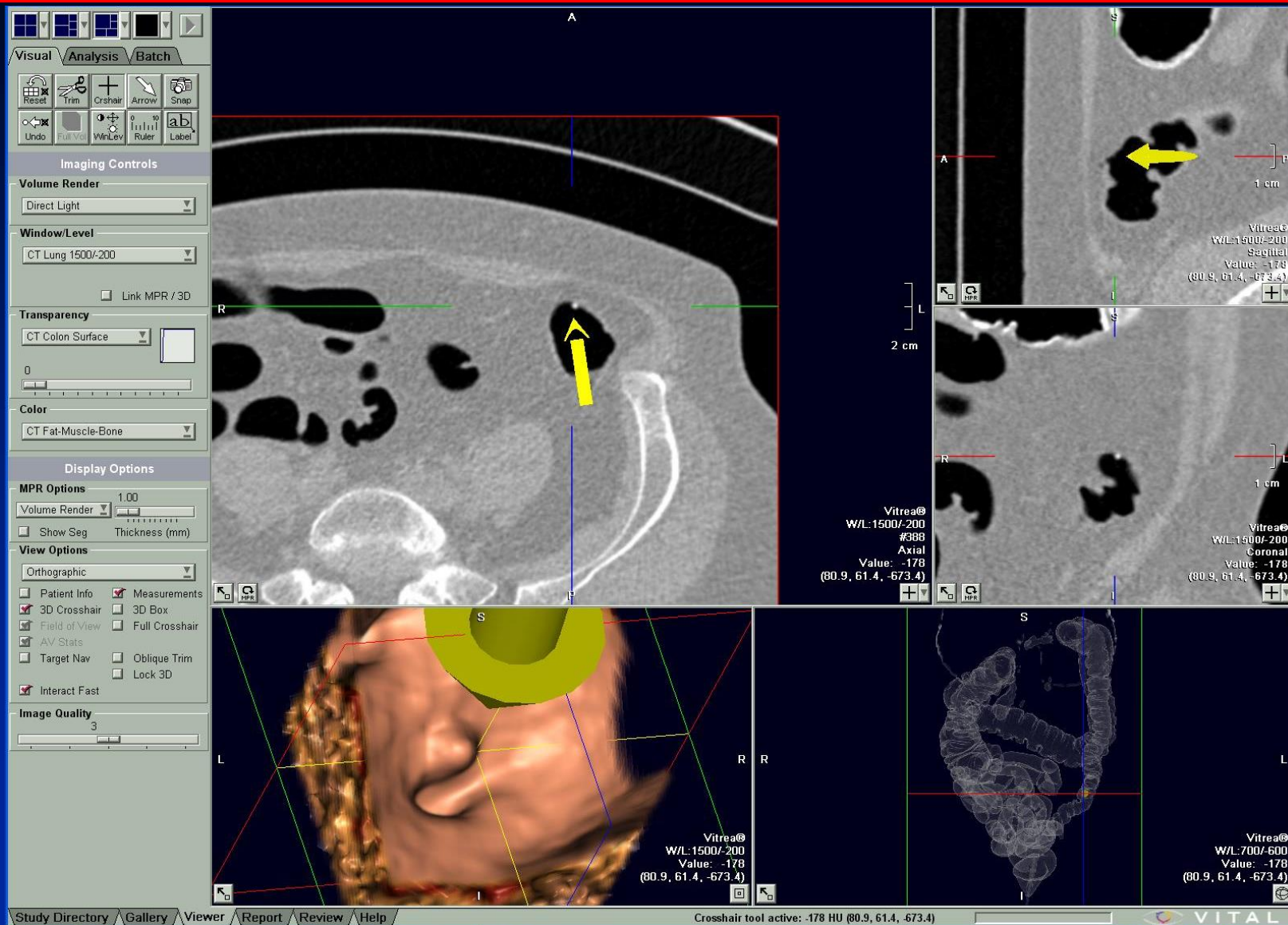


2D Detection



- +++ Visualization of entire colonic mucosa
- +++ Detection beneath obscuring fluid, stool, etc.
- +++ Simultaneous characterization of density
- +++ Integration of CAD targets
- +/- Differentiation of polyps from normal colon
 - Easy means for navigation through the colon
 - Display lesion on screen for sufficient time

2D Detection – 3D Characterization



Courtesy of:
Vital Images

3D Display Methods

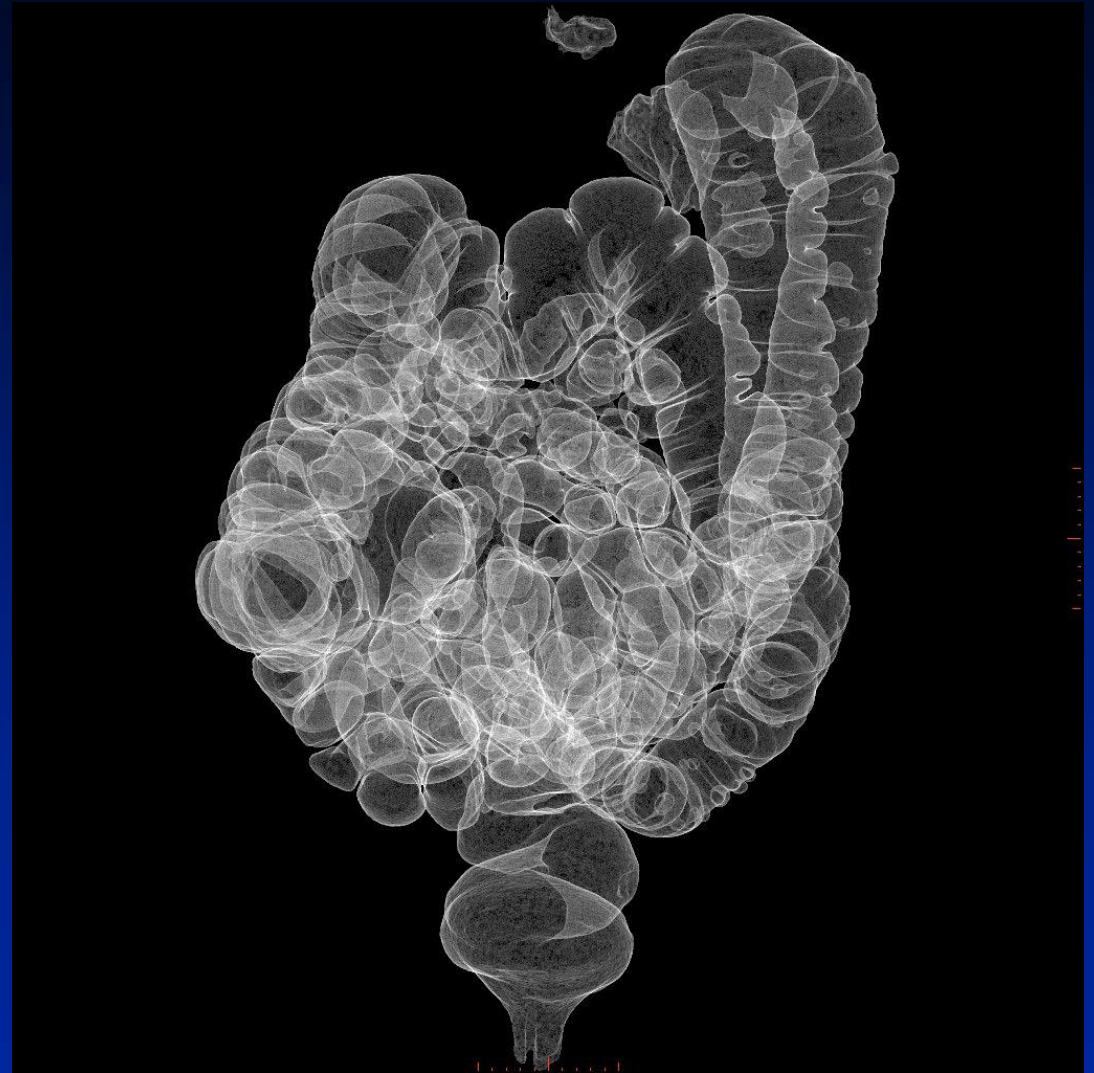

- ◆ 3D Display methods should allow:
 - Easy means for navigation through the colon
 - Display lesion on screen for sufficient detection time
 - Perception of polyps from normal features of colon
 - Visualization of entire colonic mucosa
 - Detection beneath obscuring fluid, tagged stool, etc.
 - Integration of CAD targets

3D Navigation

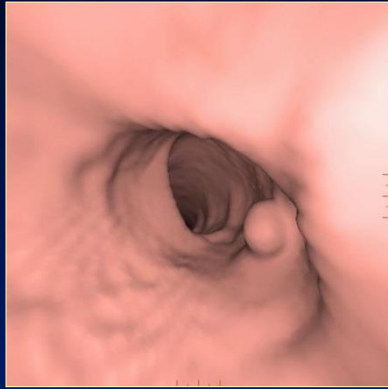

- ◆ Determine air-filled structures
- ◆ Extract colon
- ◆ Determine centerline for fly-through

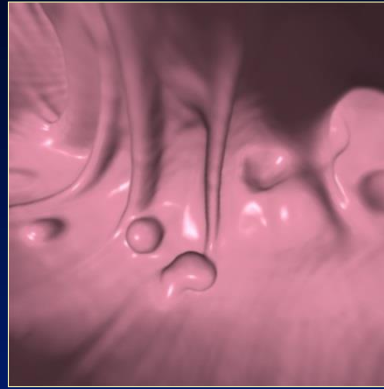


Courtesy of:
GE Medical Systems

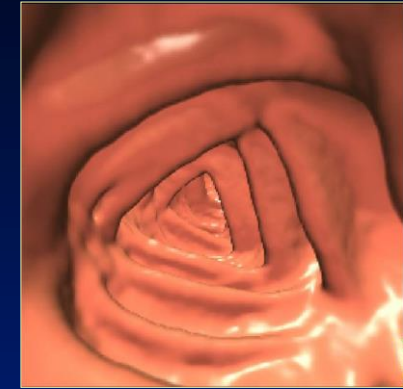3D Endoluminal Review



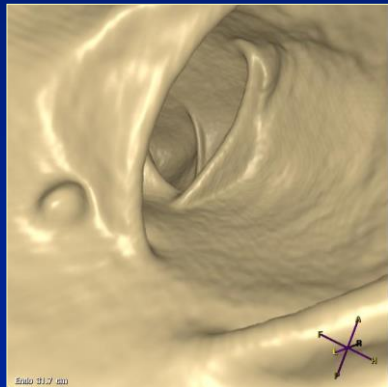
GE



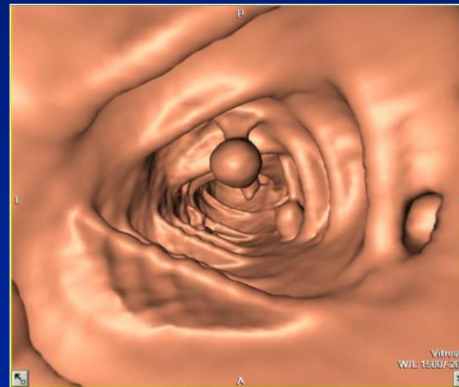
TeraRecon



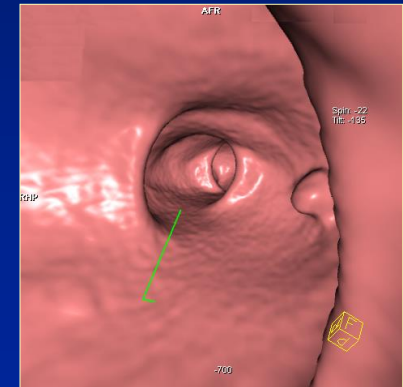
Viatronix



Philips



Vital Images



Siemens

Newer Visualization Strategies



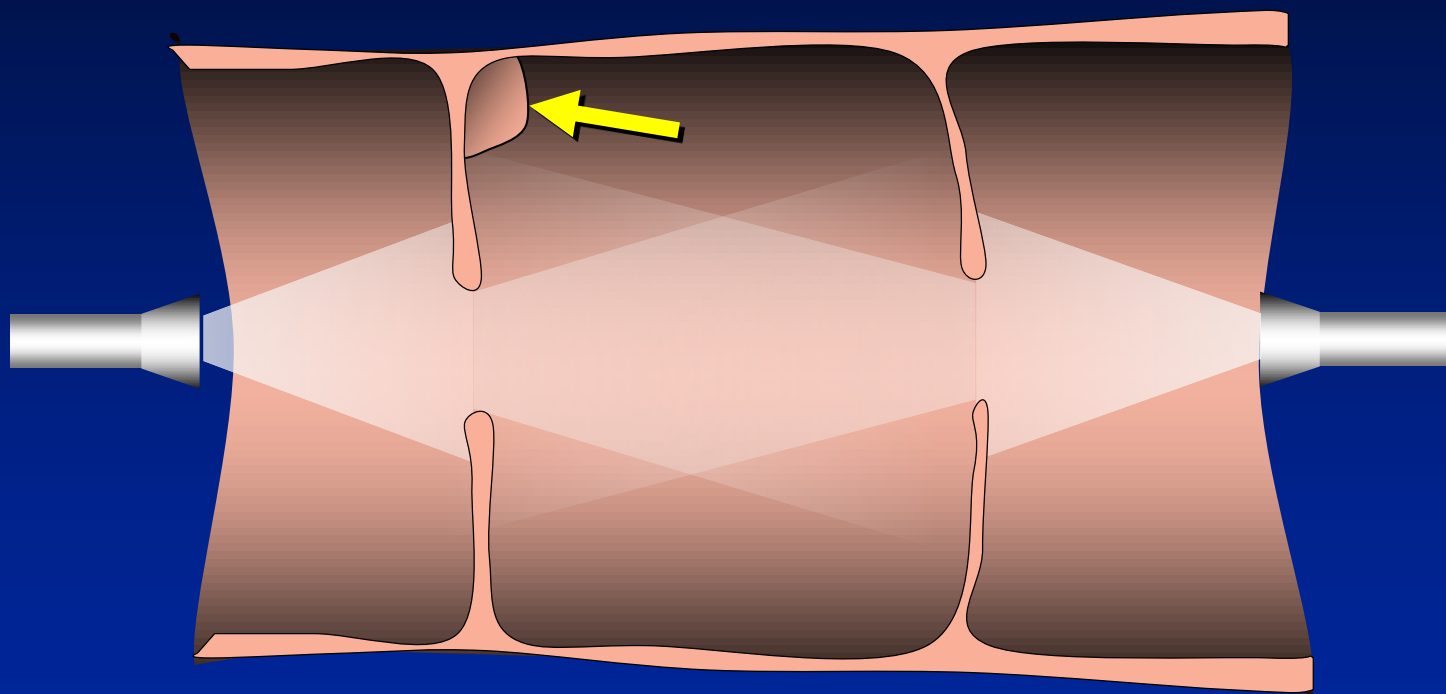
◆ 3D Review Methods

- Increase the visible surface area per unit time
 - Increased time for lesion detection (longer screen dwell time)
 - Increased conspicuity of small lesions
 - Allows for simultaneous detection and characterization of lesion morphology
- ... **but** need to confirm or provide means of viewing the entire colonic mucosa

Problems with Primary 3D Fly-through

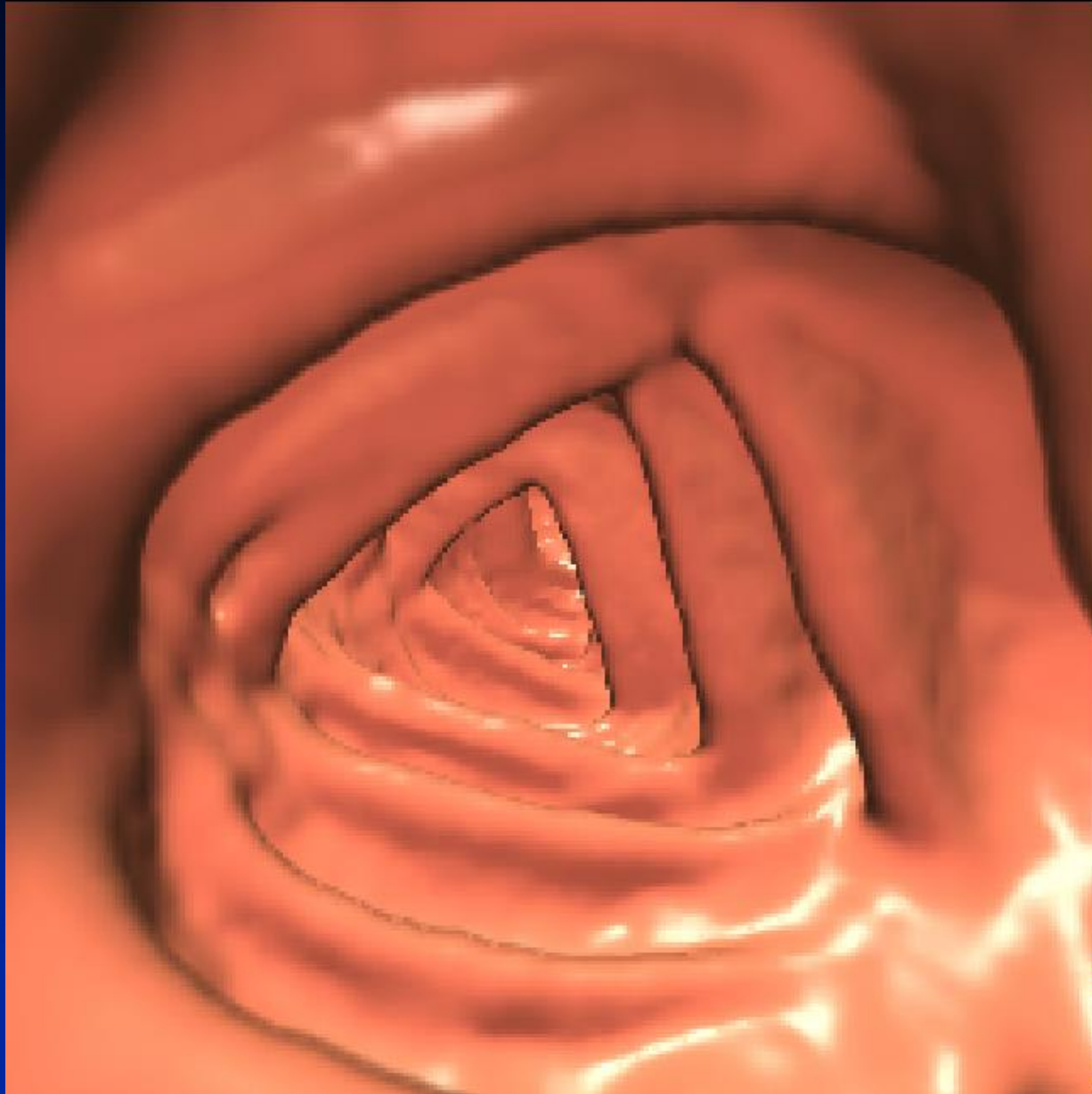


- ◆ Difficulty to see around folds



- ◆ Inability to confirm complete colonic visualization

Polyp Hidden Behind Fold



Courtesy of:
Viatronix

Problems with 3D Fly-through

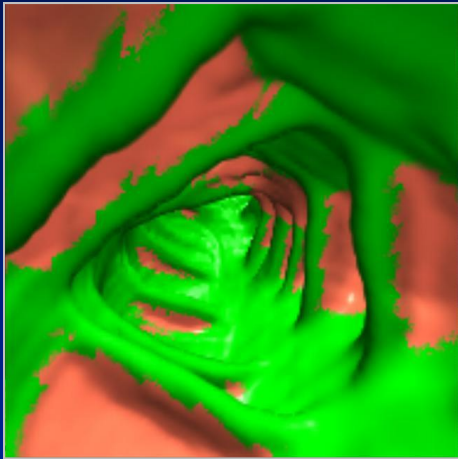


- ◆ With endoluminal 3D reading, one needs to verify that one has visualized the entirety of the colonic surface
 - Complete antegrade and retrograde flight paths
 - Mucosal “painting”

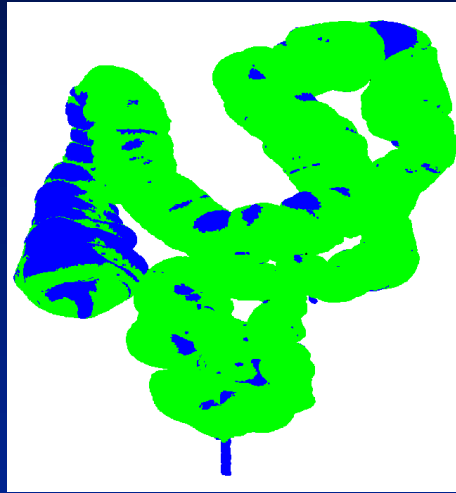
OR

- Offer display method capable of viewing behind folds during review

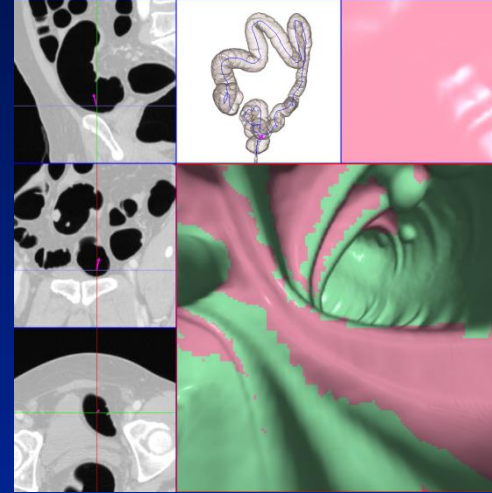
Mucosal "Painting"



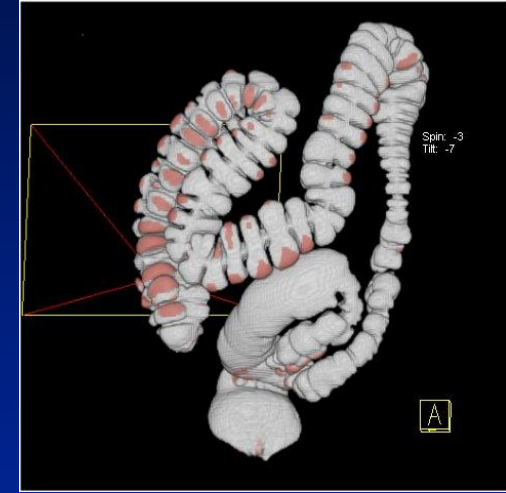
Courtesy of:
Viatronix



Courtesy of:
Vital Images
Pending FDA Approval



Courtesy of:
TeraRecon



Courtesy of:
Siemens

Solving the “Hidden Colon” Problem



- ◆ Paint visualized areas of the colon, then...
- ◆ Visualize un-seen areas of colon with 2nd look

OR (equally valid) provide:

- ◆ Advanced display technique
 - Allows visualization around / behind folds;
Eliminate need for mucosal painting
 - Added benefit of increase the amount of displayable colonic surface in a given unit of time



◆ Interpretation and Display Methods

– 2D

- Lumen tracking
- 3D Problem solving

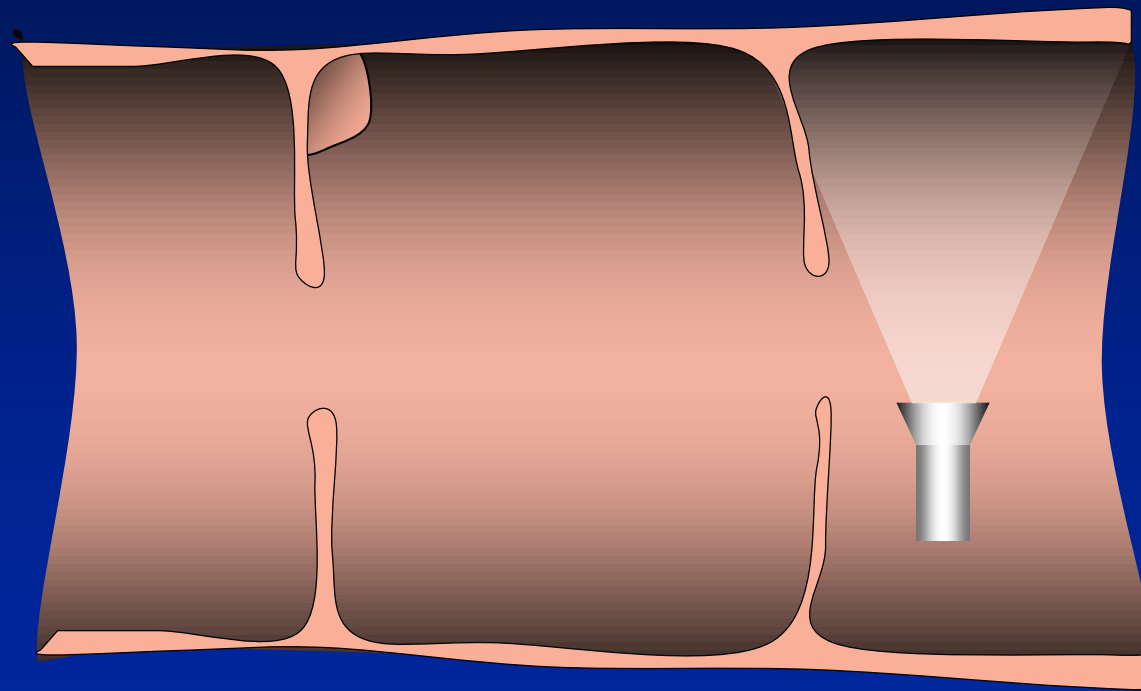
– 3D methods

- 3D cube
- Fly-through
- Fillet view (opened colon)
- Flattened
- Unfolded cube

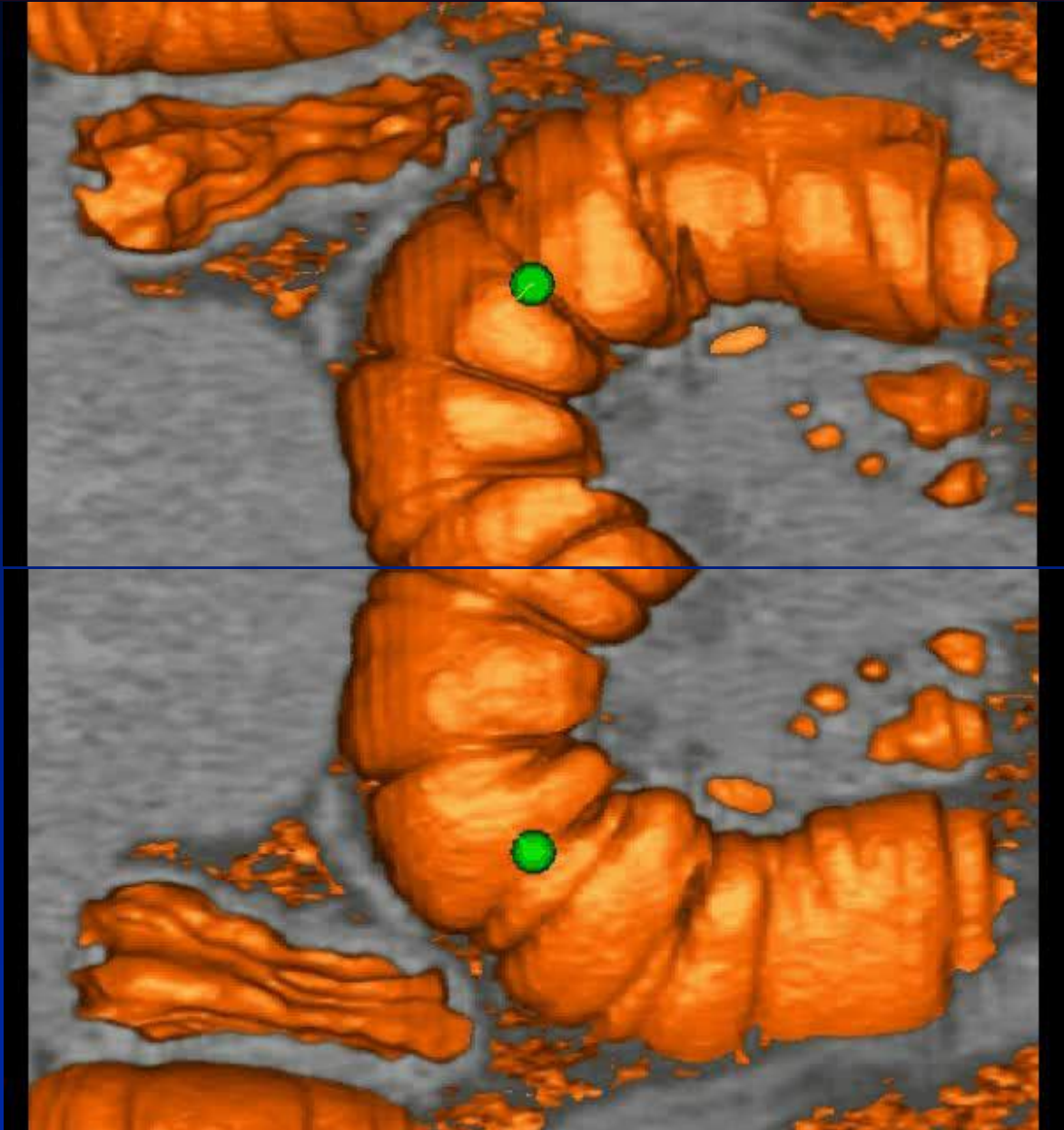
Fillet Views



- ◆ Instead of looking down the colon, the view faces the wall

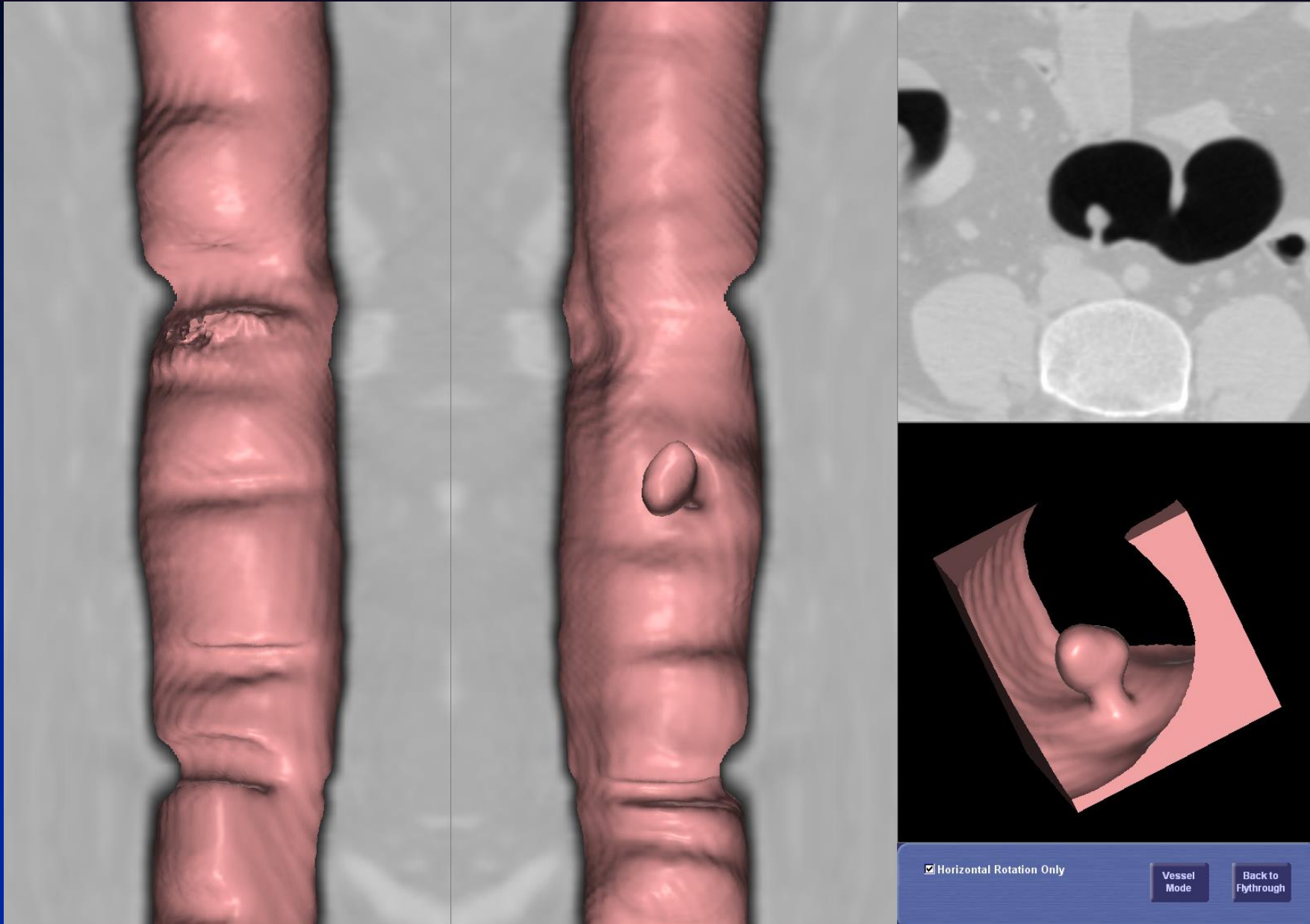


Fillet view



Courtesy of:
Rendoscopy

Fillet view



Courtesy of:
TeraRecon



◆ Interpretation and Display Methods

– 2D

- Lumen tracking
- 3D Problem solving

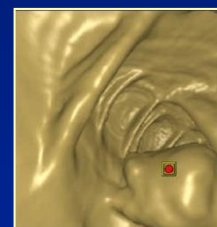
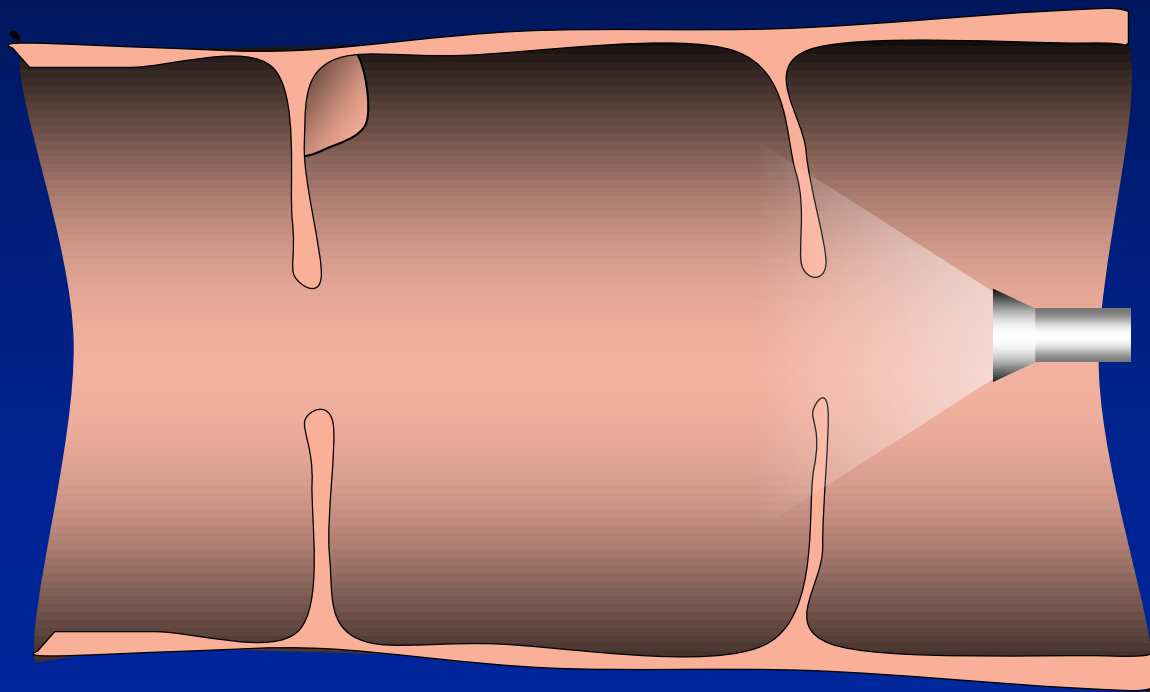
– 3D methods

- 3D cube
- Fly-through (and Fly-around)
- Fillet
- Unfolded cube
- Flattened

Unfolded Cube




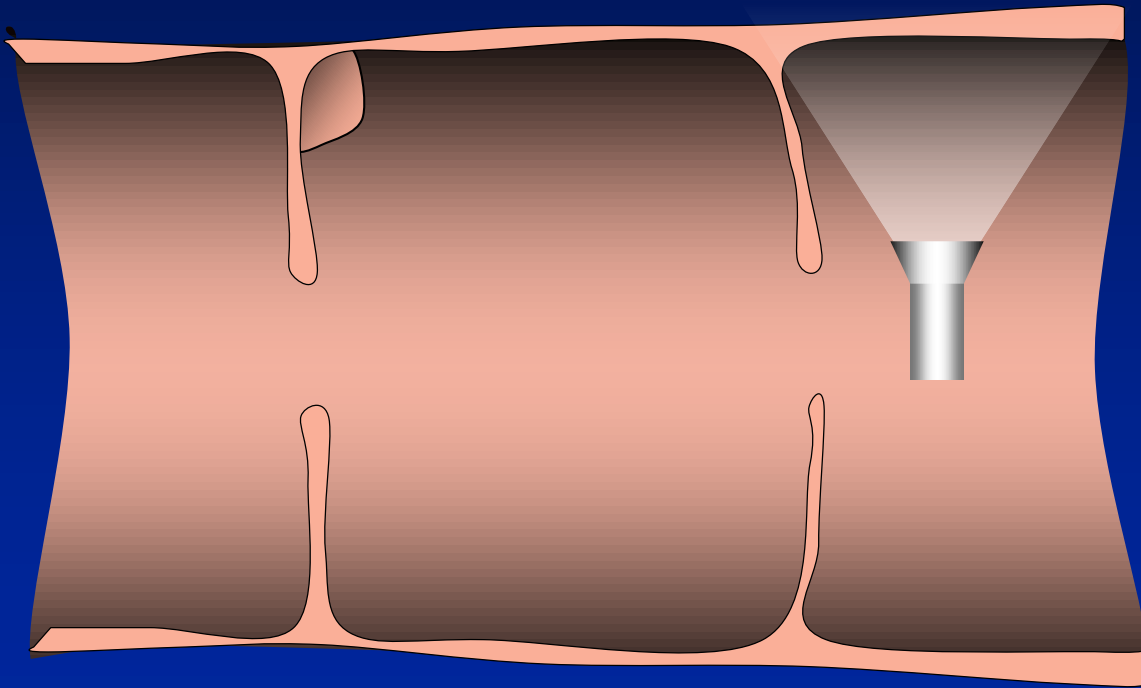
- ◆ In addition to looking down the colon, the view faces in all directions (including reverse)



Unfolded Cube



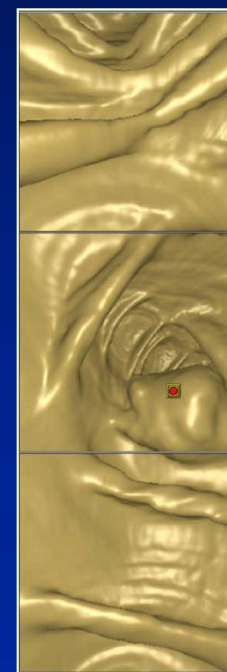
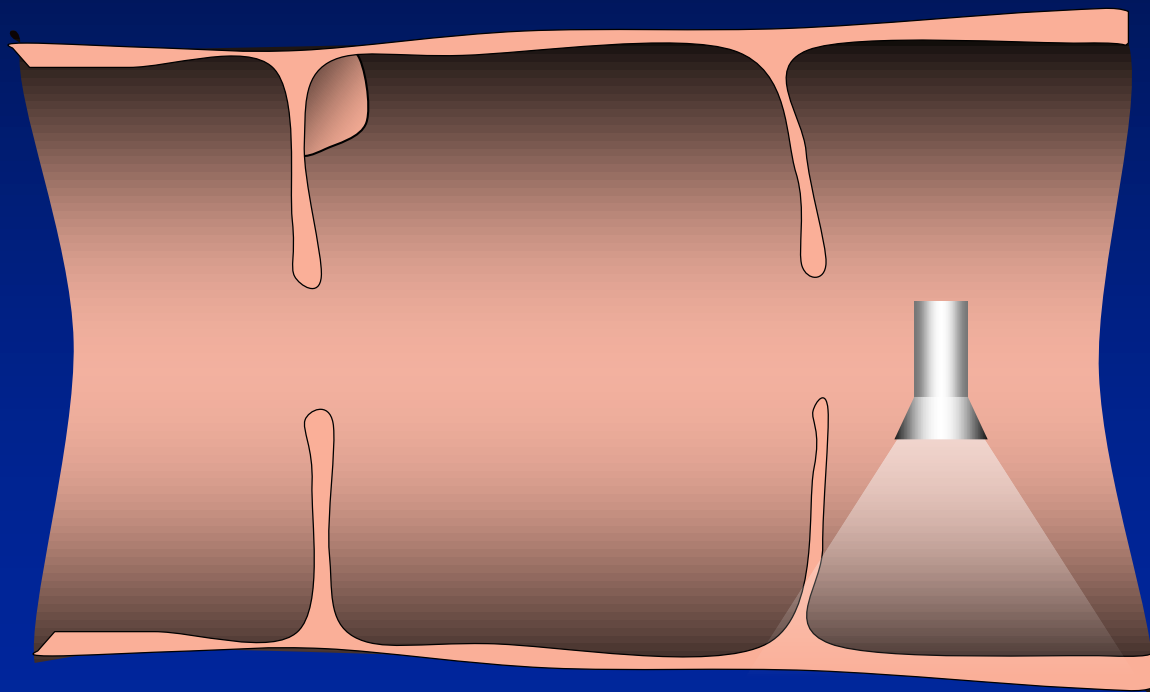
- ◆ In addition to looking down the colon, the view faces in all directions (including reverse)



Unfolded Cube




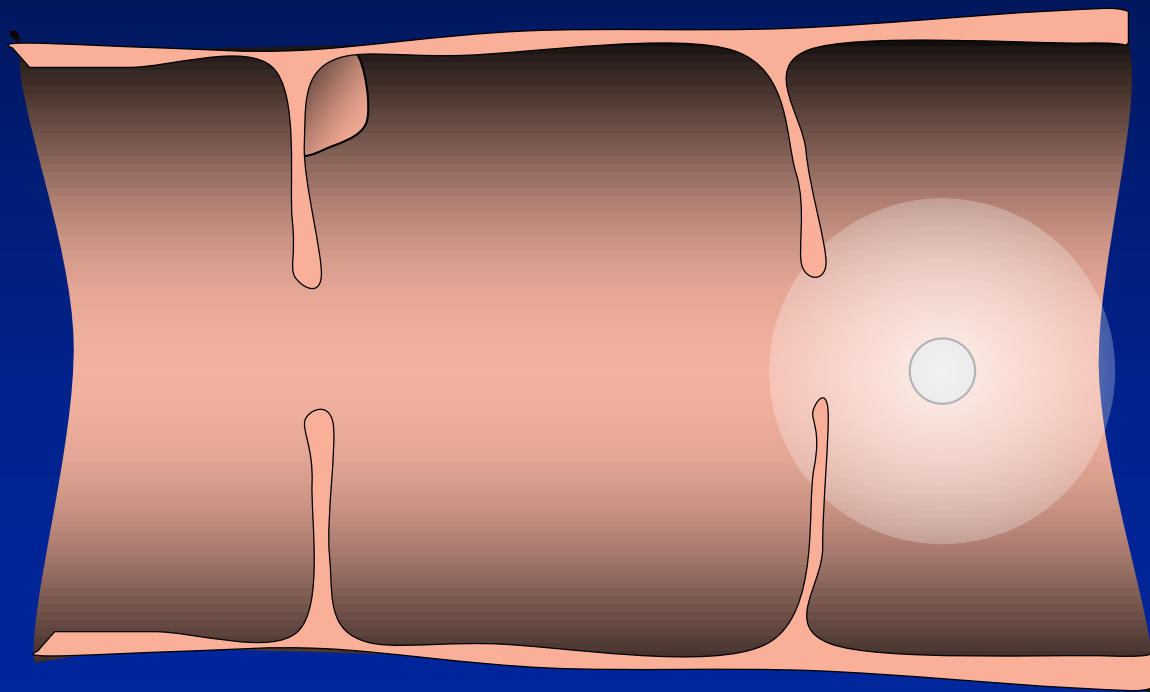
- ◆ In addition to looking down the colon, the view faces in all directions (including reverse)



Unfolded Cube



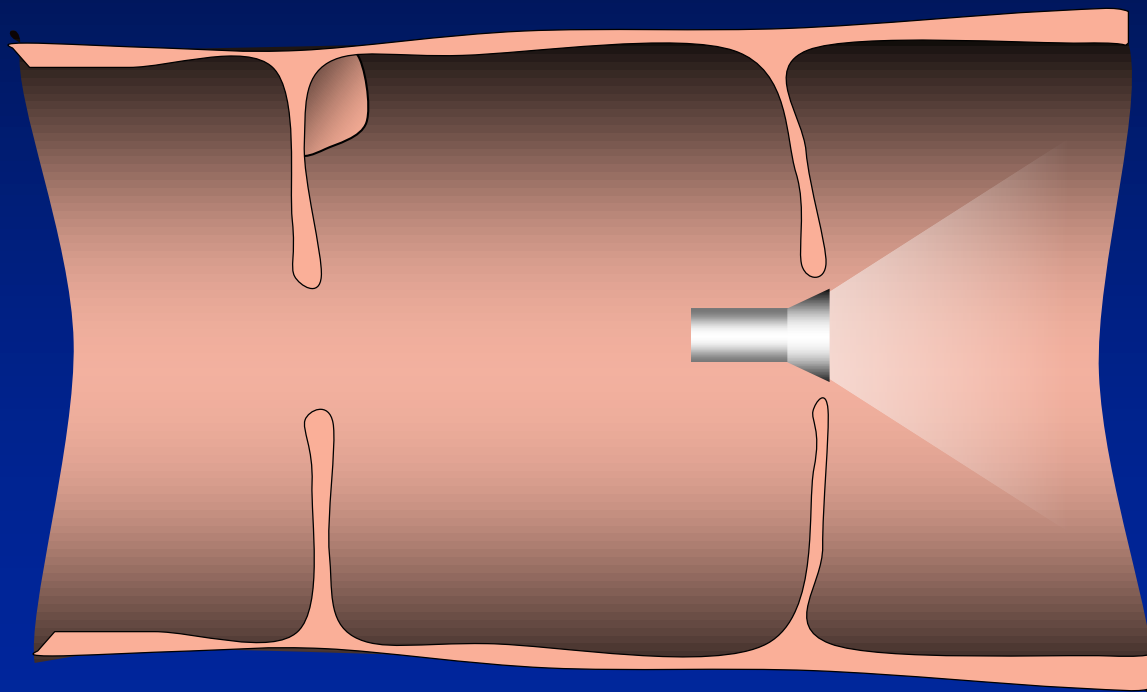
- ◆ In addition to looking down the colon, the view faces in all directions (including reverse)



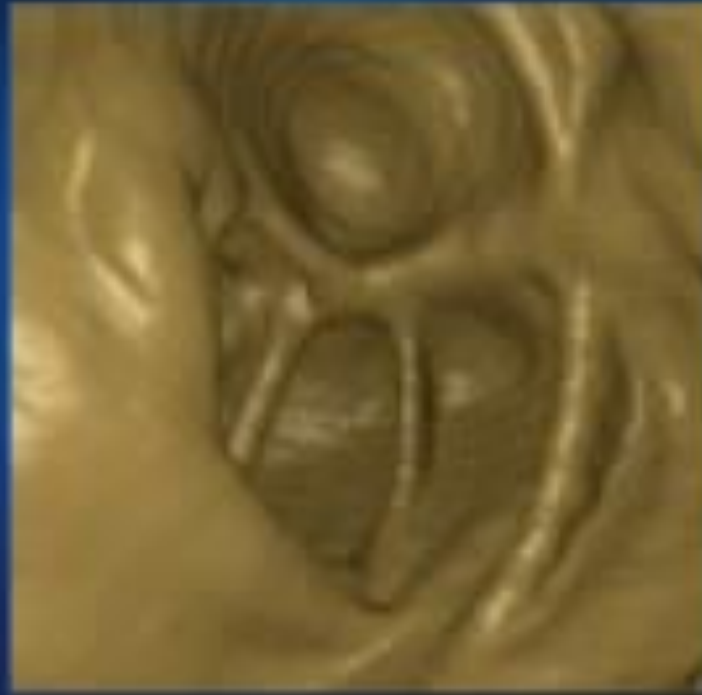Unfolded Cube



- ◆ In addition to looking down the colon, the view faces in all directions (including reverse)

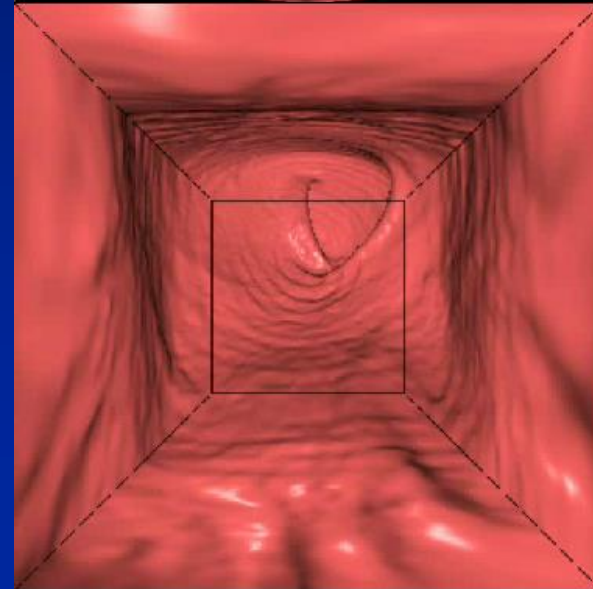
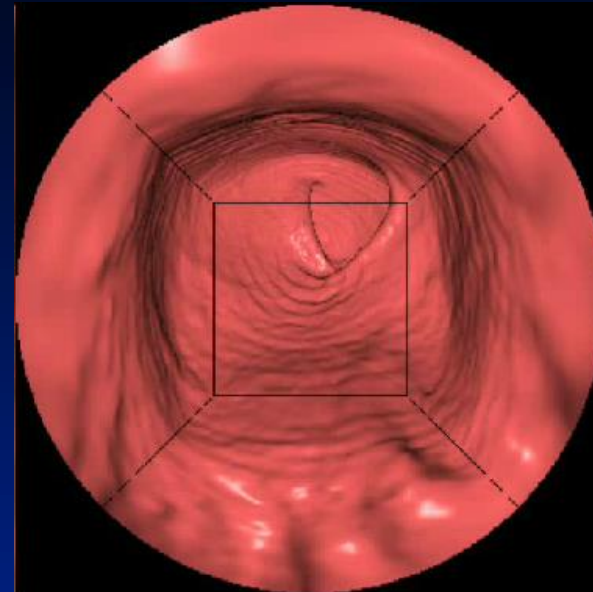
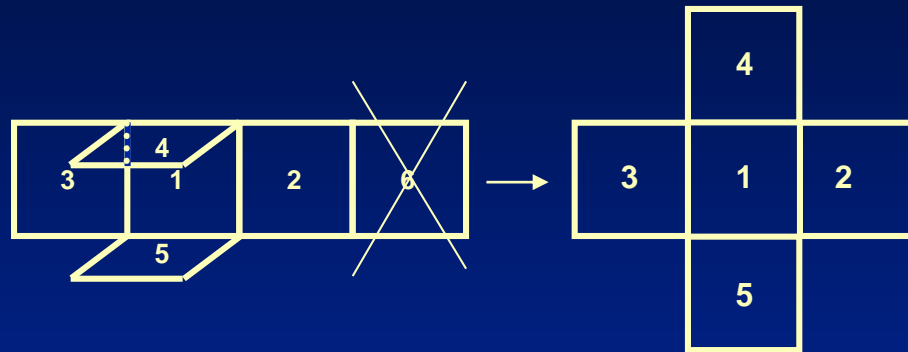


Unfolded Cube



Courtesy of:
Philips

Panoramic View - Unfolded Cube



D. Bielen et. al.: Comparison of a standard and panoramic view in CT colonography: a pilot study, 7th International Symposium for Virtual Colonoscopy.

Mang et al.: Multidetector row CT Colonography: 3D Panoramic view versus standard virtual colonoscopy for the detection of colorectal polyps

Courtesy of:
Siemens



◆ Interpretation and Display Methods

– 2D

- Lumen tracking
- 3D Problem solving

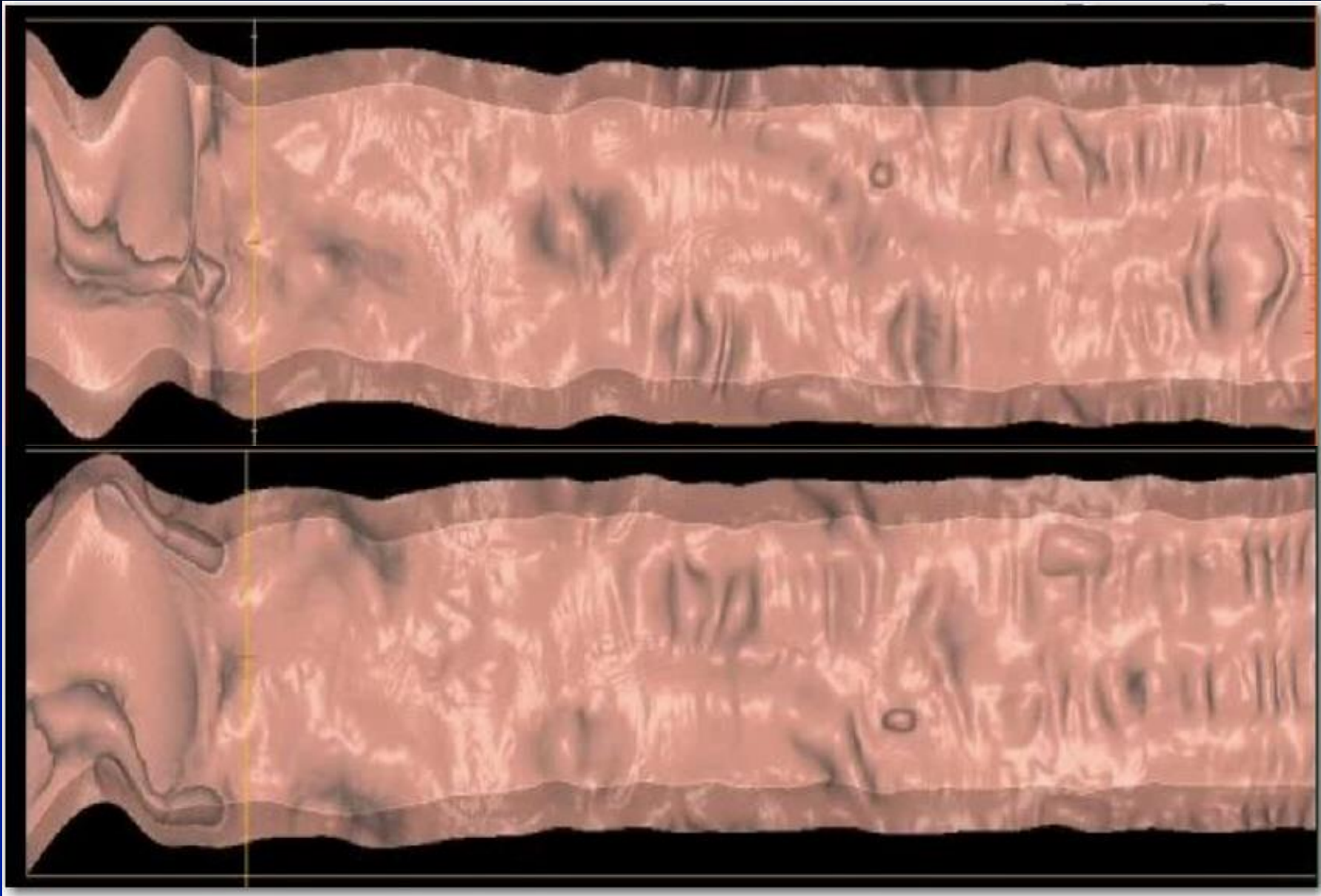
– 3D methods

- 3D cube
- Fly-through
- Fillet
- Unfolded cube
- Flattened (Virtual Pathology)

Fillet view – Flattened & Straightened

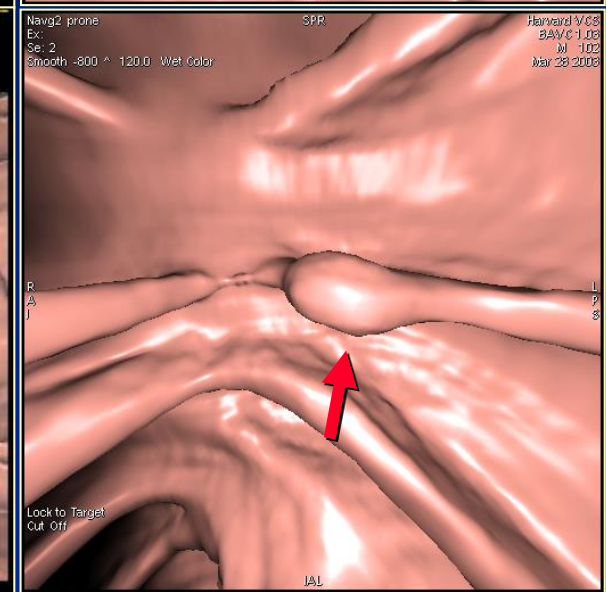
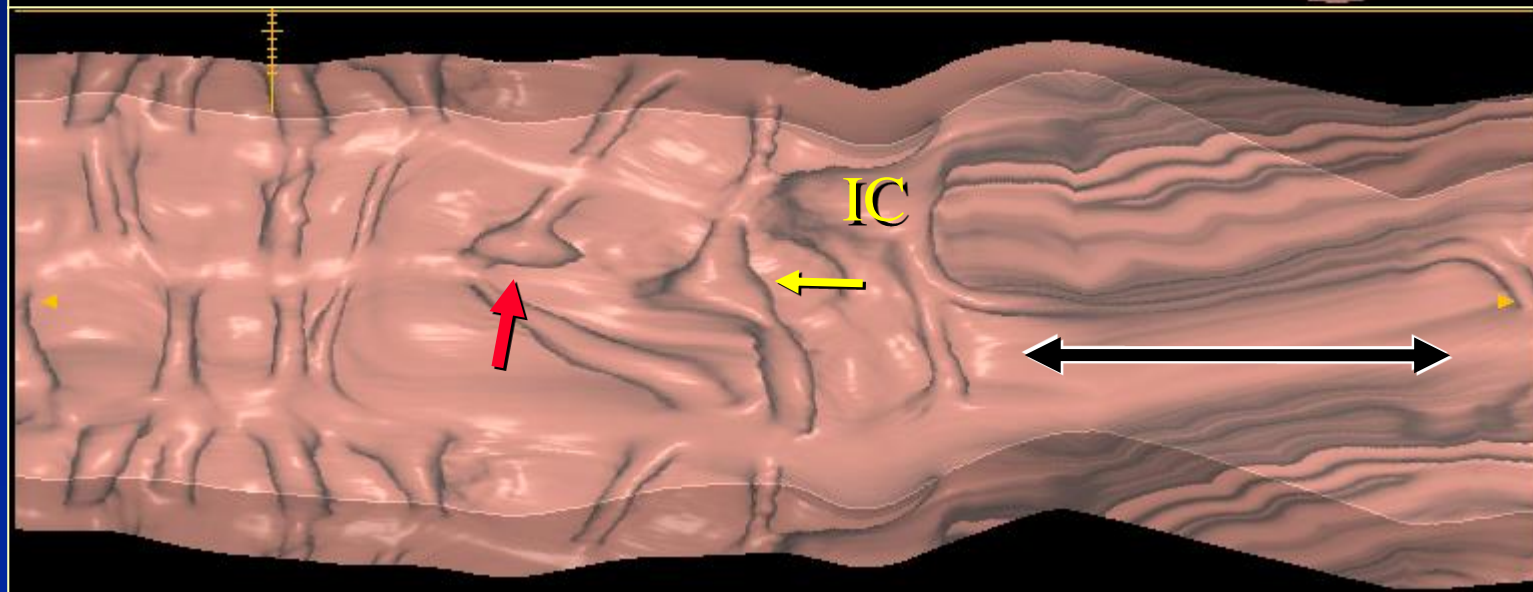
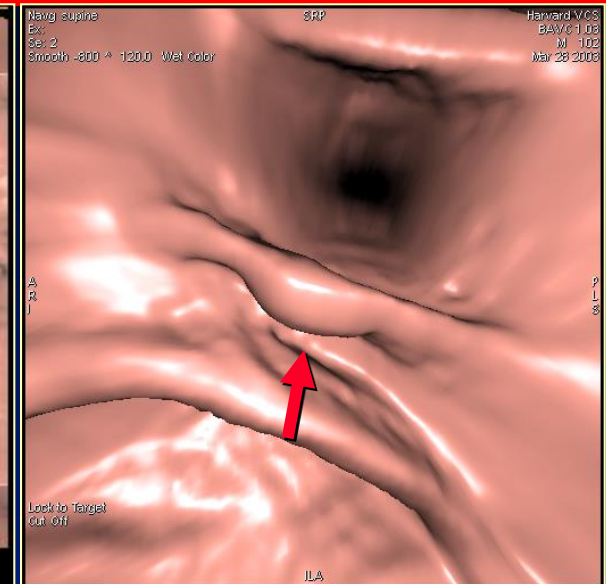
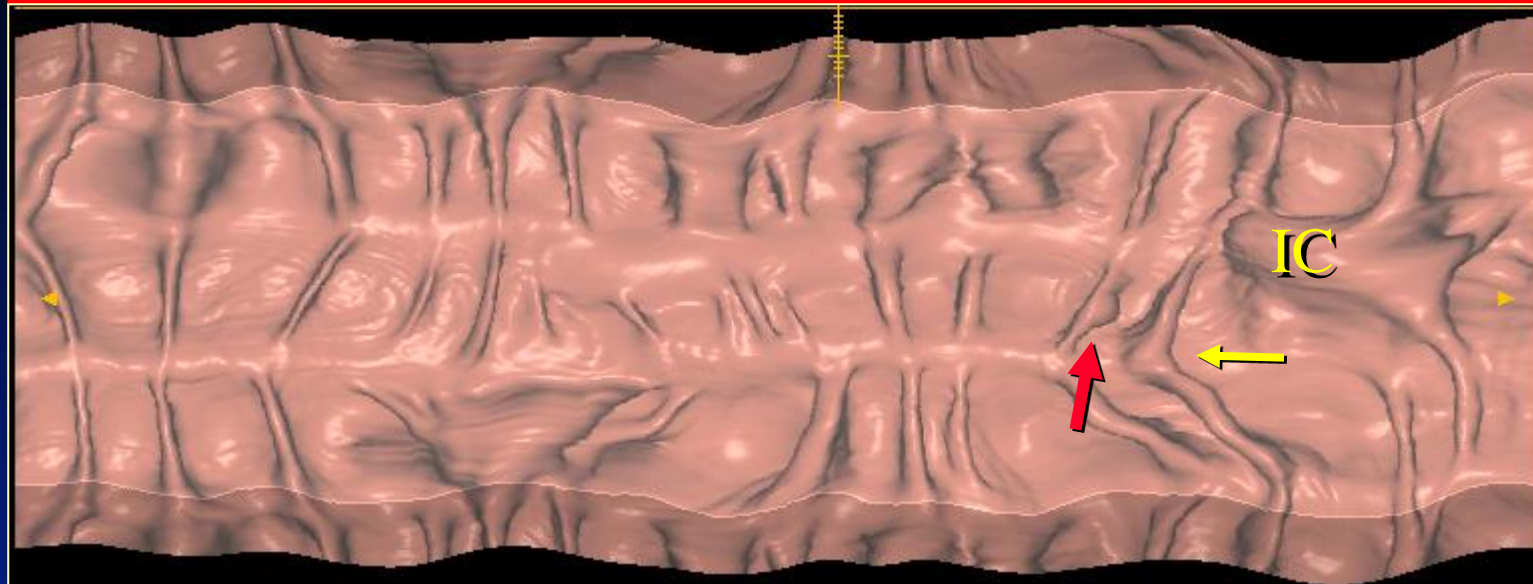


Flattened Colon Display



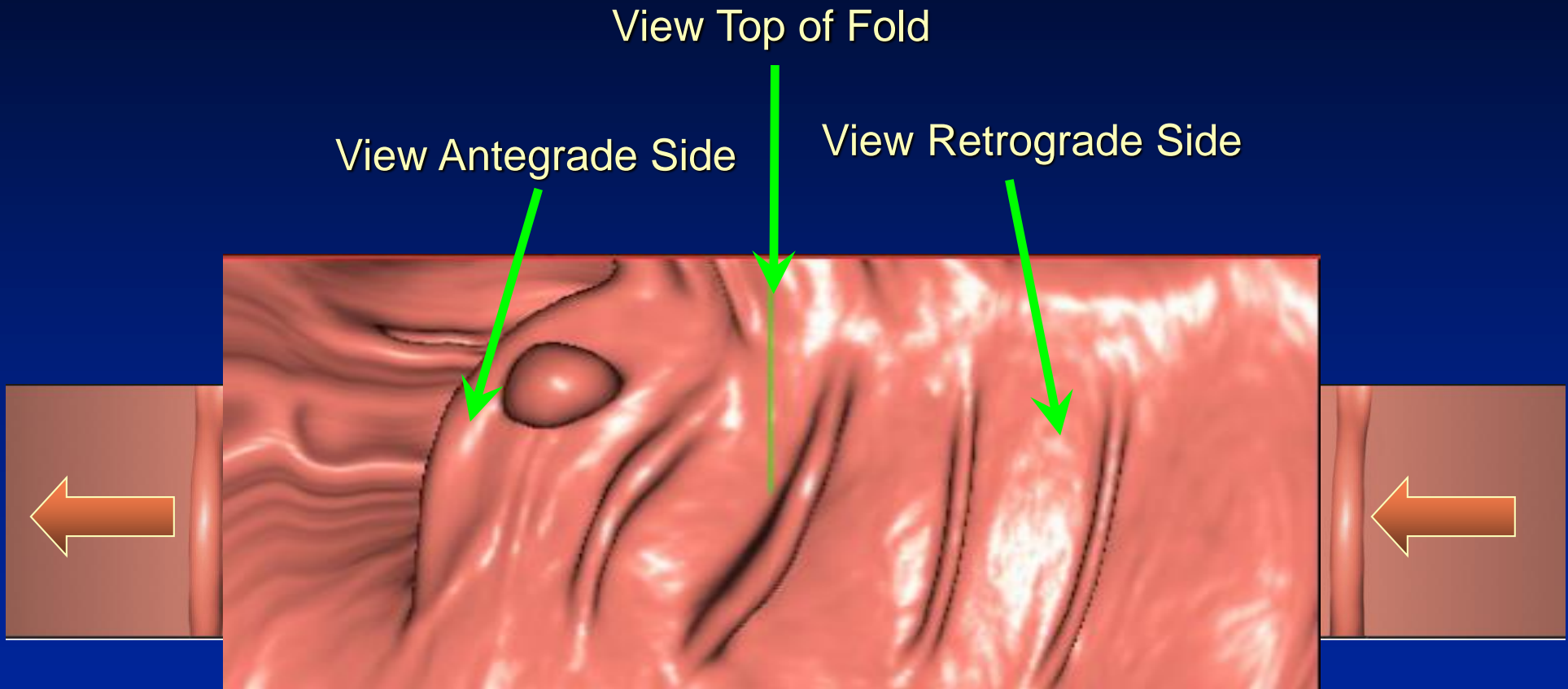
Courtesy:
GE Medical
Systems

Flattened Colon Display



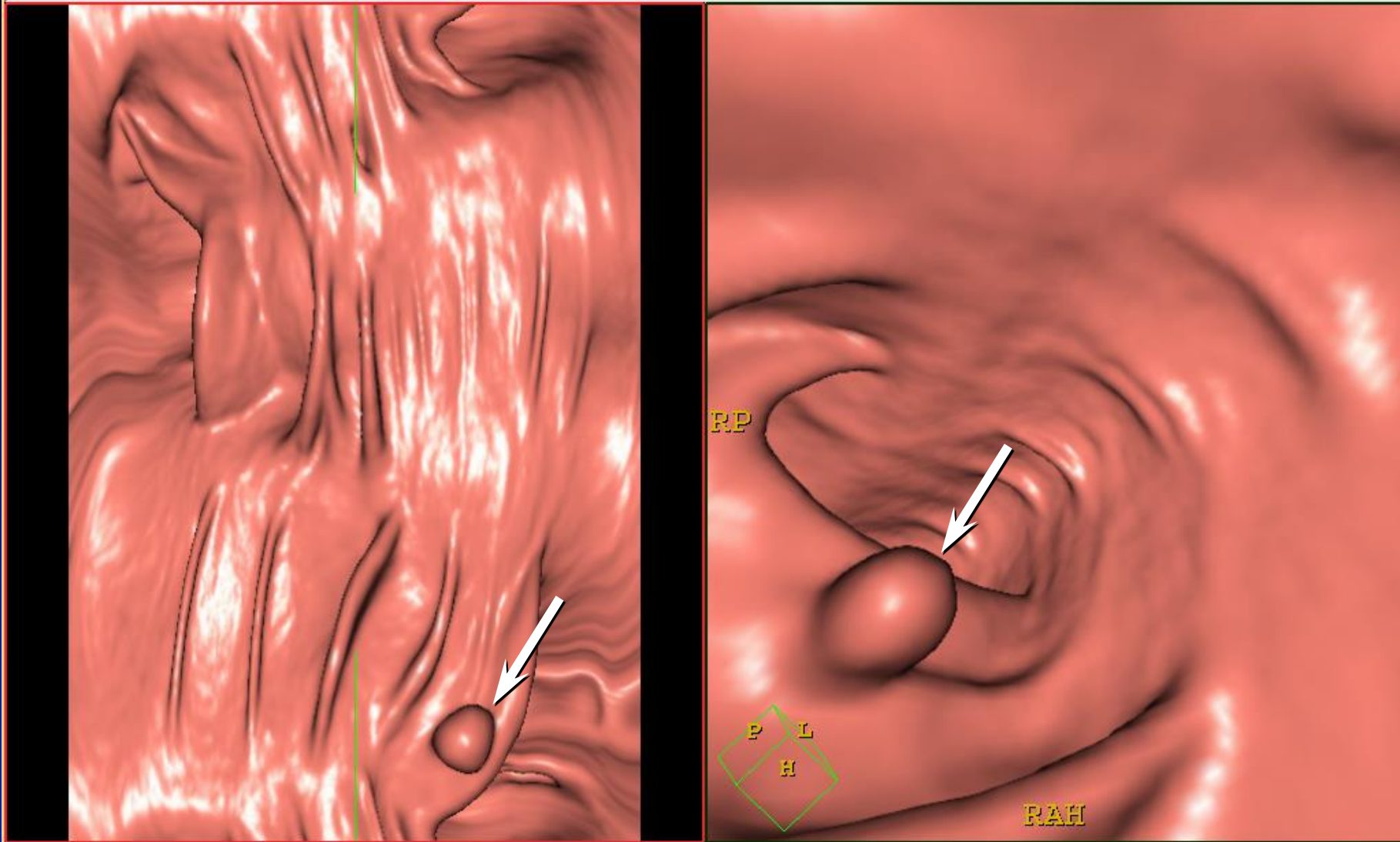
Courtesy: GE Medical Systems

Perspective Filet View



Courtesy of:
Philips Medical Systems

Perspective Filet View



Courtesy of: Philips Medical Systems

Detection of Suspect Lesions

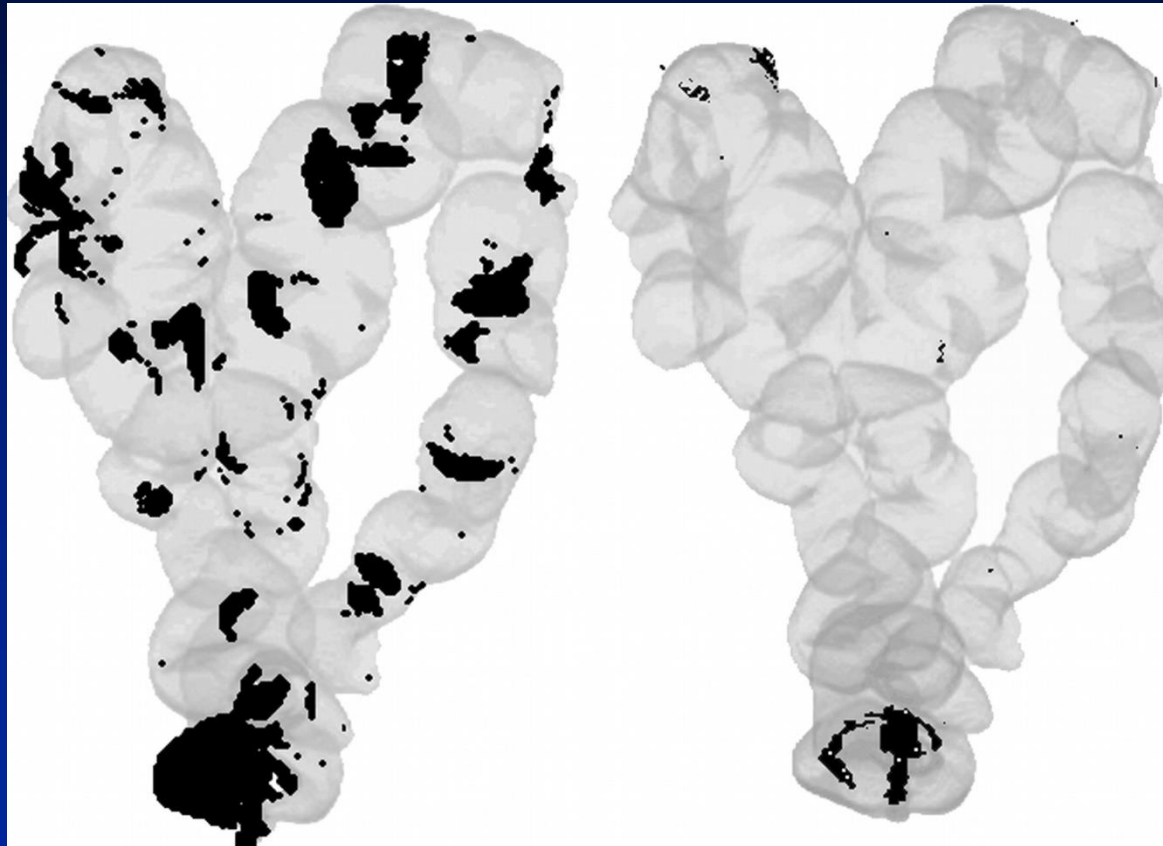


- ◆ Display method should allow:
 - Easy means for navigation through the colon
 - Display lesion on screen for sufficient detection time
 - **Visualization of entire colonic mucosa**
 - Perception of polyps from normal features of colon
 - Detection beneath obscuring fluid, tagged stool, etc.
 - Integration of CAD targets

Visualization of the Entire Colon



- ◆ New visualization methods try to eliminate need for “mucosal painting” by viewing entirety of colonic mucosa



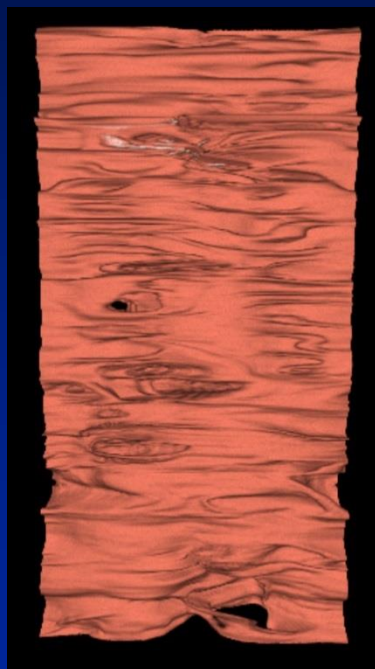
3D Fly-thru

Unfolded Cube

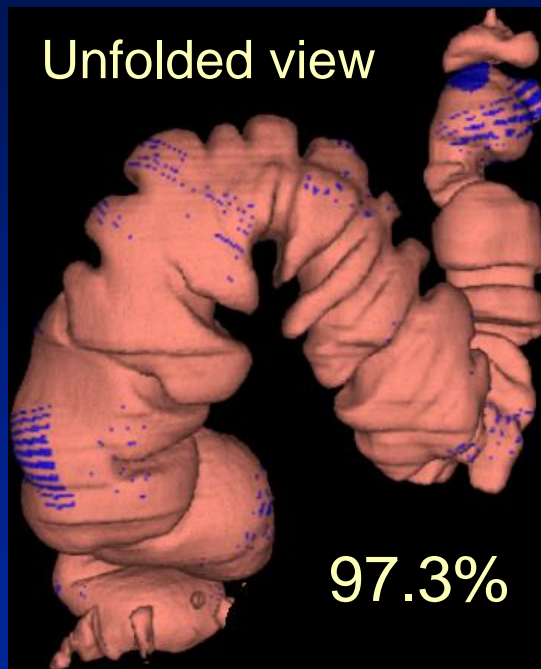
Visualization of the Entire Colon



- ◆ New visualization methods try to eliminate need for “mucosal painting” by viewing entirety of colonic mucosa



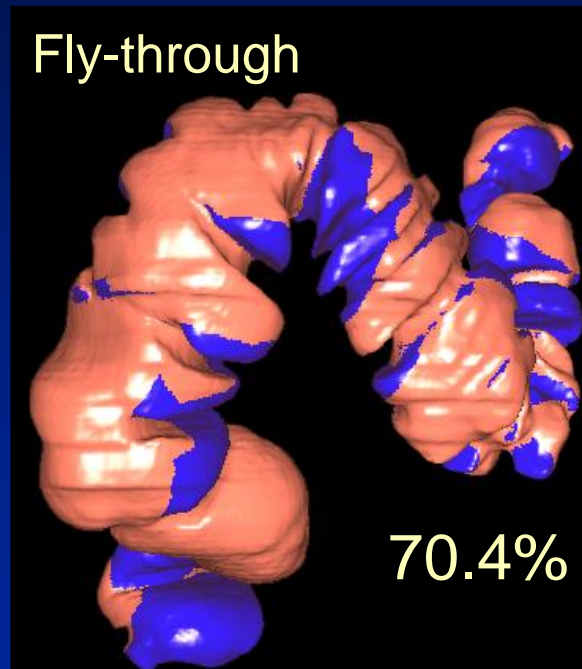
Unfolded view



97.3%

Flattened View

Fly-through



70.4%

3D Fly-thru

Detection of Suspect Lesions



- ◆ Display method should allow:
 - Visualization of entire colonic mucosa
 - Easy means for navigation through the colon
 - Display lesion on screen for sufficient detection time
 - Perception of polyps from normal features of colon
 - **Detection beneath obscuring fluid, tagged stool, etc.**
 - Integration of CAD targets



- ◆ Purpose of Reconstruction and Review
 - Detection of suspect lesions
 - Determines sensitivity -
Increase True Positives &
Reduce False Negatives
 - Characterization of detected lesions
 - Determines specificity -
Reduce false positives

Characterization of Lesions



- ◆ Display method should allow for rapid characterization
 - Morphology
 - Polyps don't have angular shapes (polyps are roughly hemispheric)
 - Stool can appear cubic or needle-like
 - Density
 - Polyps have soft tissue density (lipoma has fat density)
 - Stool can be very high or low density
 - Mobility
 - Stool shows positional change from prone to supine
 - BUT not all stool moves and not all that moves is stool

Lesion Characterization

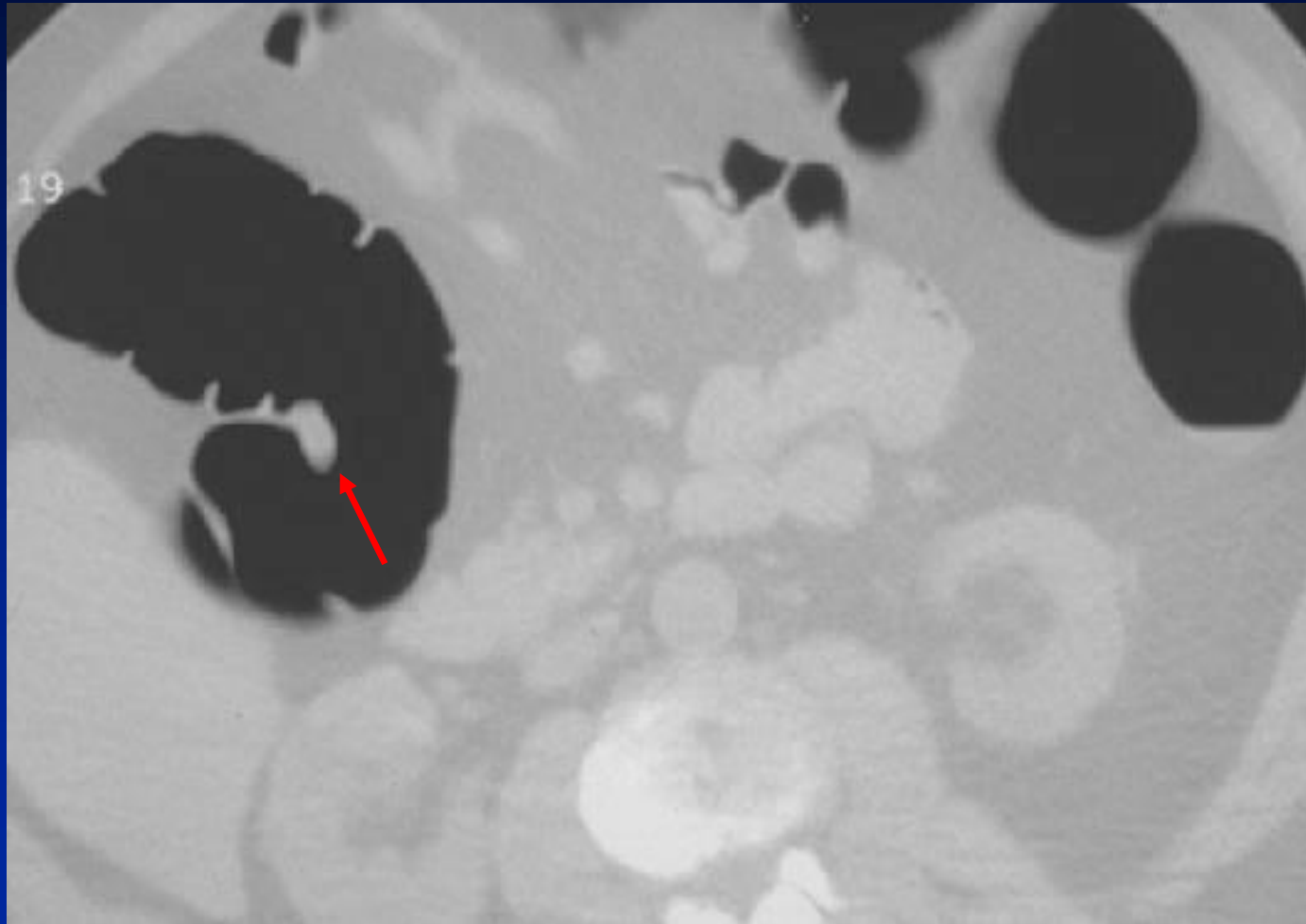


- ◆ Morphology
 - Polyps don't have angular shapes (polyps are roughly hemispheric)
 - Stool can appear cubic or needle-like
- ◆ Density
 - Polyps have soft tissue density (lipoma has fat density)
 - Stool can be very high or low density
- ◆ Mobility
 - Stool shows positional change from prone to supine
 - BUT not all stool moves and not all that moves is stool

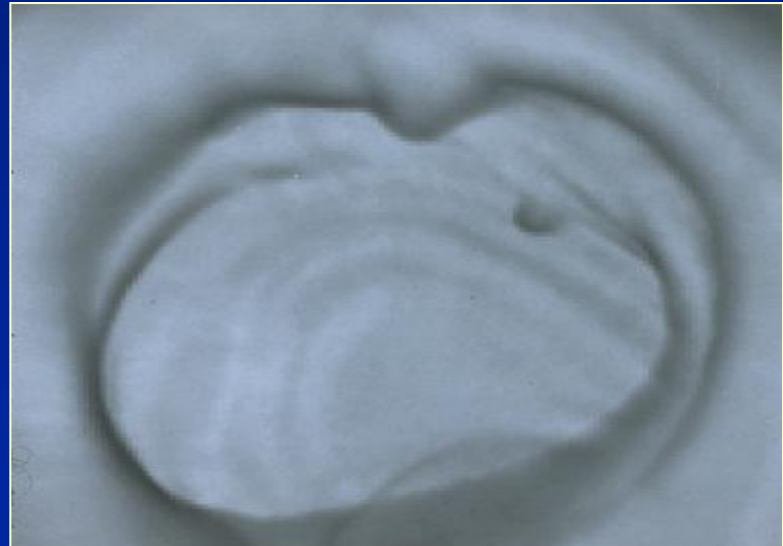
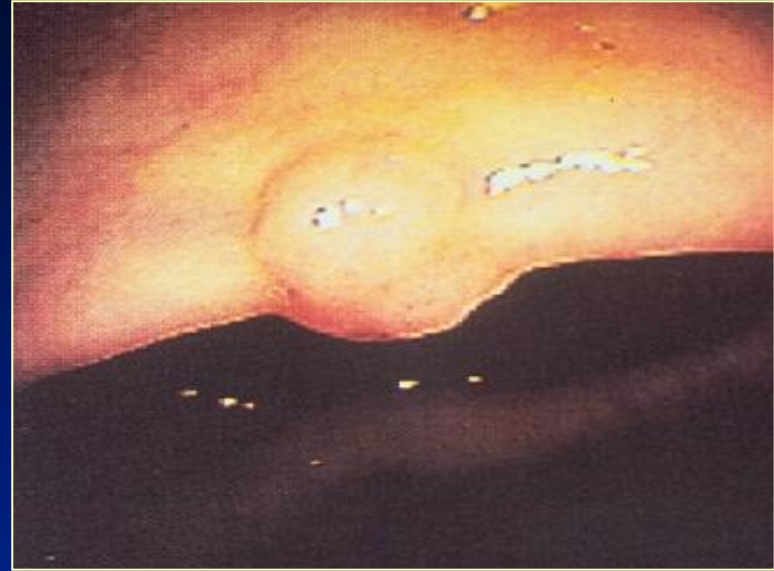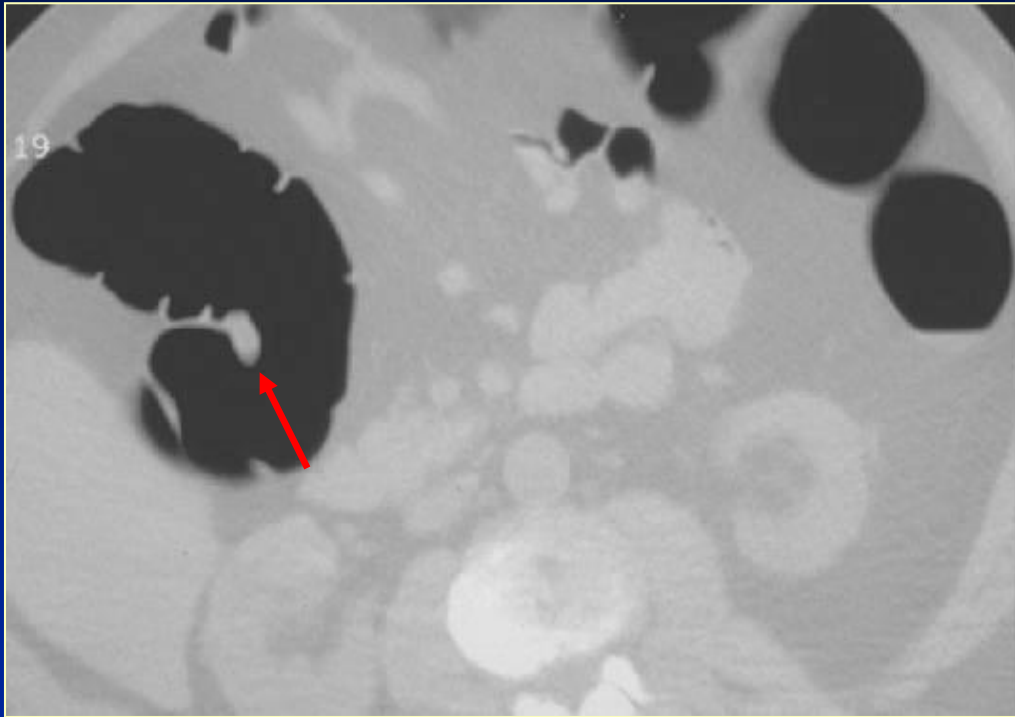


- ◆ Main weakness of 2D review:
 - Does not allow for full demonstration of lesion morphology
 - Complex lesion shapes can be difficult to interpret
 - Detection of small lesions may be limited

Complex Fold or Polyp ?



Polyp on Fold



Lesion Characterization



◆ Morphology

- Polyps don't have angular shapes (polyps are roughly hemispheric)
- Stool can appear cubic or needle-like

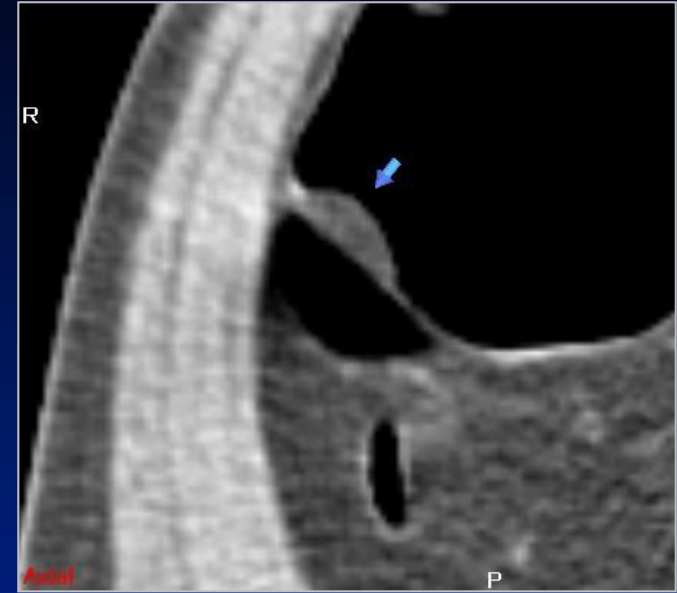
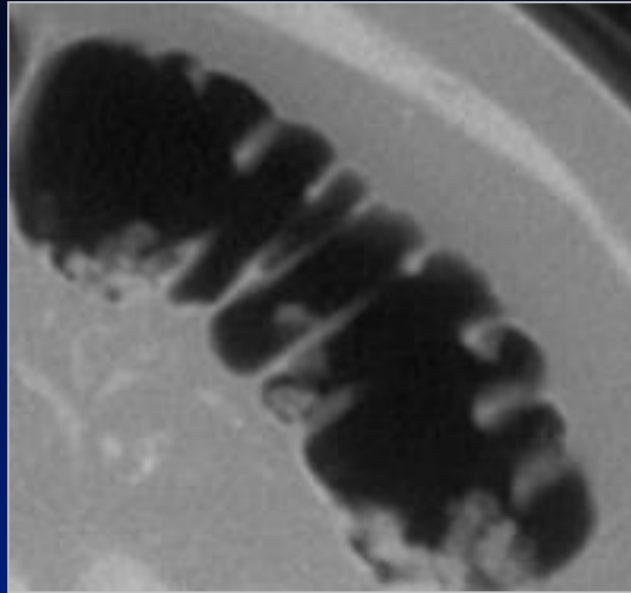
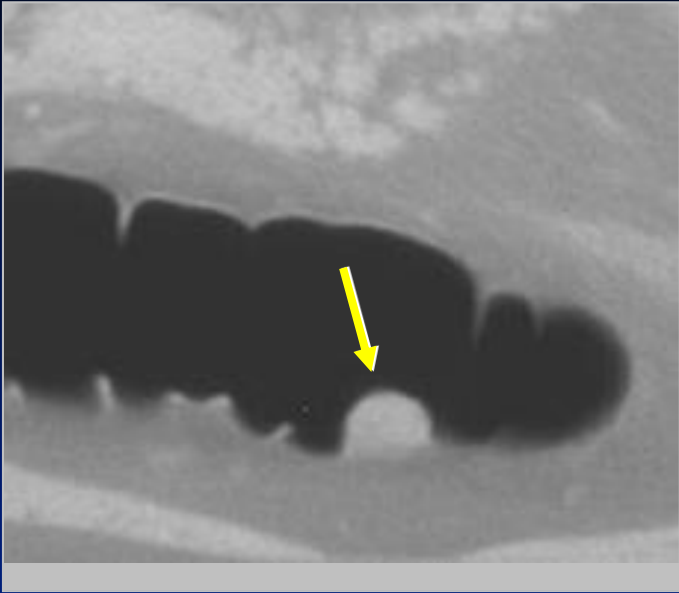
◆ Density

- Polyps have soft tissue density (lipoma - fat density)
- Stool can be very high or low density

◆ Mobility

- Stool shows positional change from prone to supine
- BUT not all stool moves and not all that moves is stool

Density – Soft Tissue



Polyp
Soft Tissue

Stool
Gas Density
within lesion

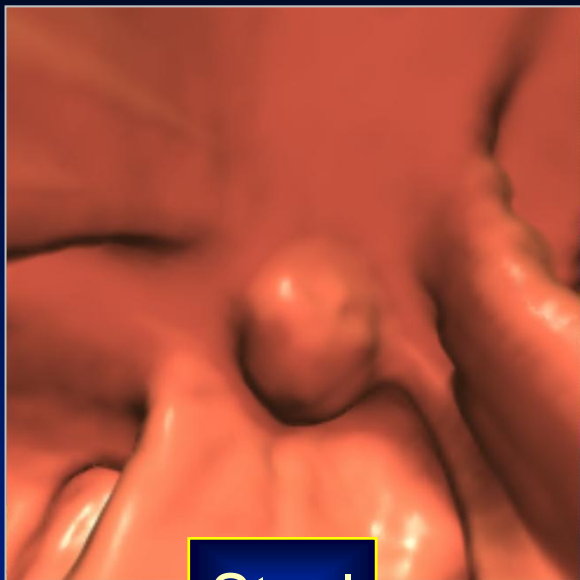
Lipoma
Fat Density

Problems with Primary 3D Fly-through

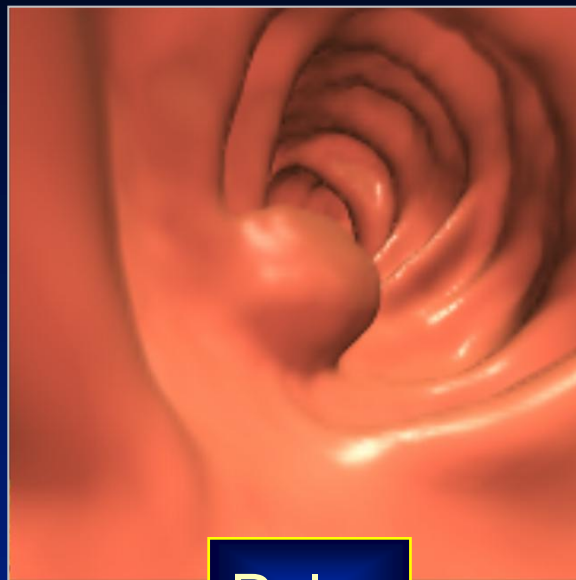


- ◆ Main difficulty with primary 3D interpretation is the “inability” to characterize lesion density without 2D review
 - Difficult to differentiate polyp from stool
- ◆ Primary 3D with 2D problem-solving
 - Detection on 3D review with 2D images used for characterization

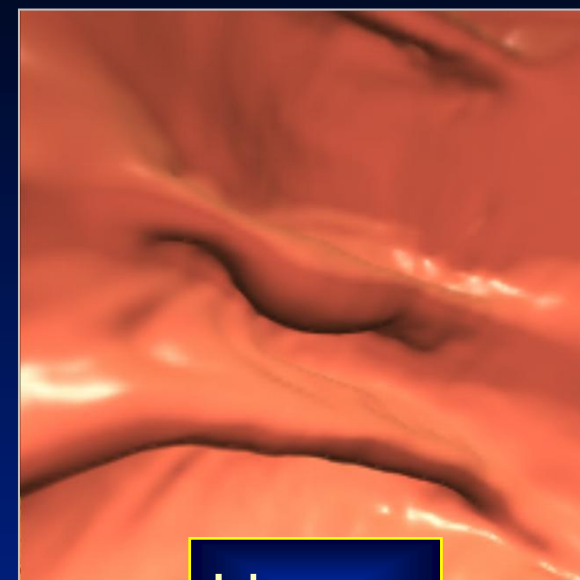
Characterization Difficulty - Density



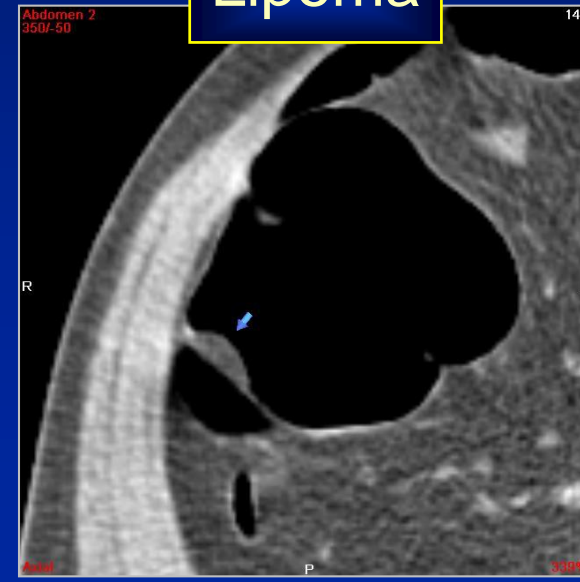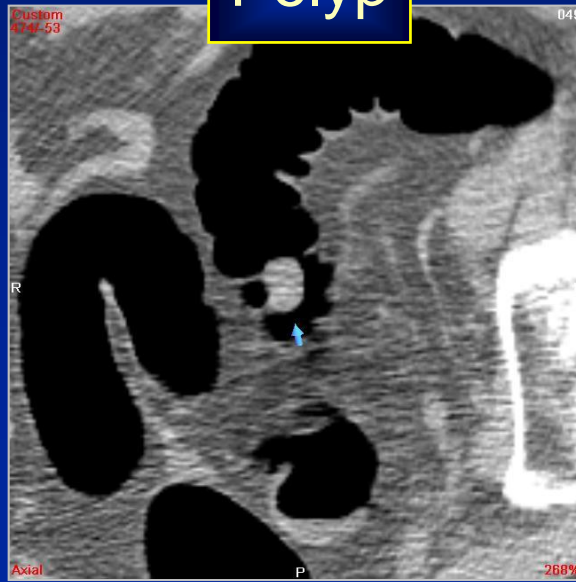
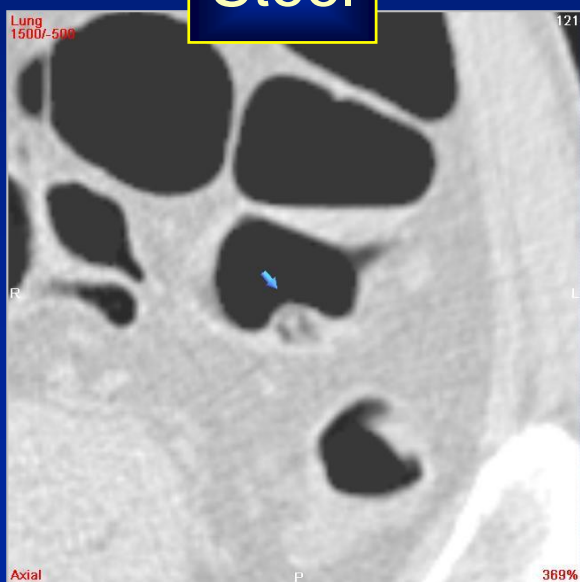
Stool



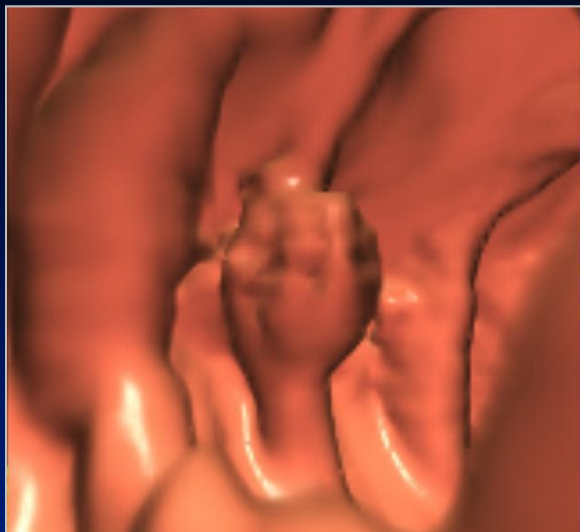
Polyp



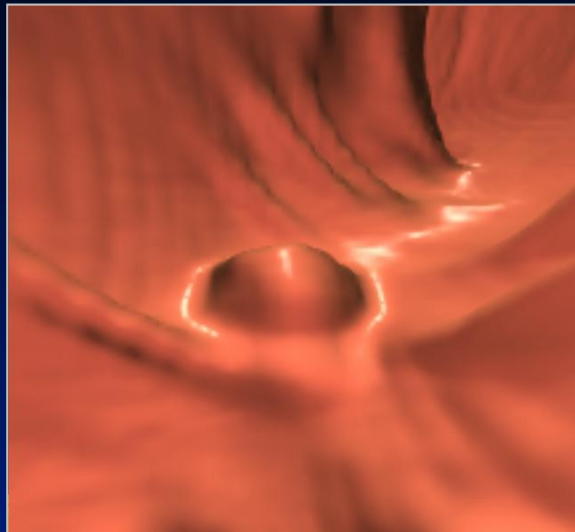
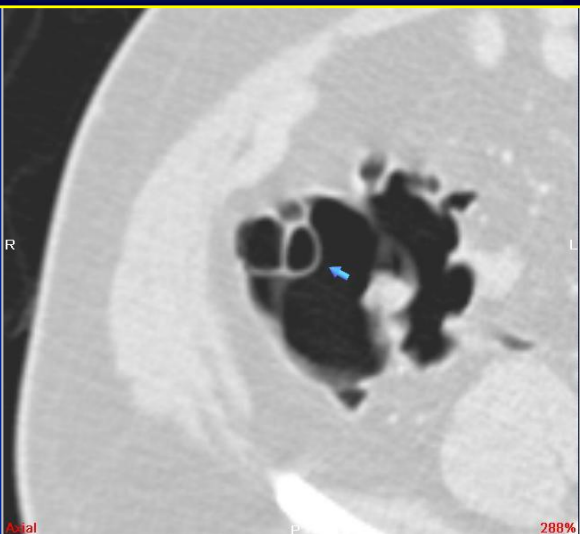
Lipoma



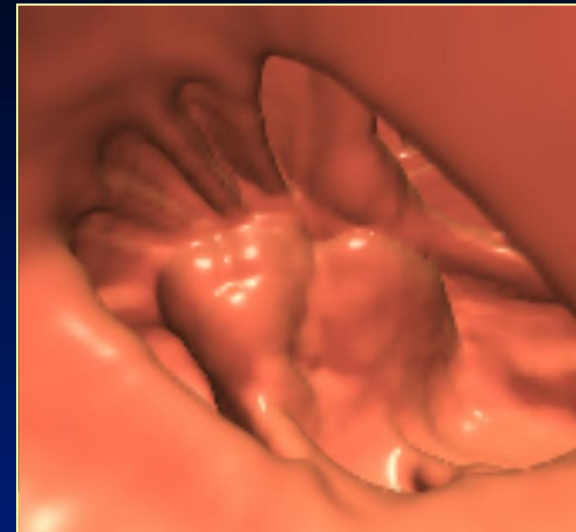
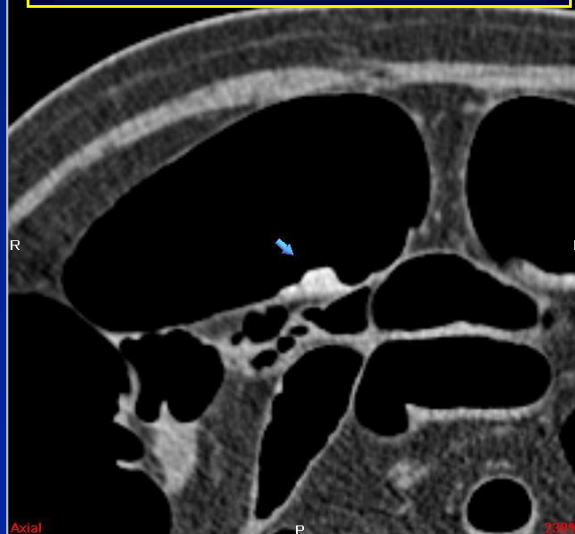
Characterization Difficulty - Density



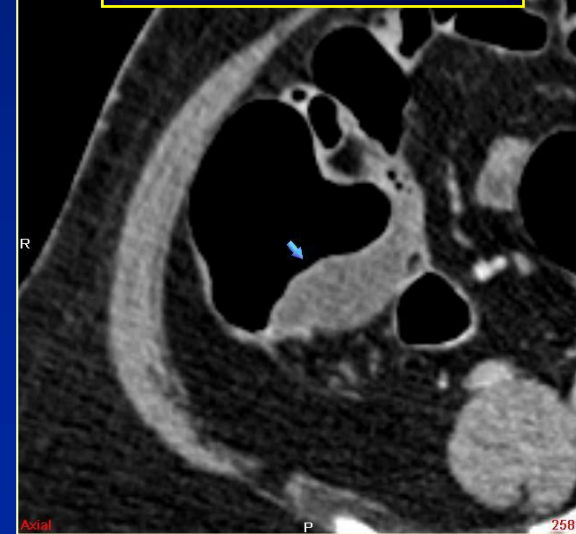
Pneumatosis Cystoides



Barium Tagged Stool



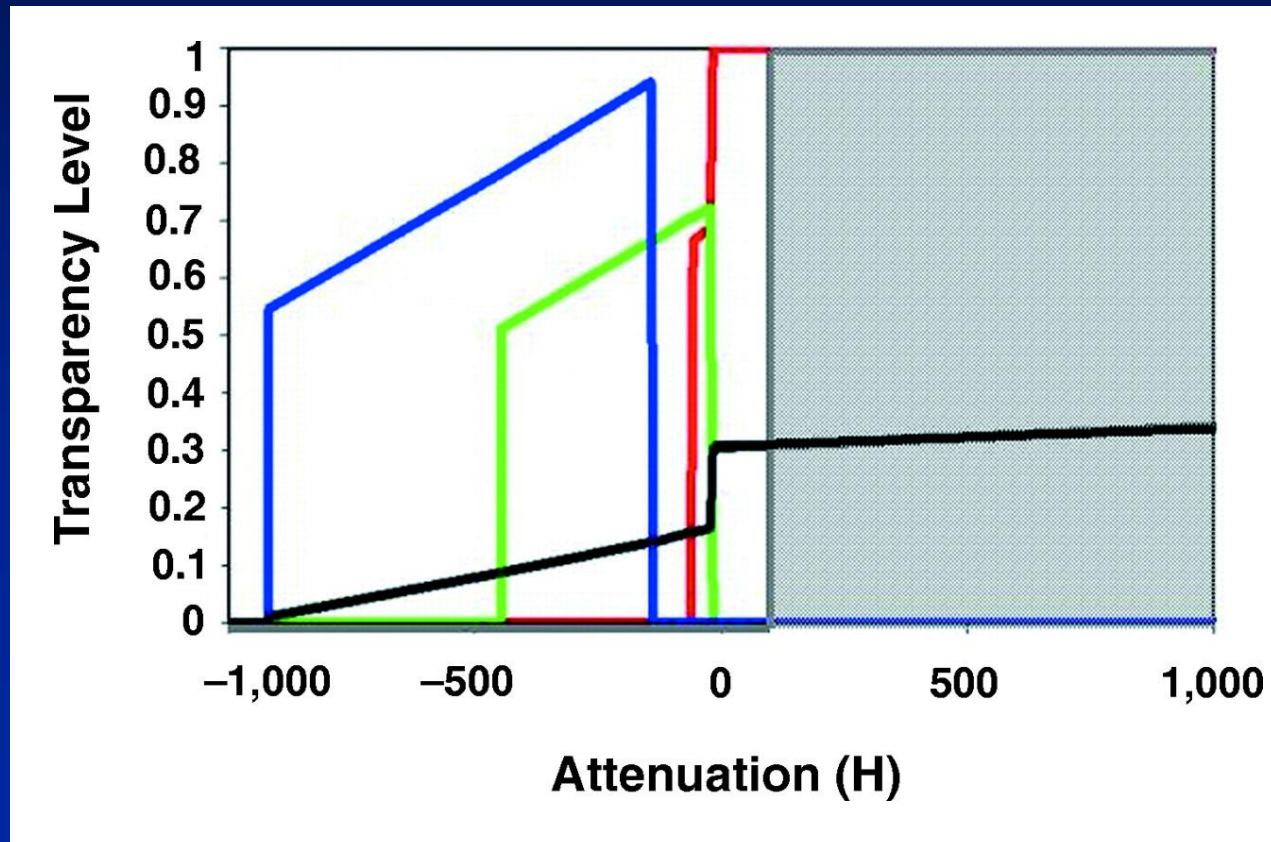
Cecal Mucocele



Translucency

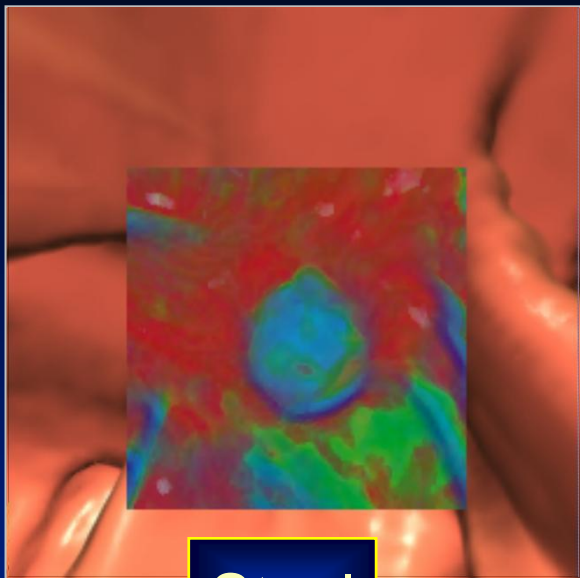


- ◆ Application of alternate color-opacity histogram to the volume-rendered image, allows for simultaneous display of density during 3D review




From: Pickhardt *AJR*
2004; 183:429-436

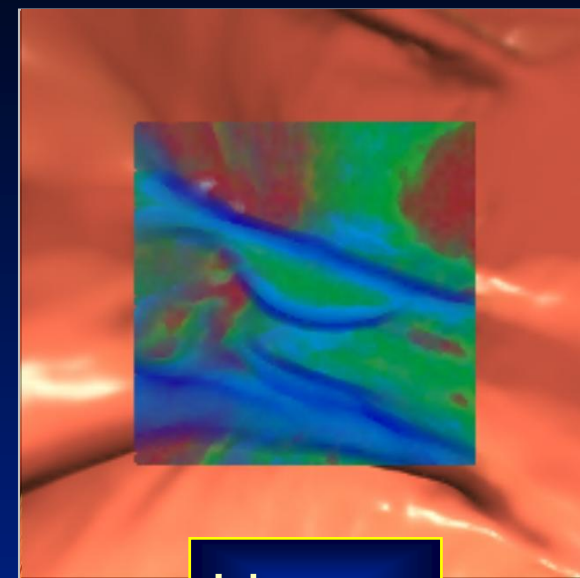
Characterization Difficulty - Density



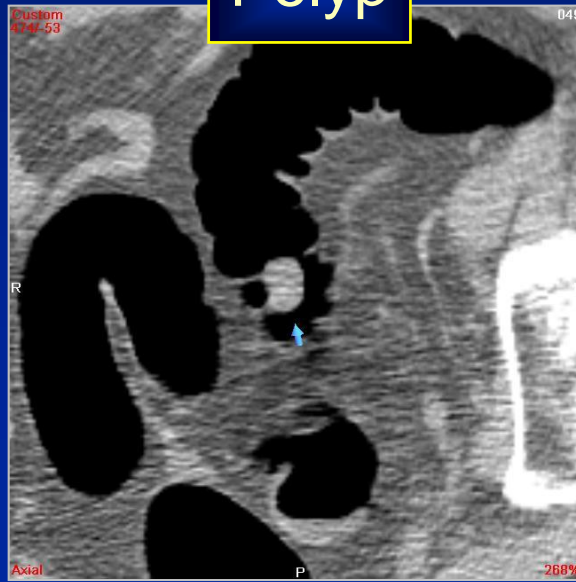
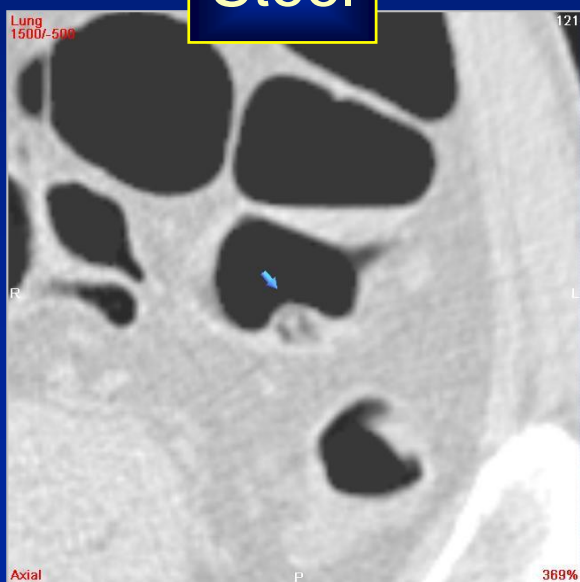
Stool



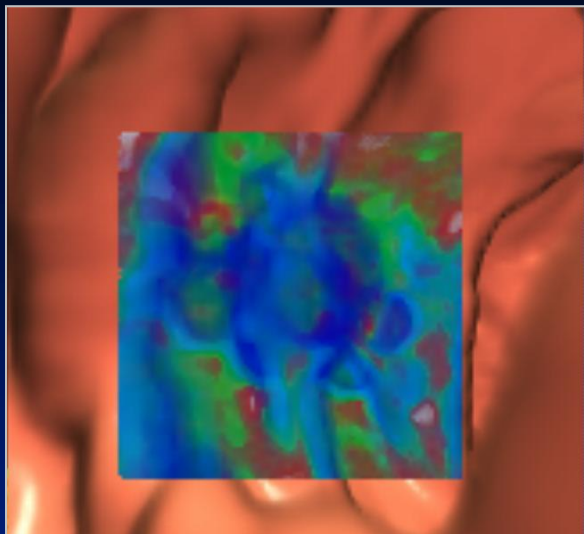
Polyp



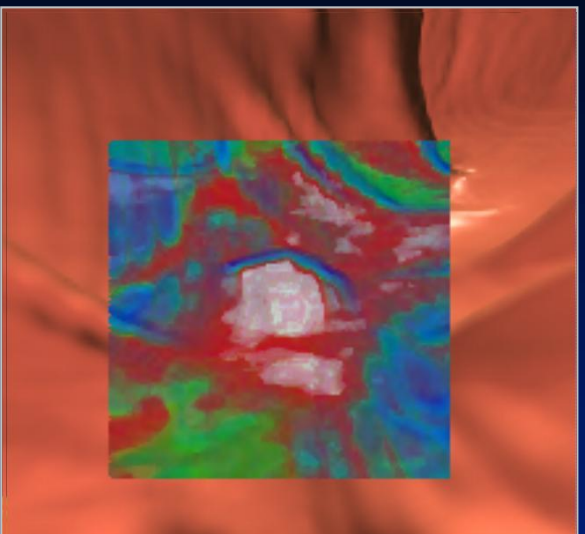
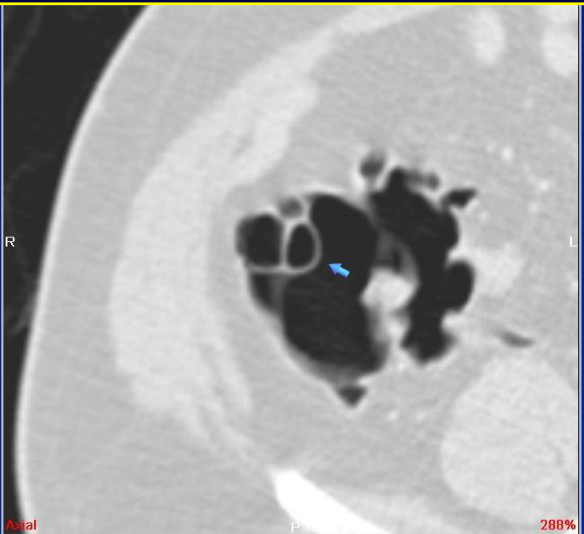
Lipoma



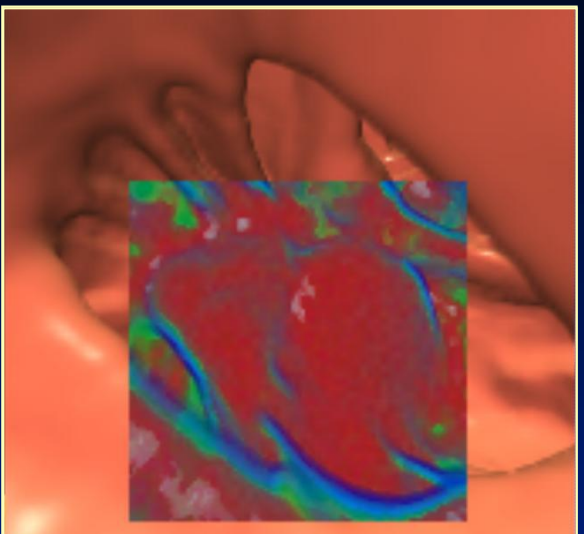
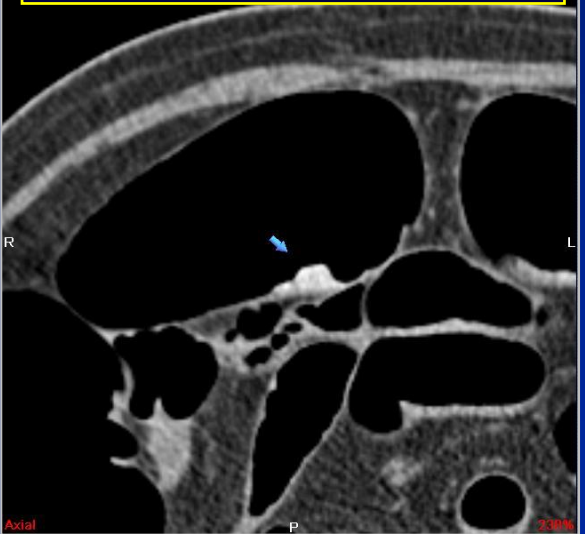
Characterization Difficulty - Density



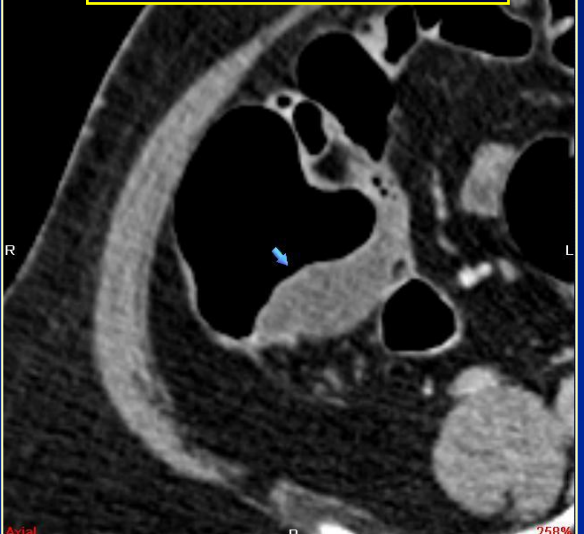
Pneumatosis Cystoides




Barium Tagged Stool



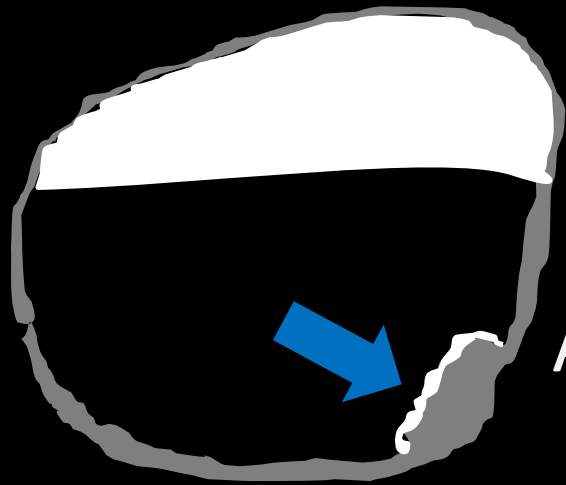
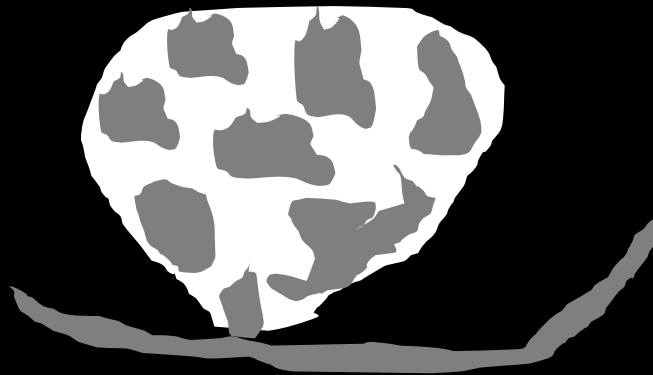
Cecal Mucocele



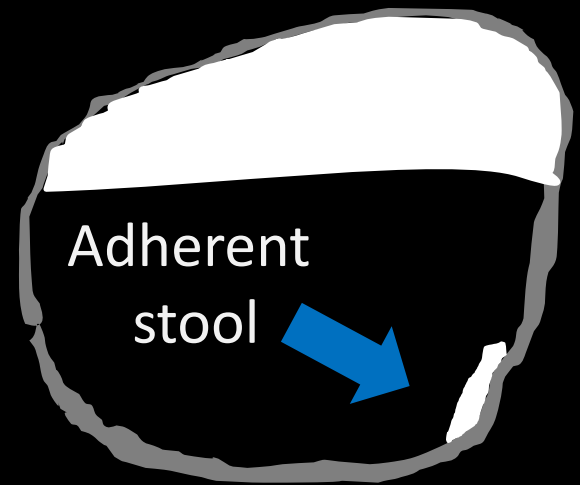
Villous Polyp



Fecal Material



Anti-dependant tagging agent marking flat lesion



Lesion Characterization



◆ Density

- Polyps have soft tissue density (lipoma has fat density)
- Stool can be very high or low density

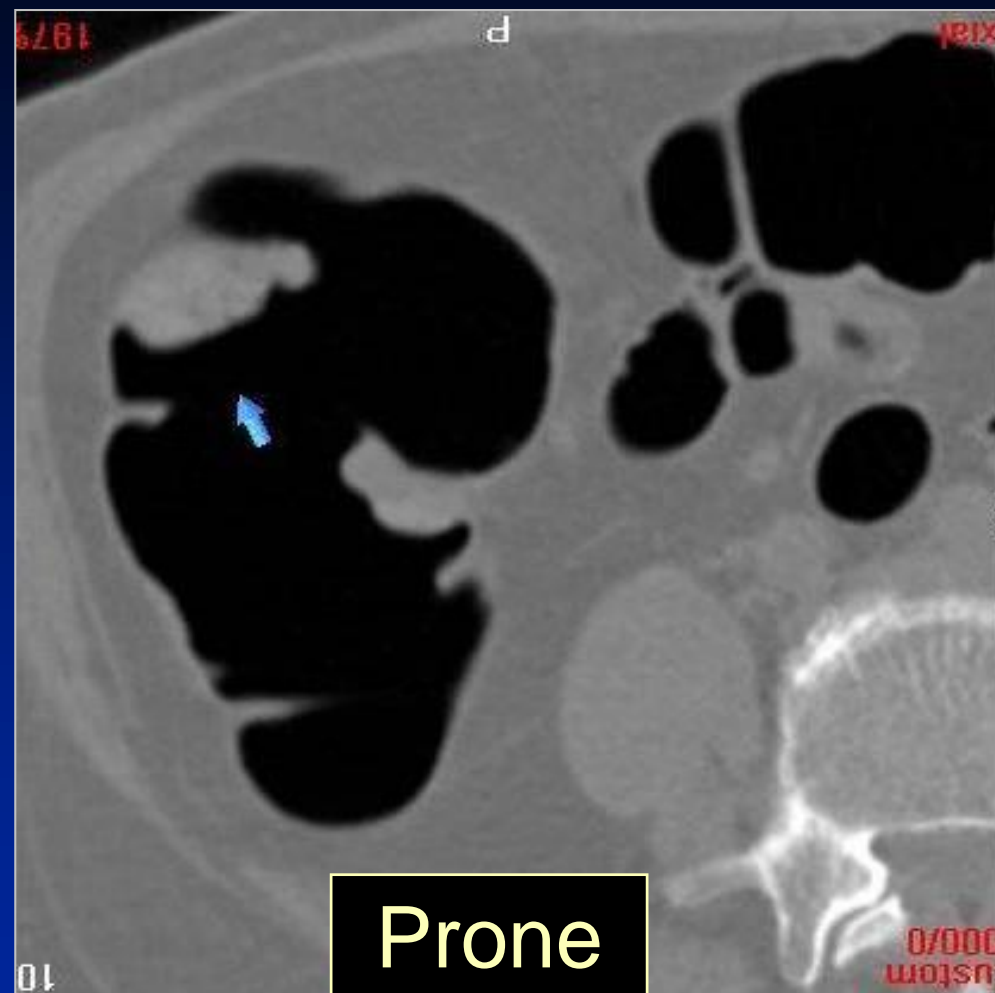
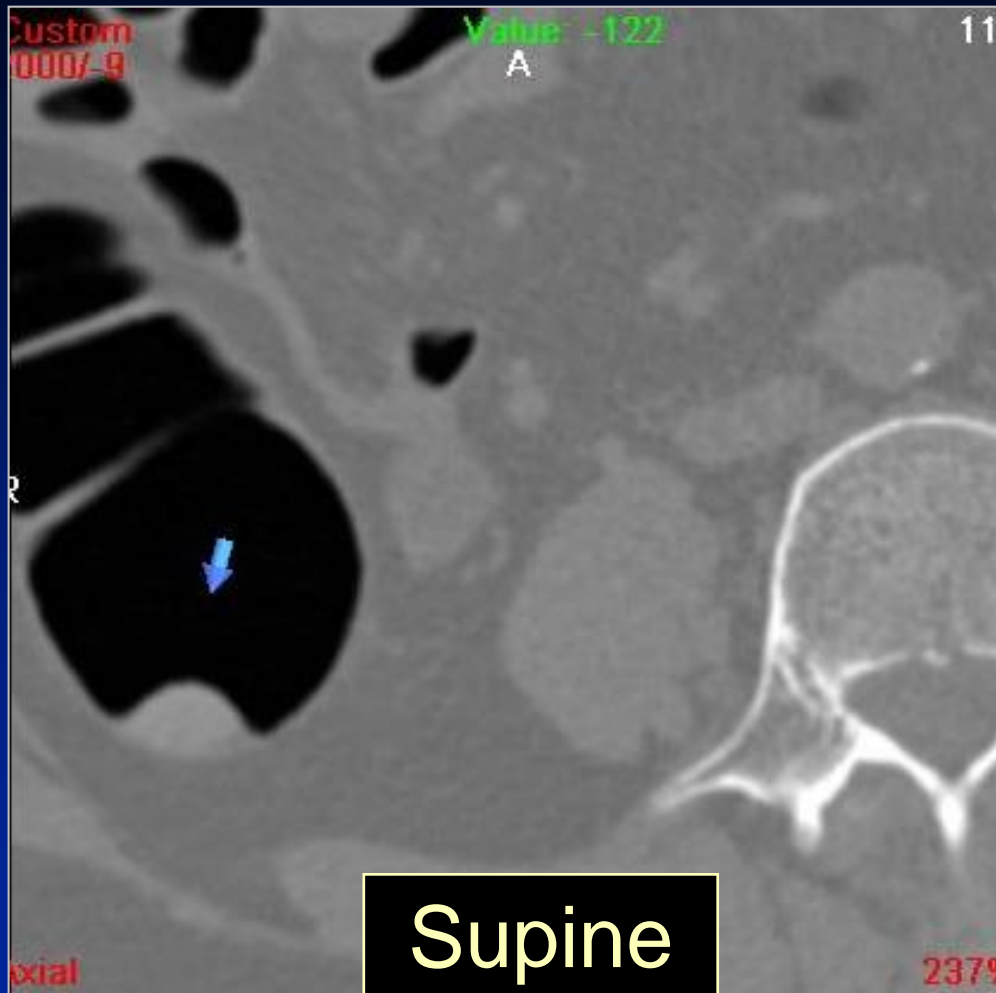
◆ Morphology

- Polyps don't have angular shapes (polyps are roughly hemispheric)
- Stool can appear cubic or needle-like

◆ Mobility

- Stool shows positional change from prone to supine
- BUT not all stool moves and not all that moves is stool
- Polyps maintain position between prone and supine

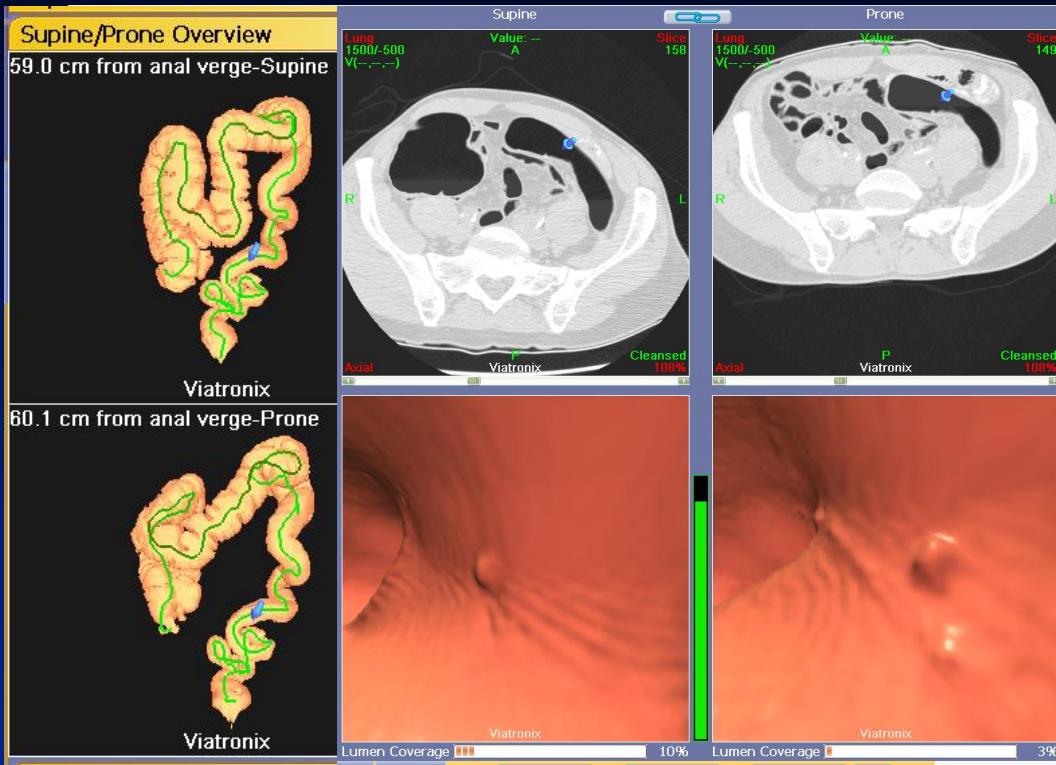
Mobility - Stool



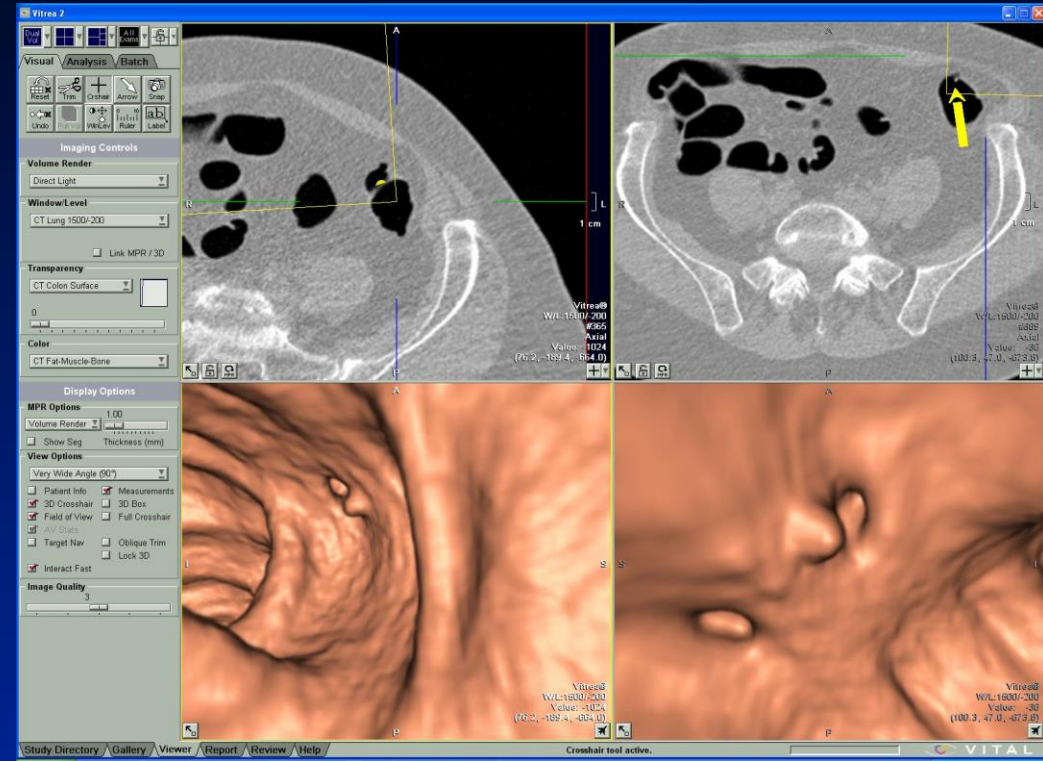


- ◆ Need to confirm position between prone and supine
 - Positional registration
 - Rotational registration

Positional Registration



Courtesy of Viatronix

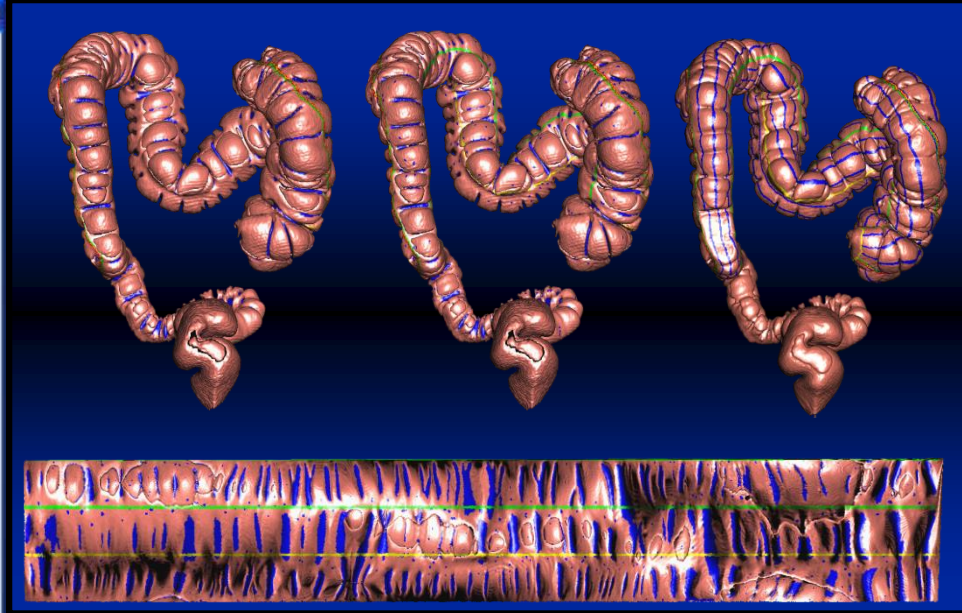
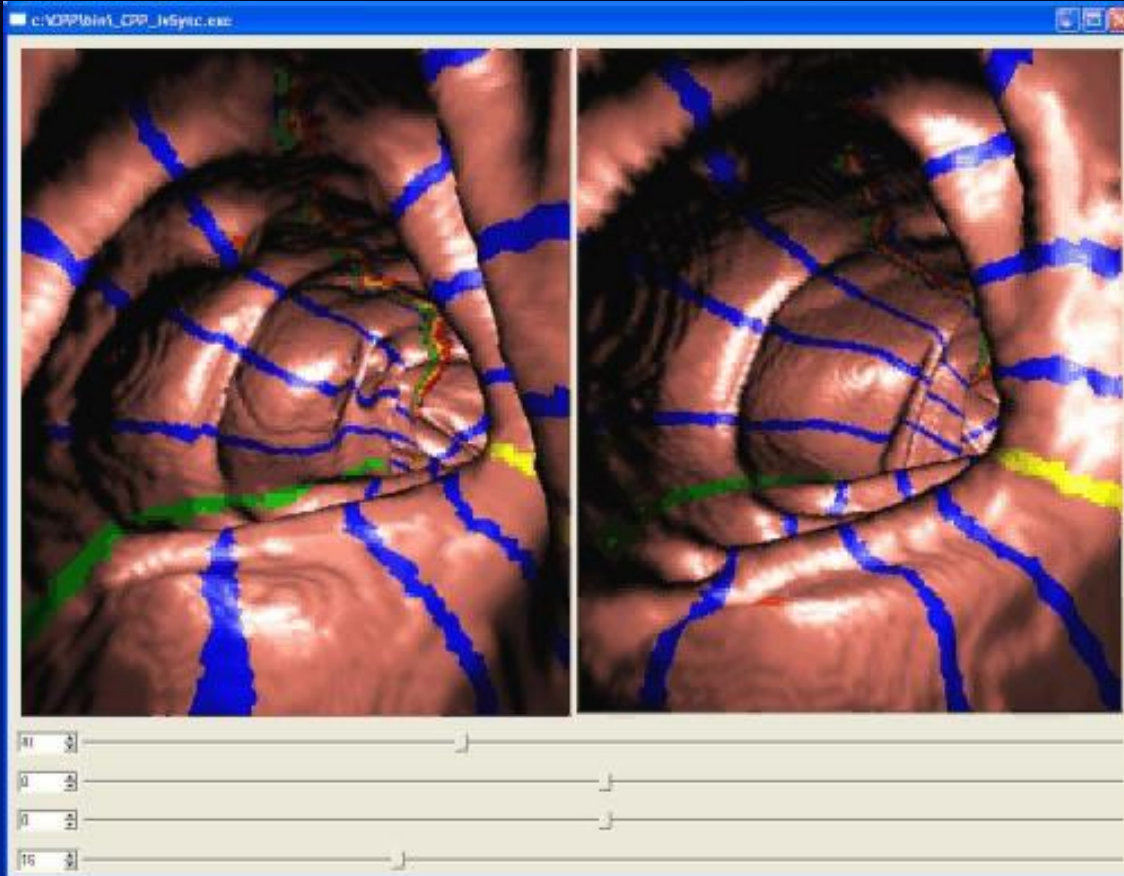


Courtesy of Vital Images

Works in Progress
Pending FDA Approval

Uses a combination of length and user defined points along centerline to create two registered datasets

Rotational Registration



Courtesy of Dr. Ron Summers
Virtual Endoscopy & CAD Lab
NIH Clinical Center

Uses tenia coli to create coordinate system to register datasets

Conclusion



- ◆ Accurate interpretation of Virtual Colonoscopy is based on the ability to **detect** and **characterize** lesions.
- ◆ New display methods will continue to change and improve our ability to accomplish both of these tasks in a reasonable amount of time



