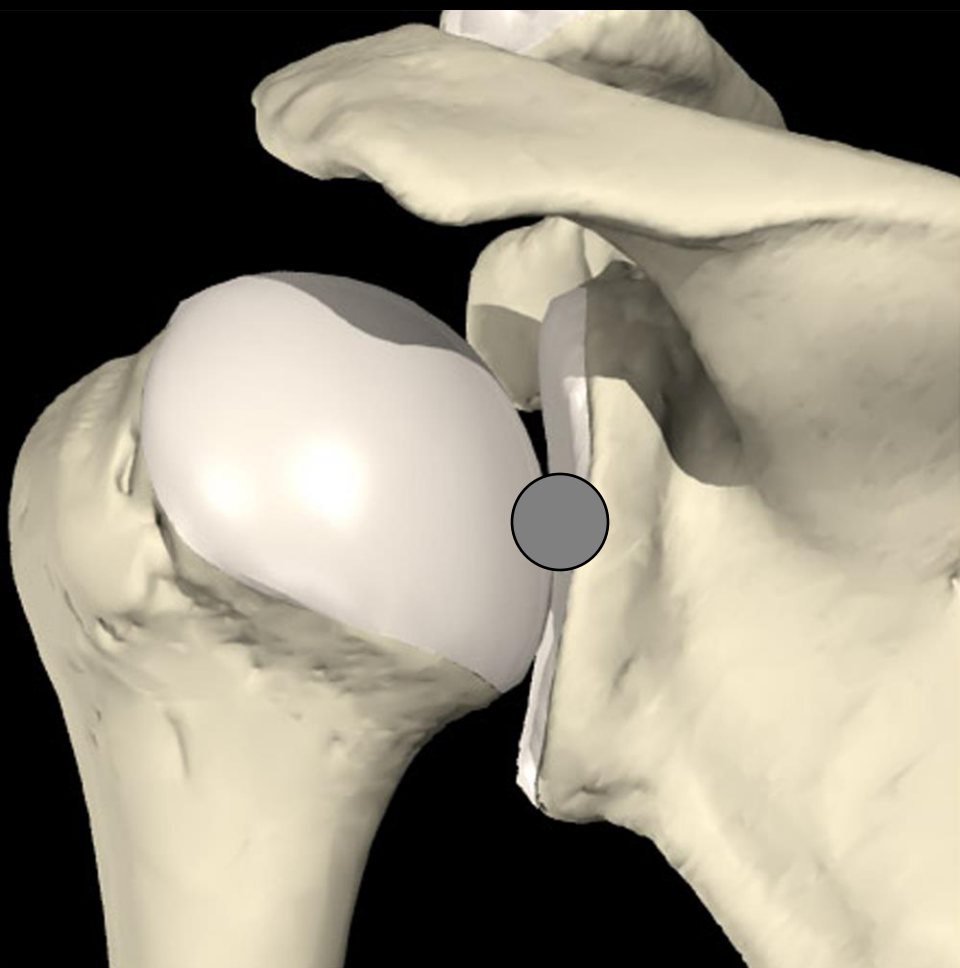
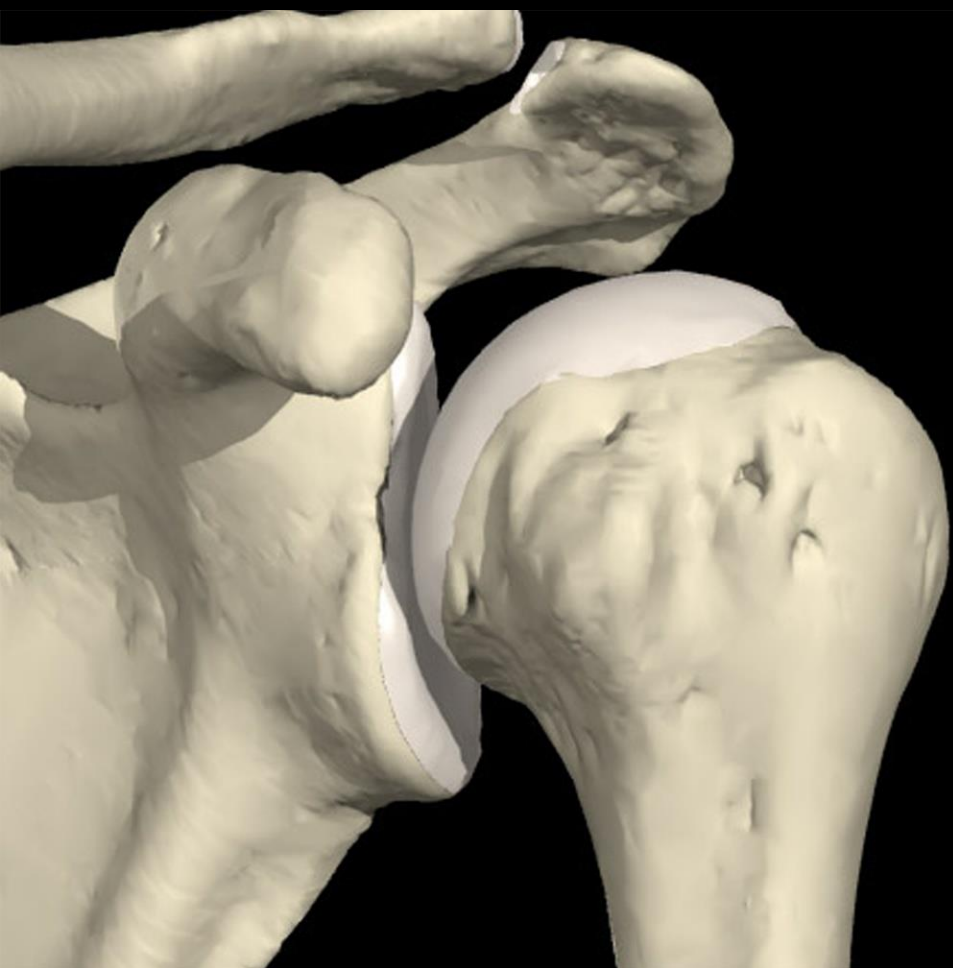

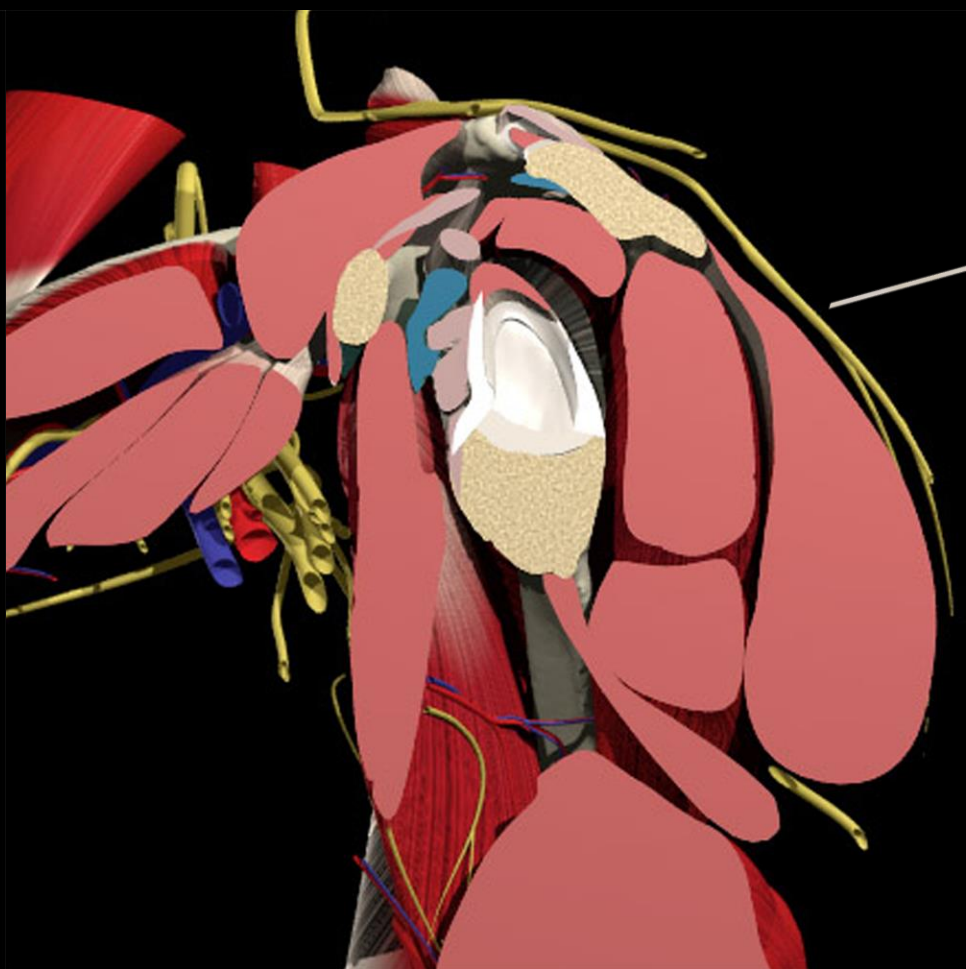
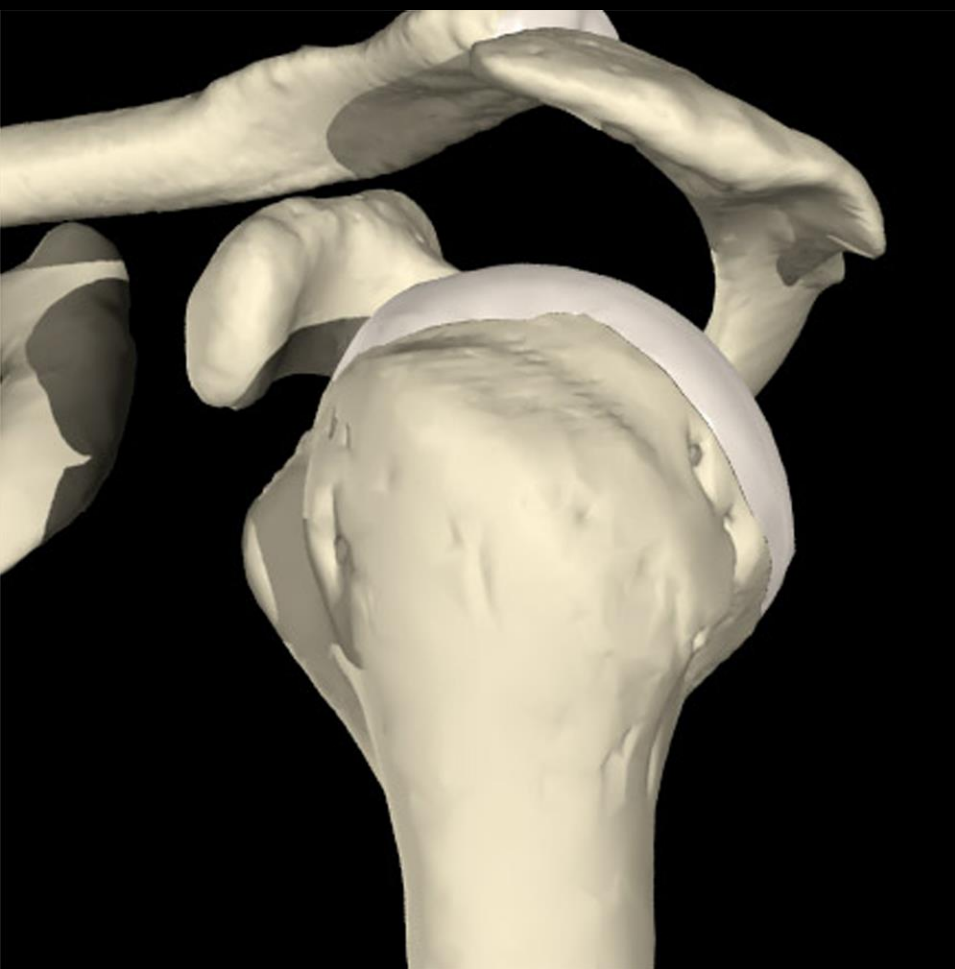ARTHROSCOPY TECHNIQUE SHOULDER

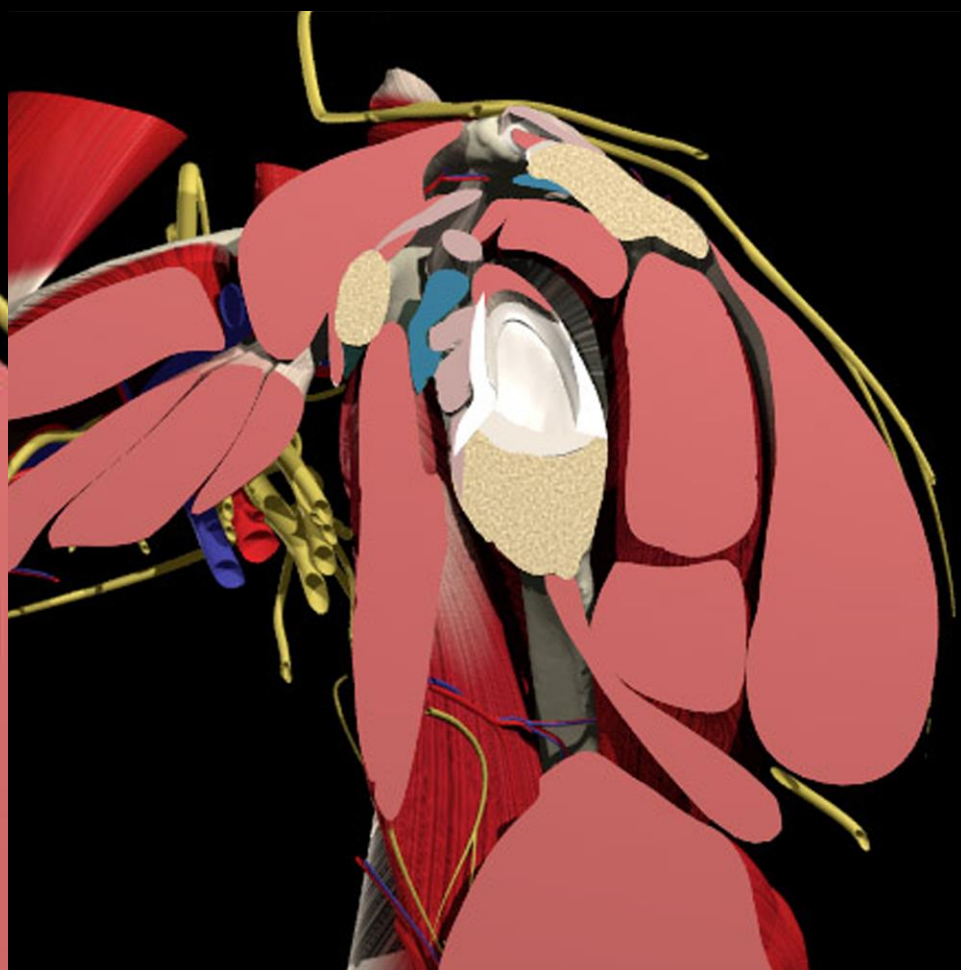
MARK D. MURPHEY, MD, FACR

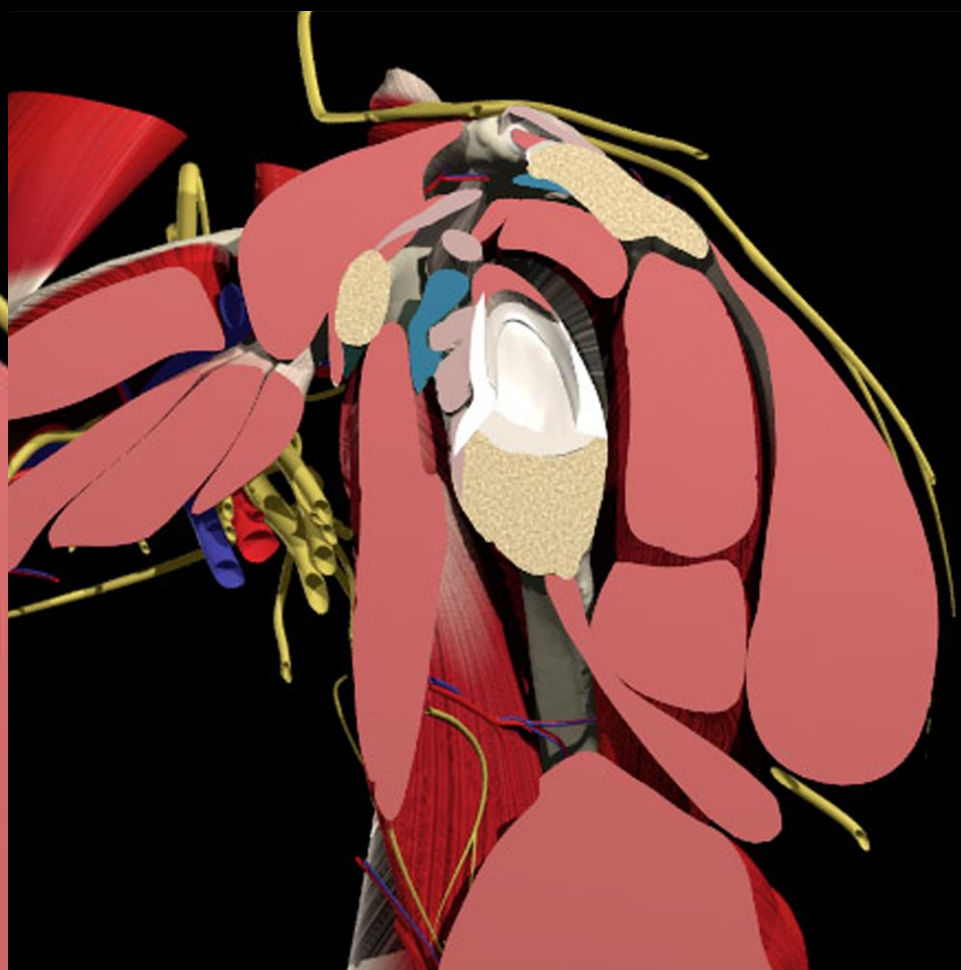
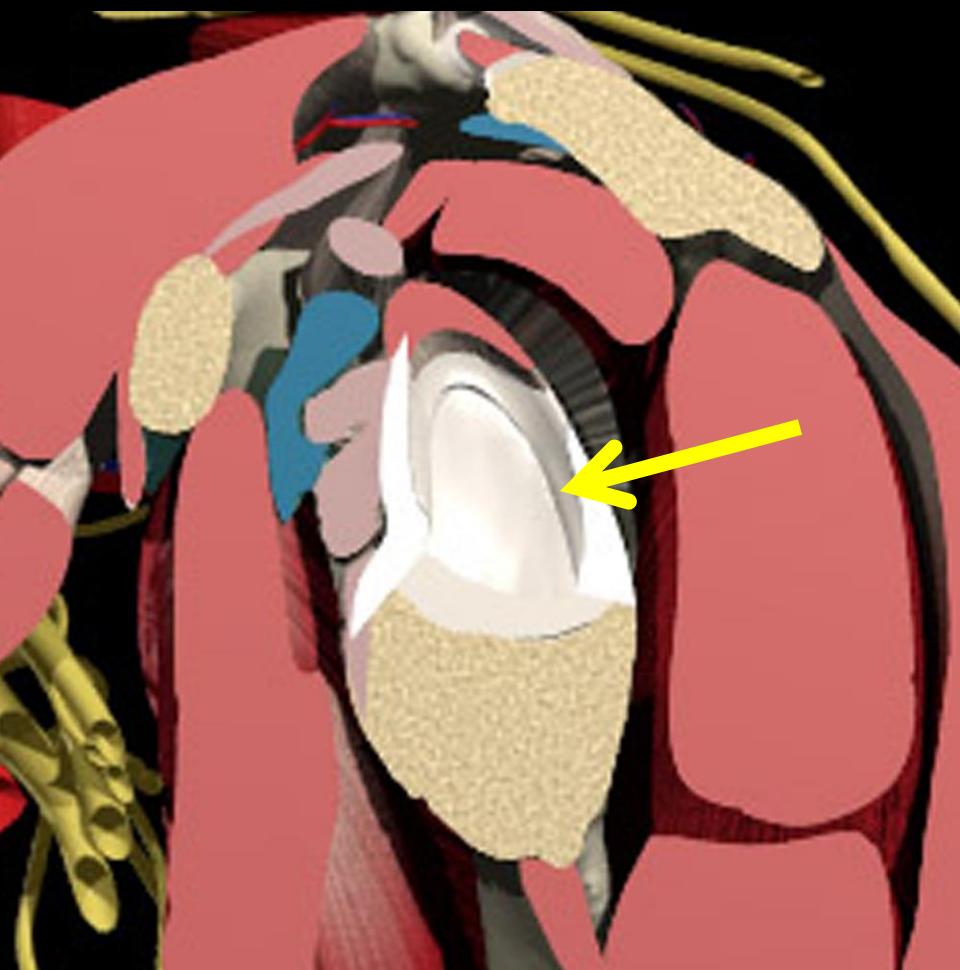
Physician-in-Chief, AIRP

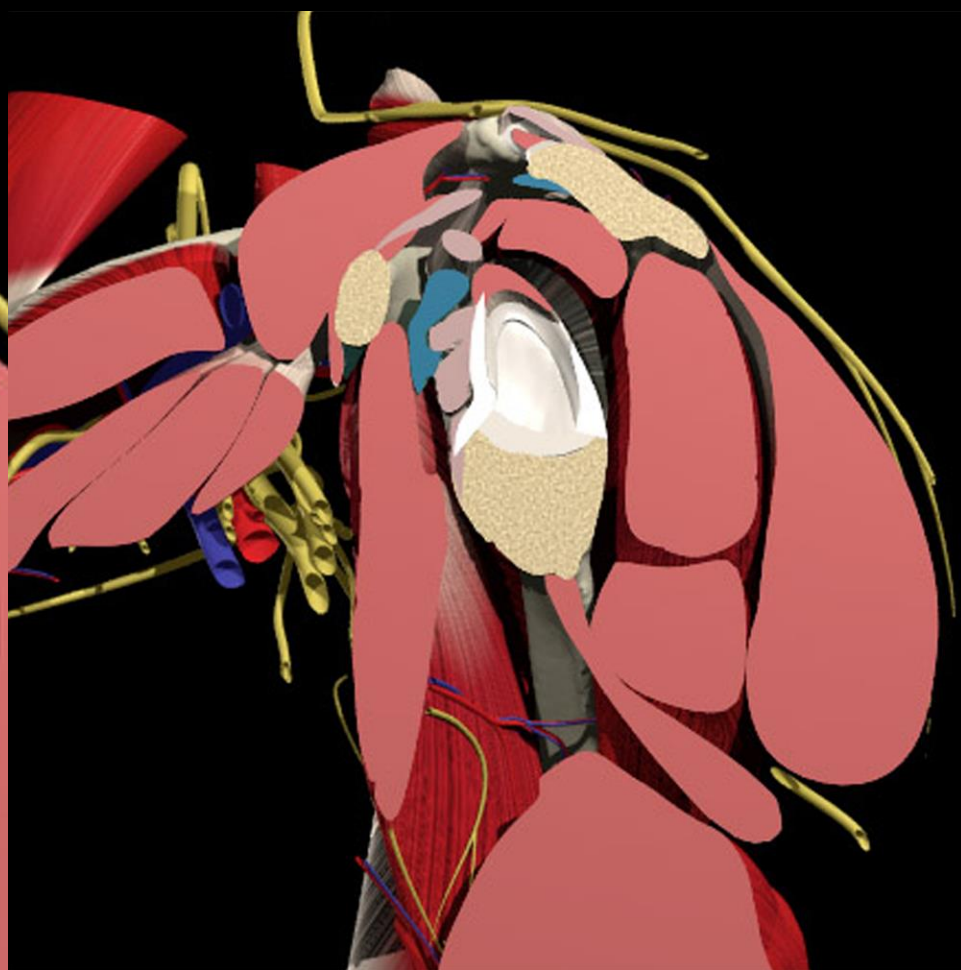
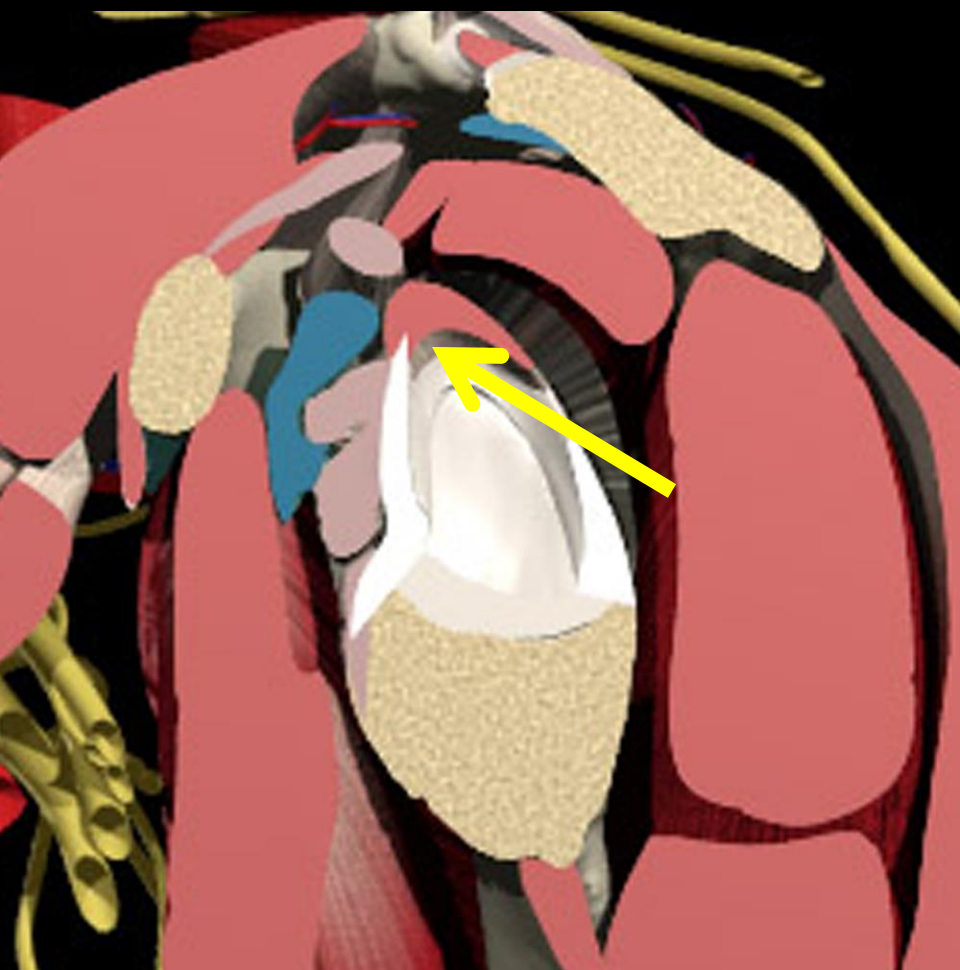
CHIEF, MUSCULOSKELETAL IMAGING

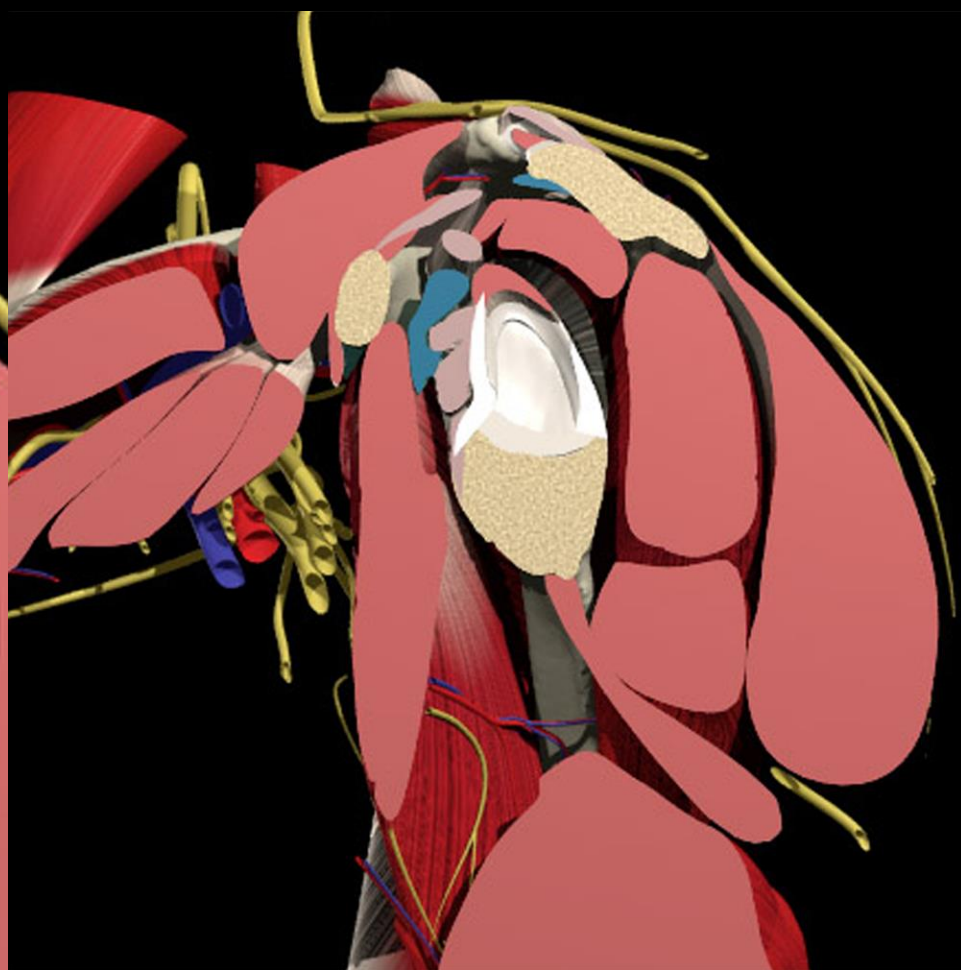
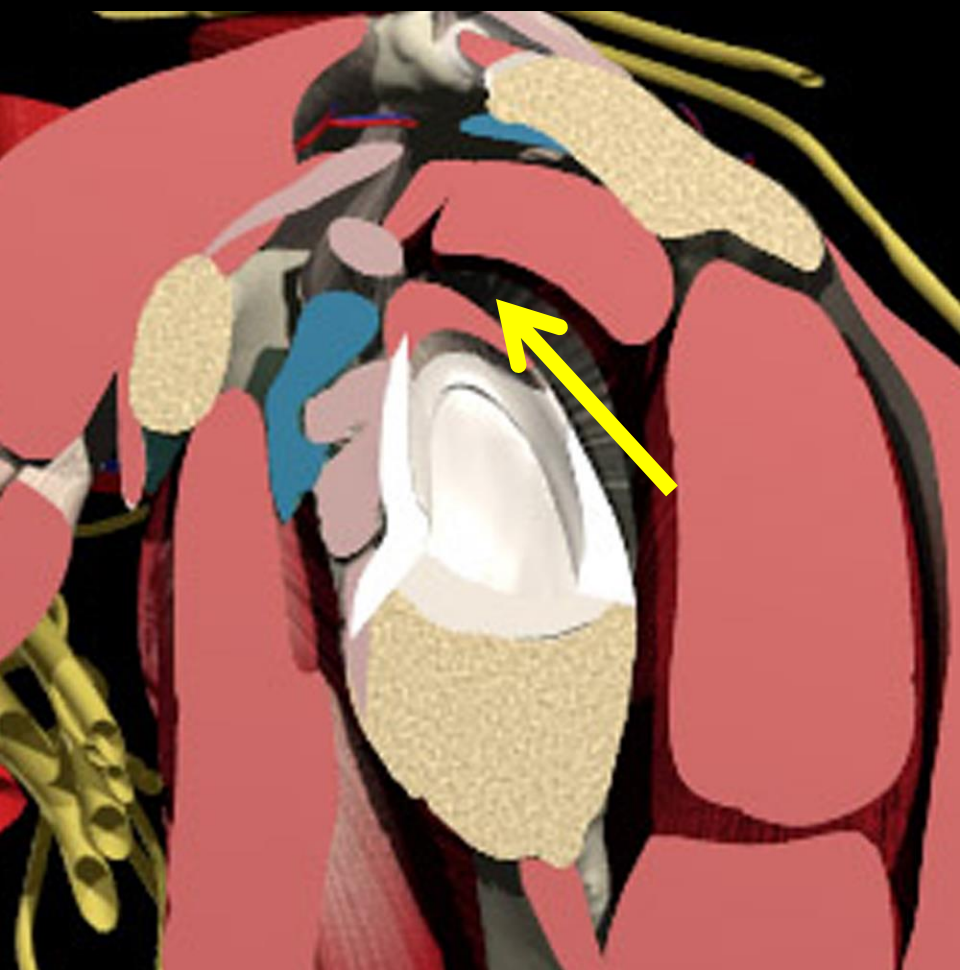

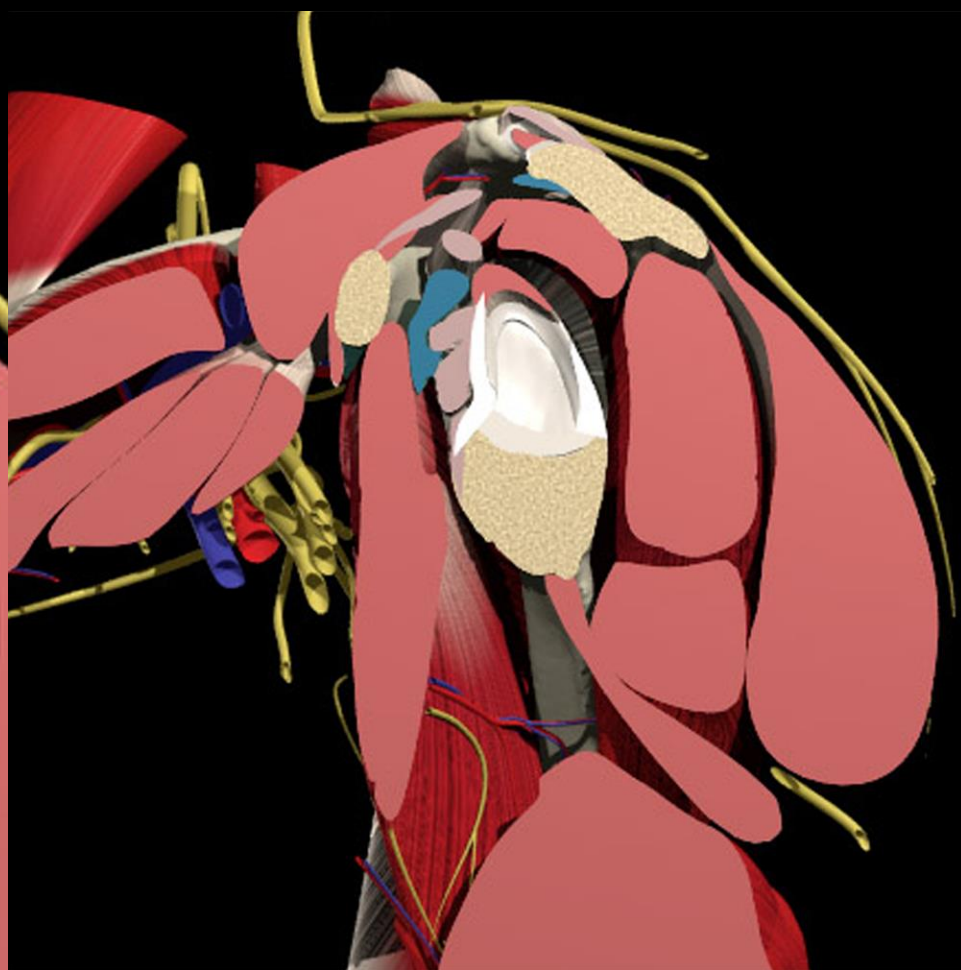

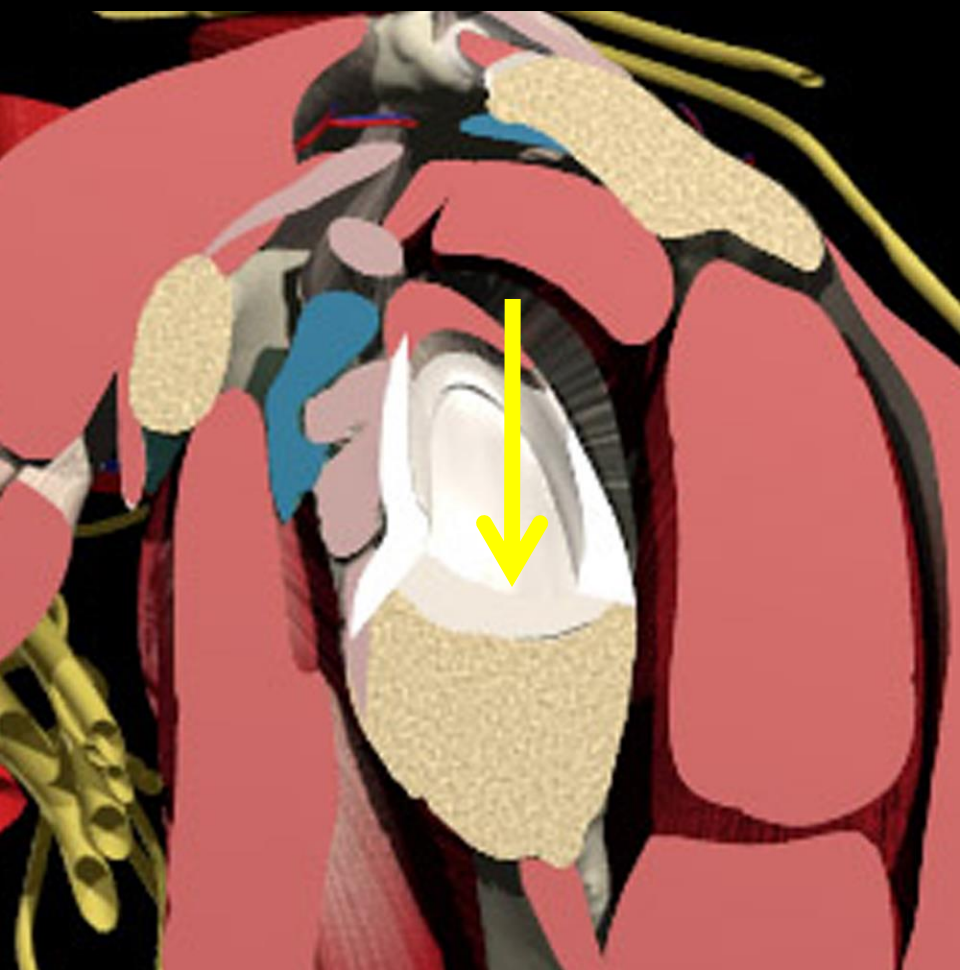


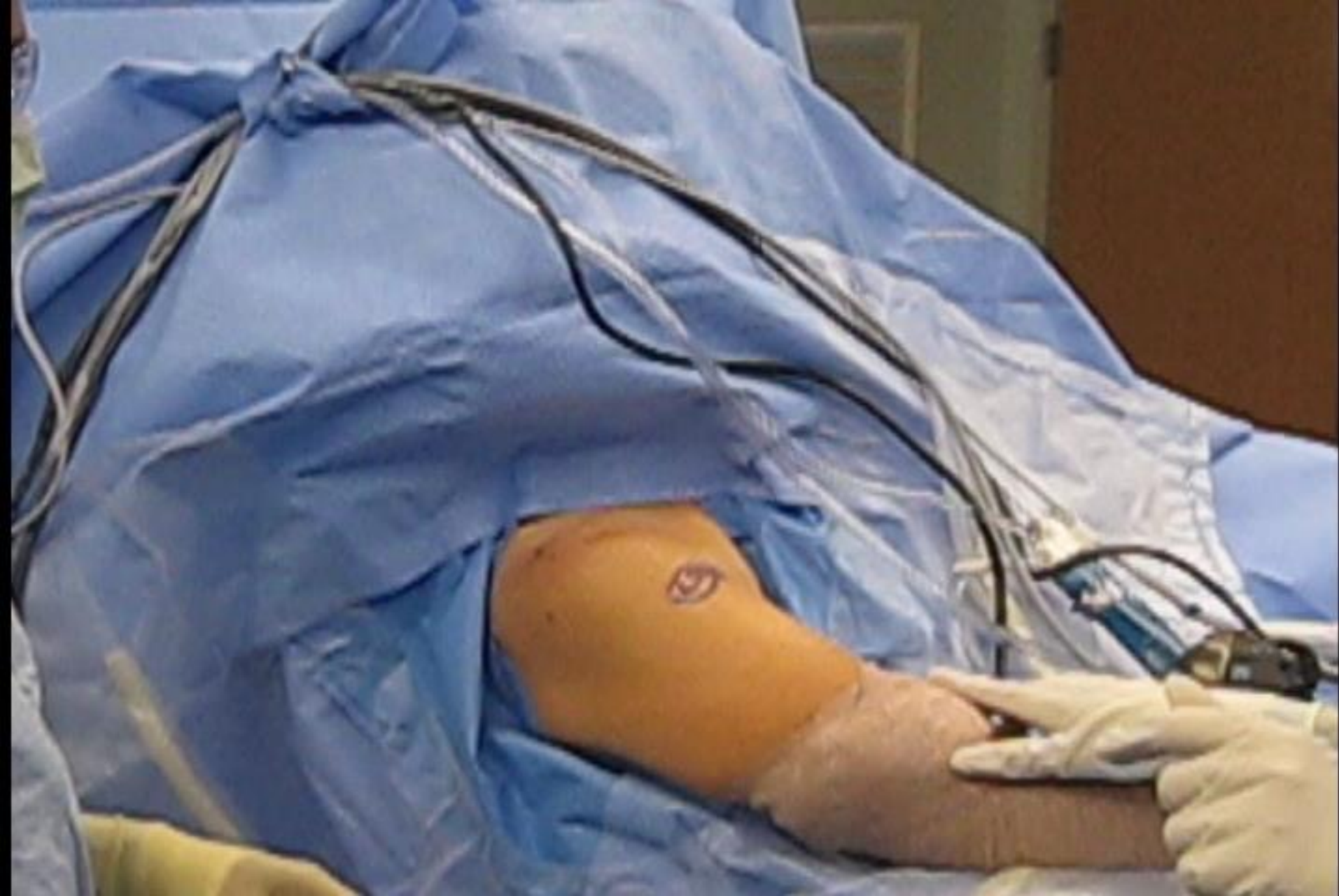


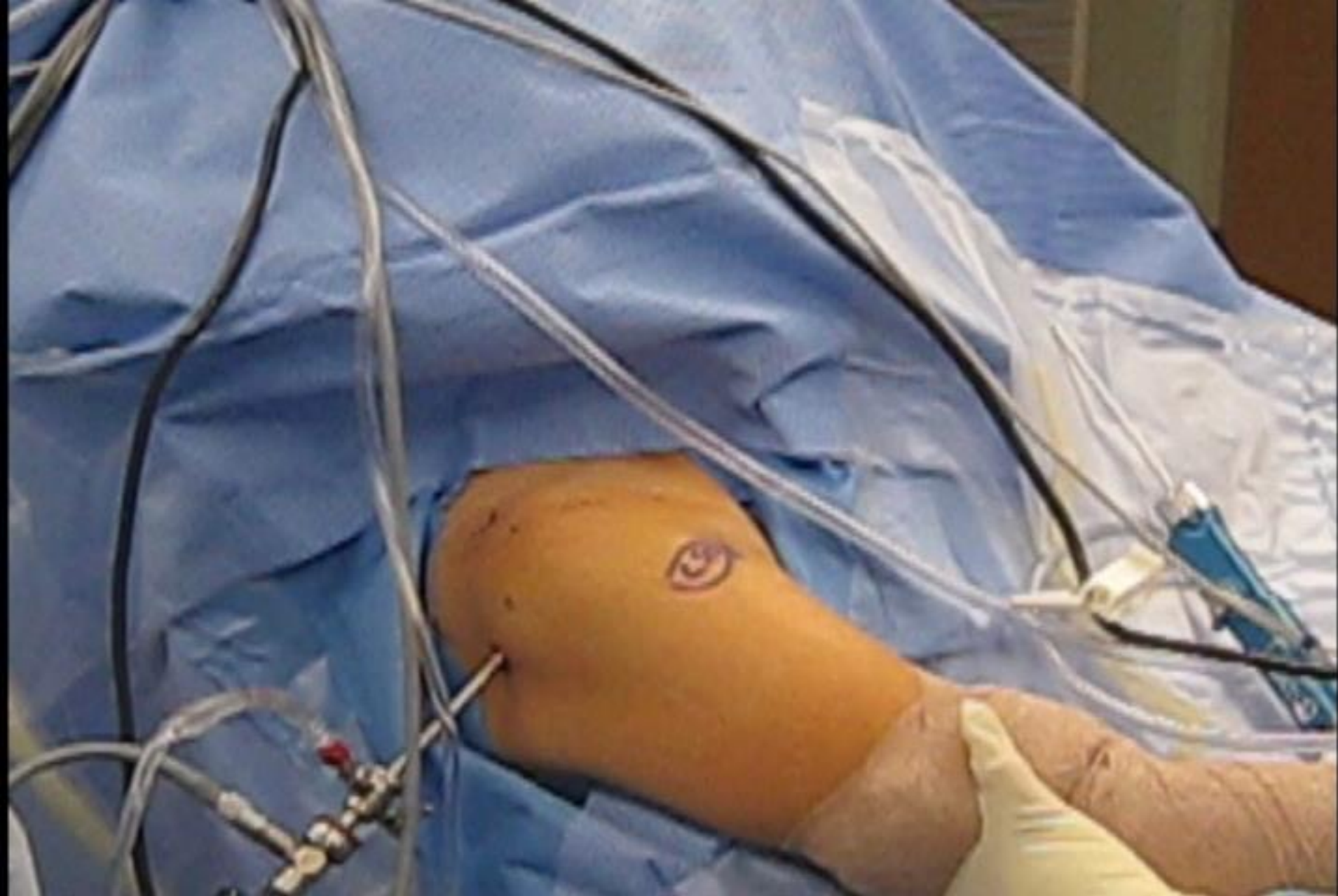


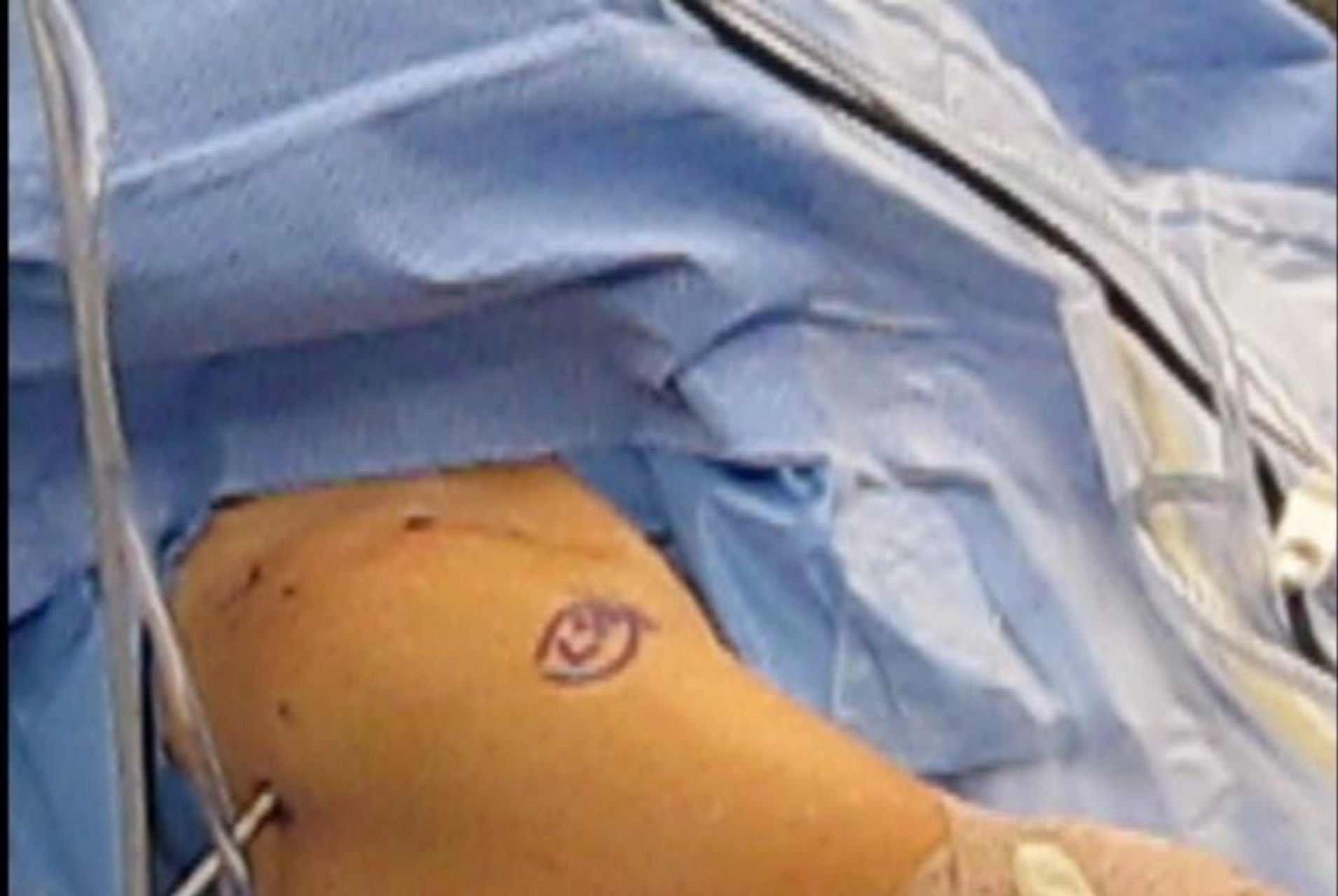


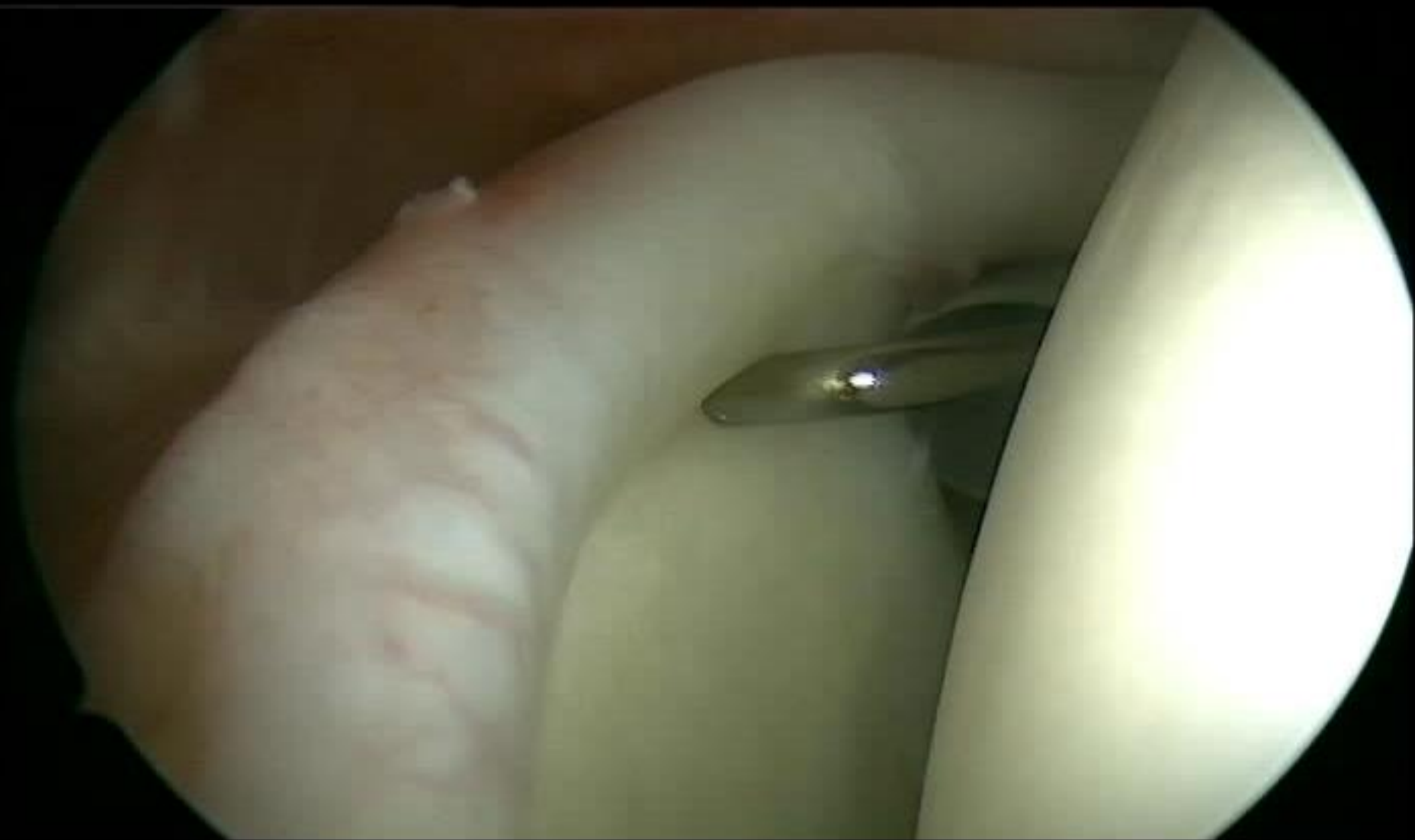


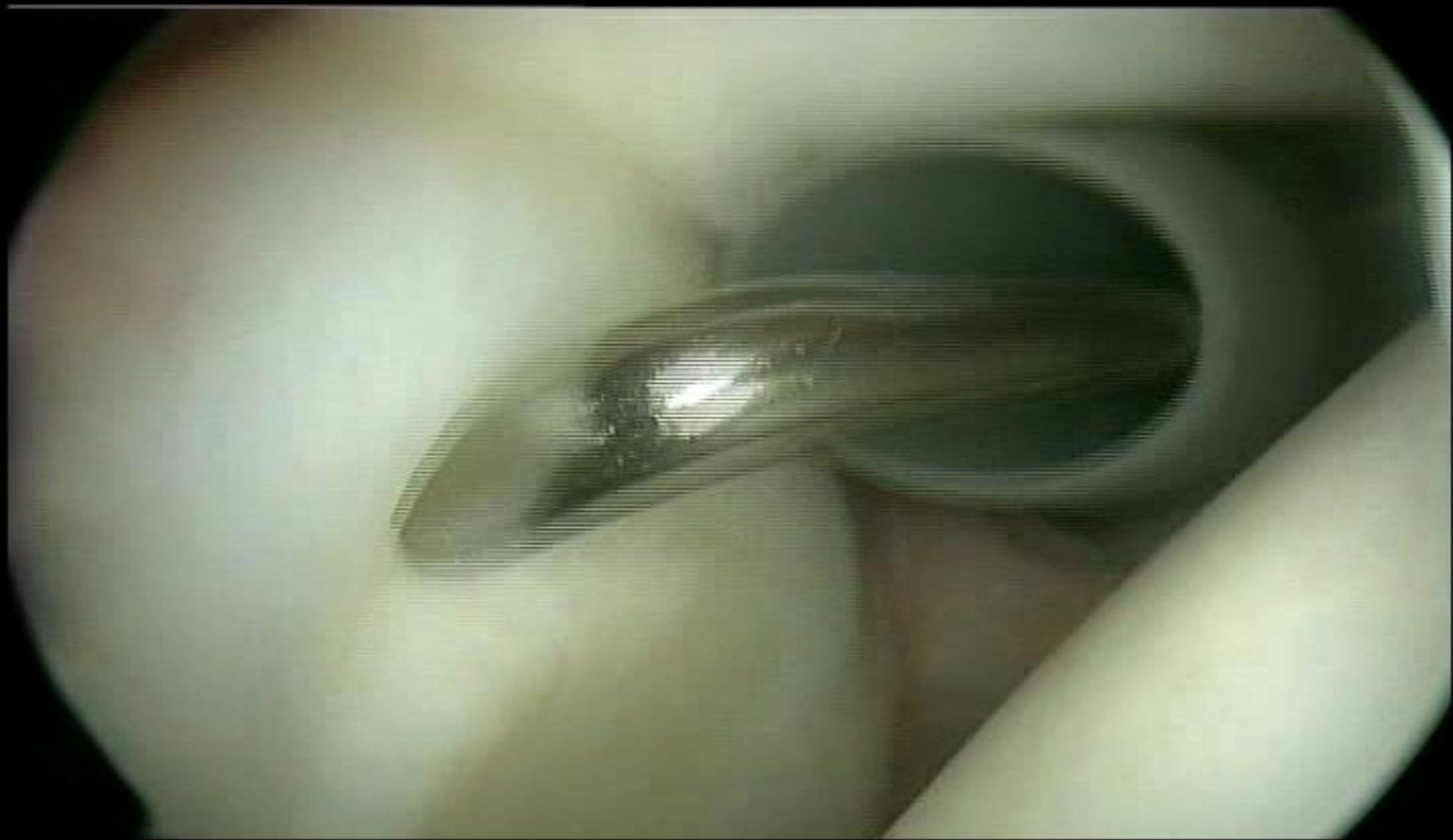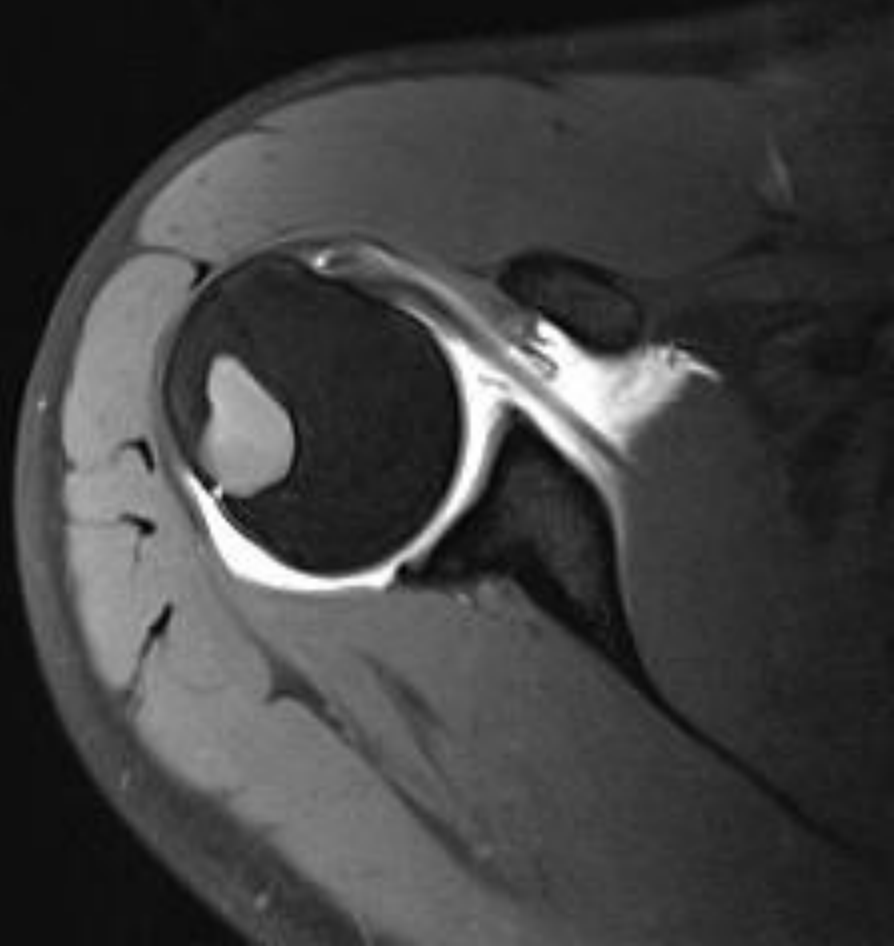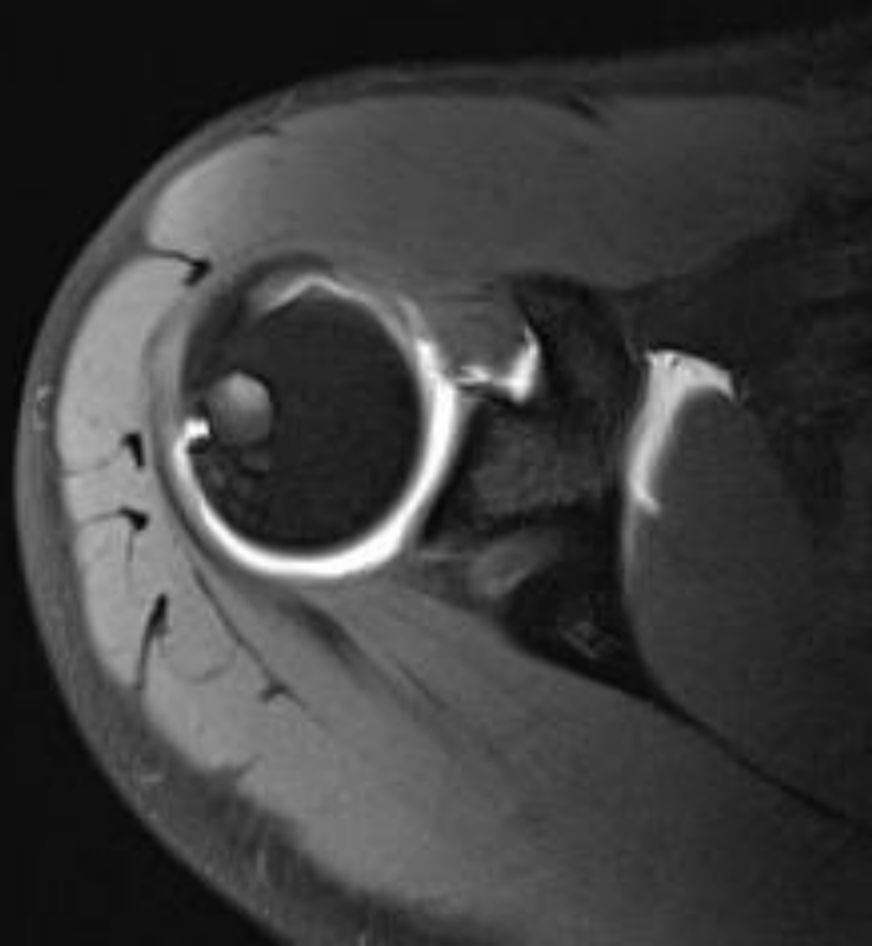


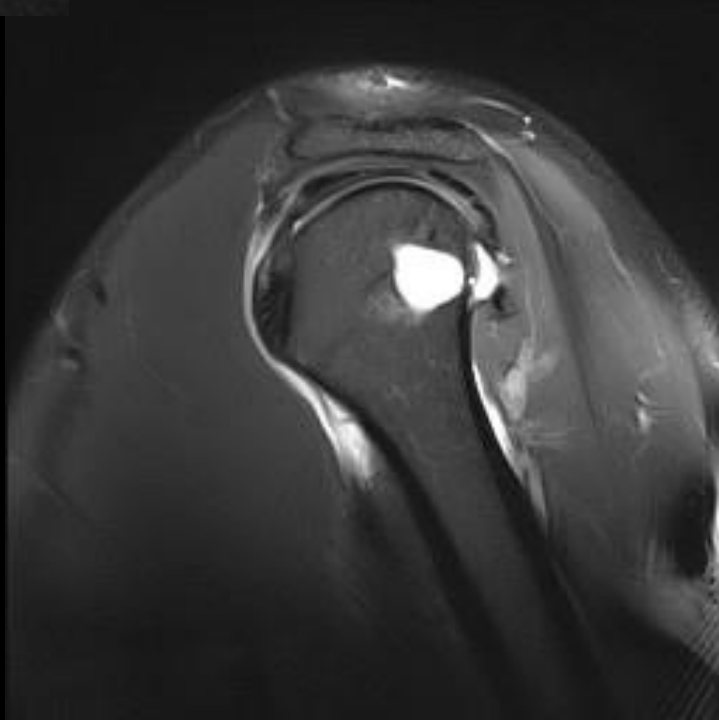

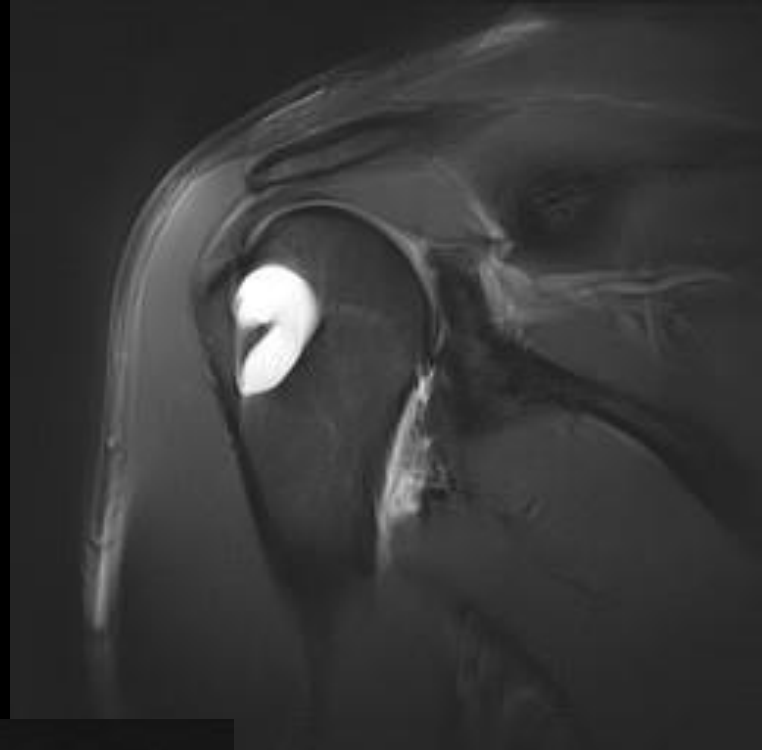
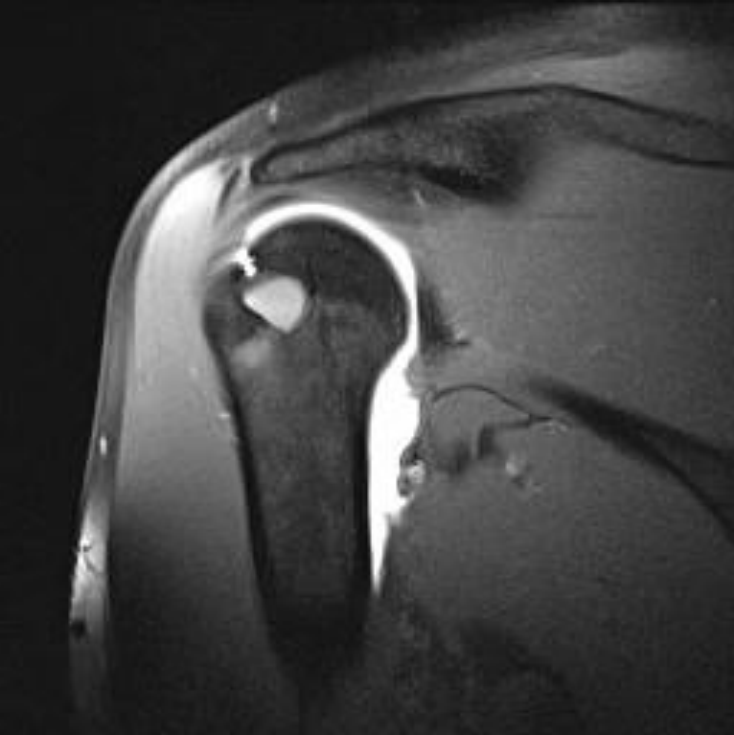


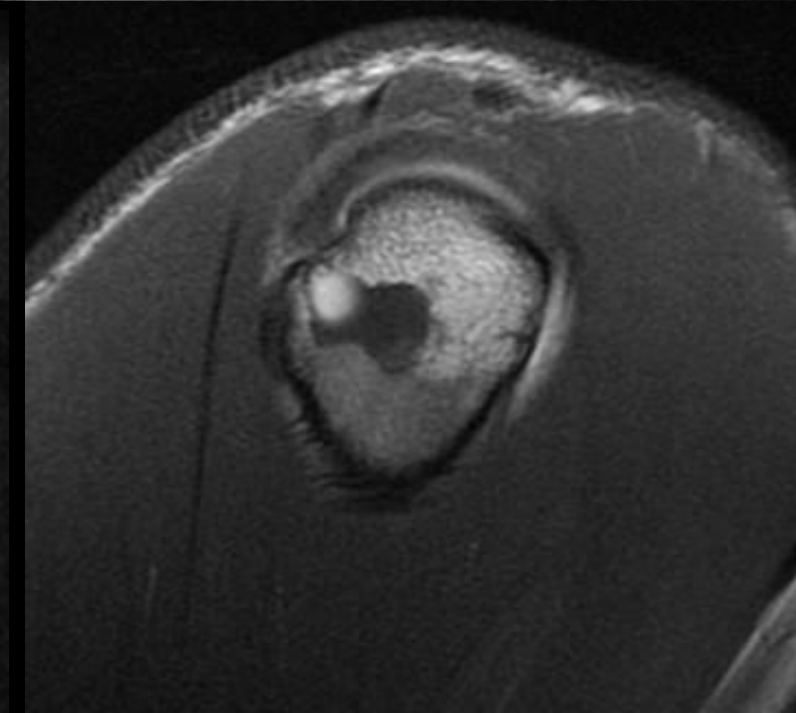
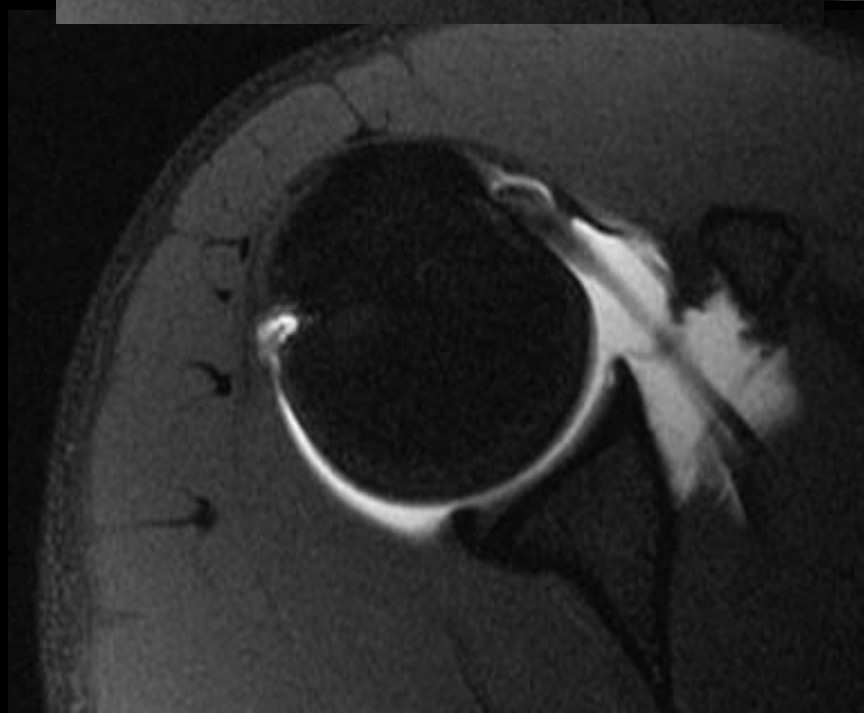
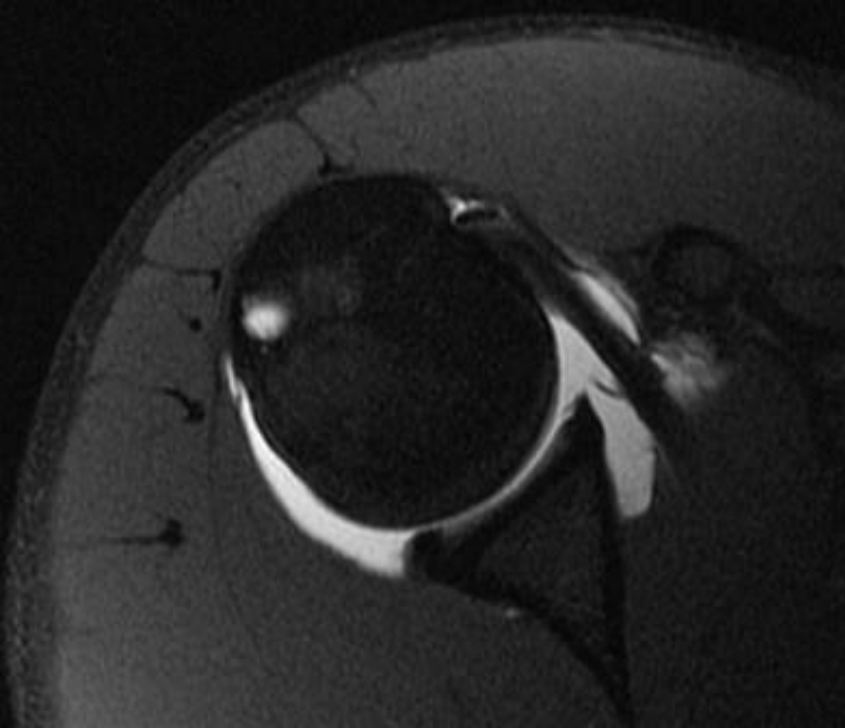
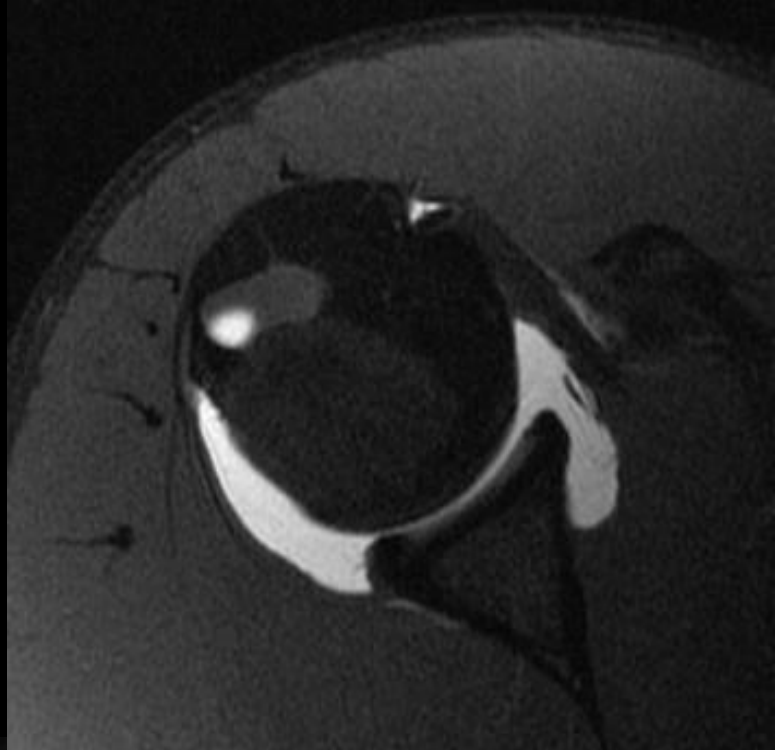


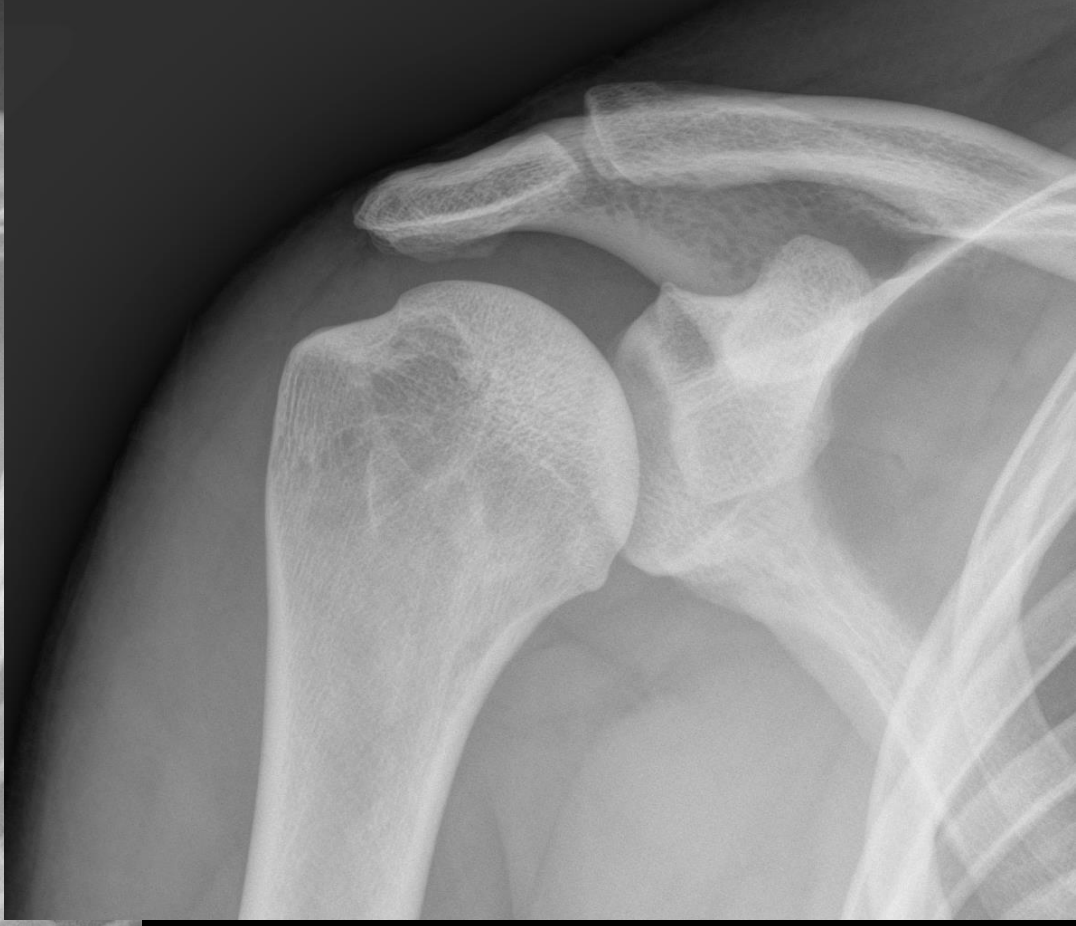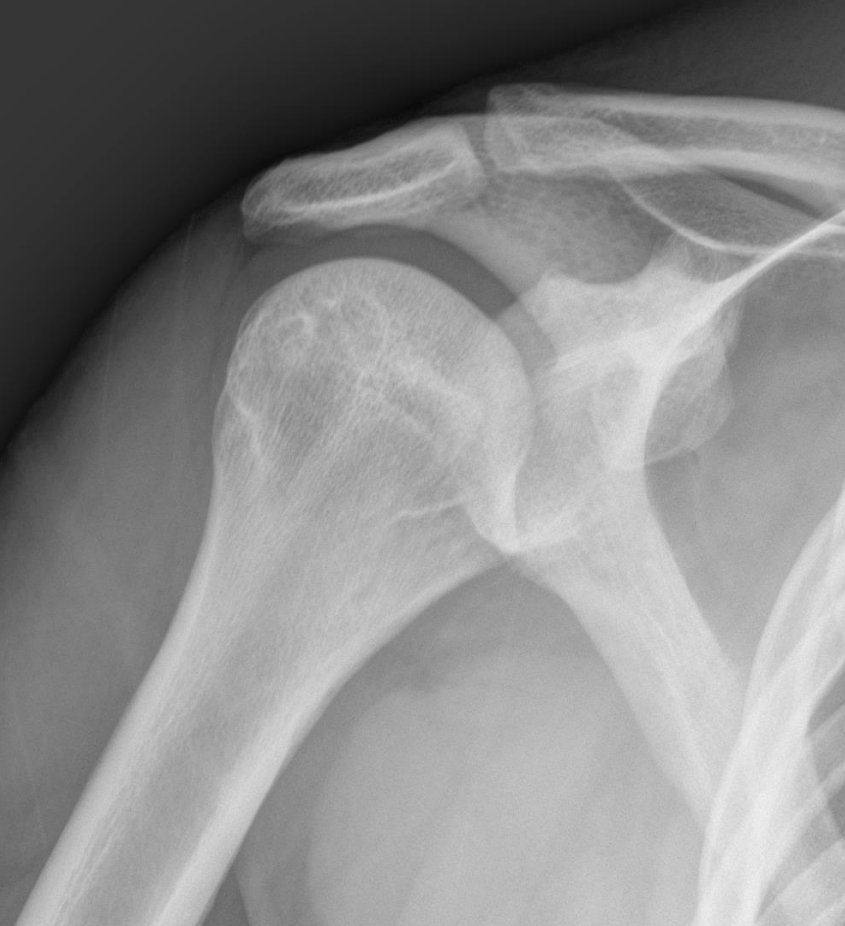


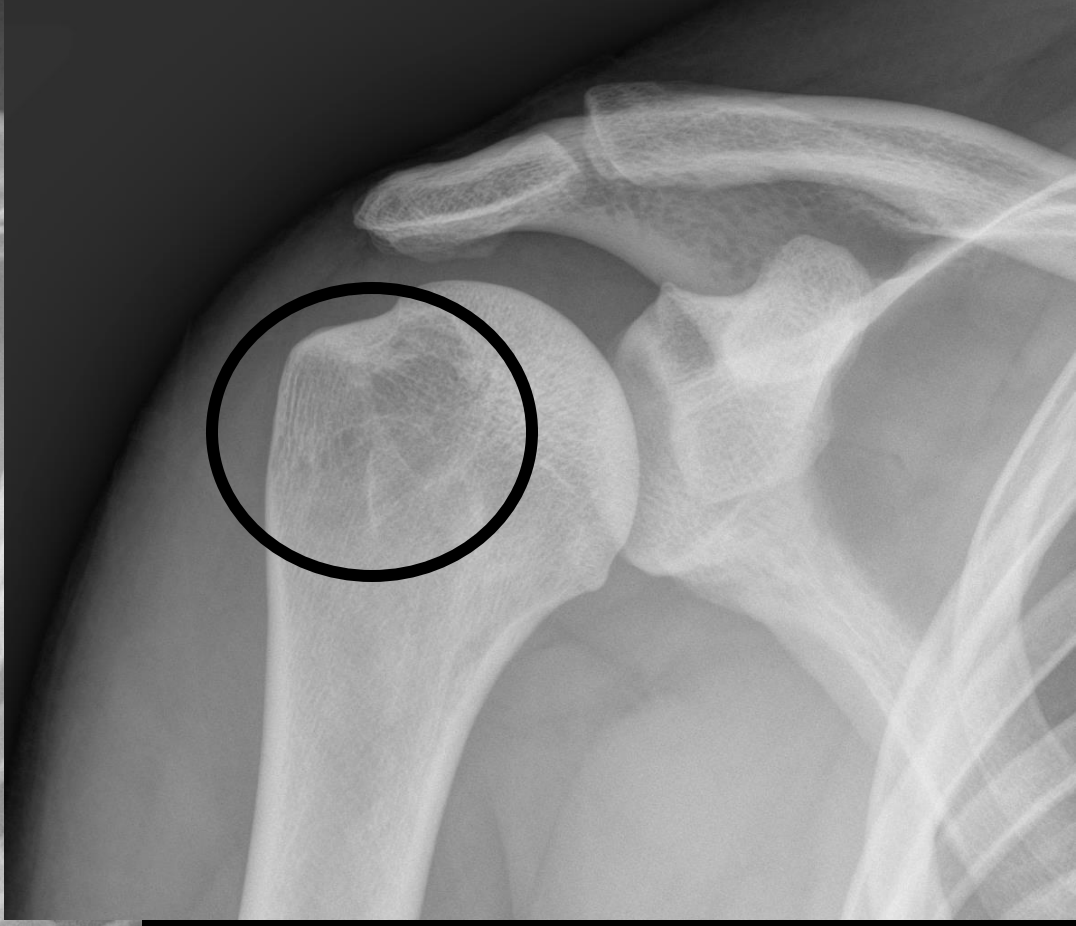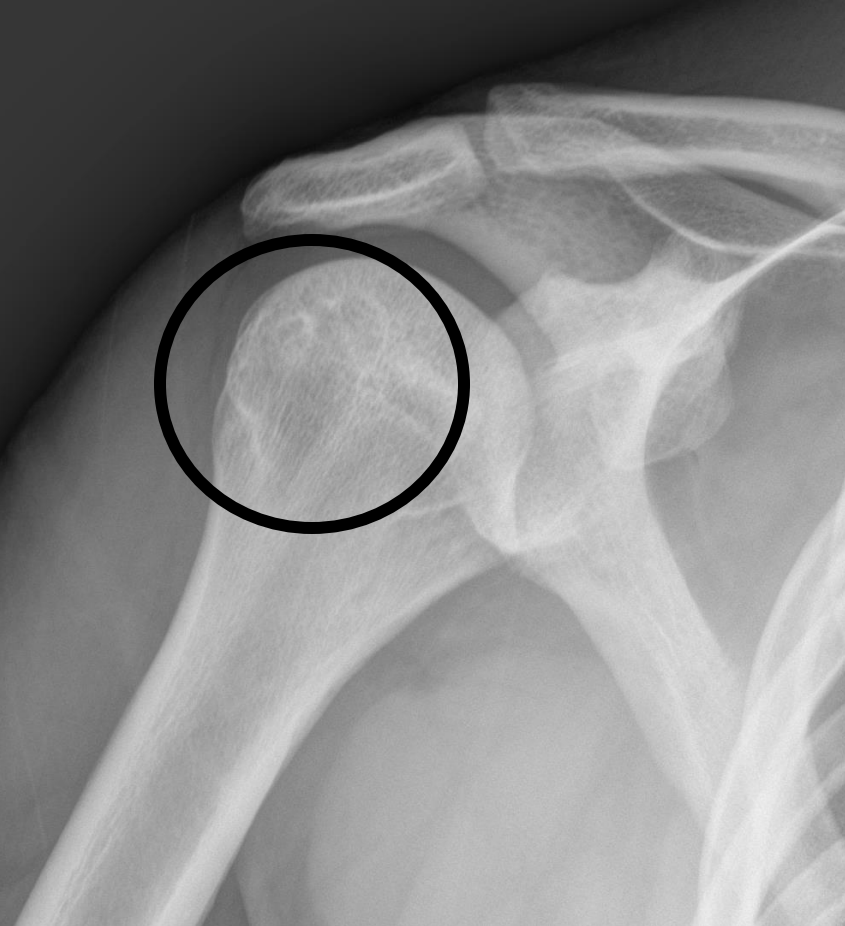


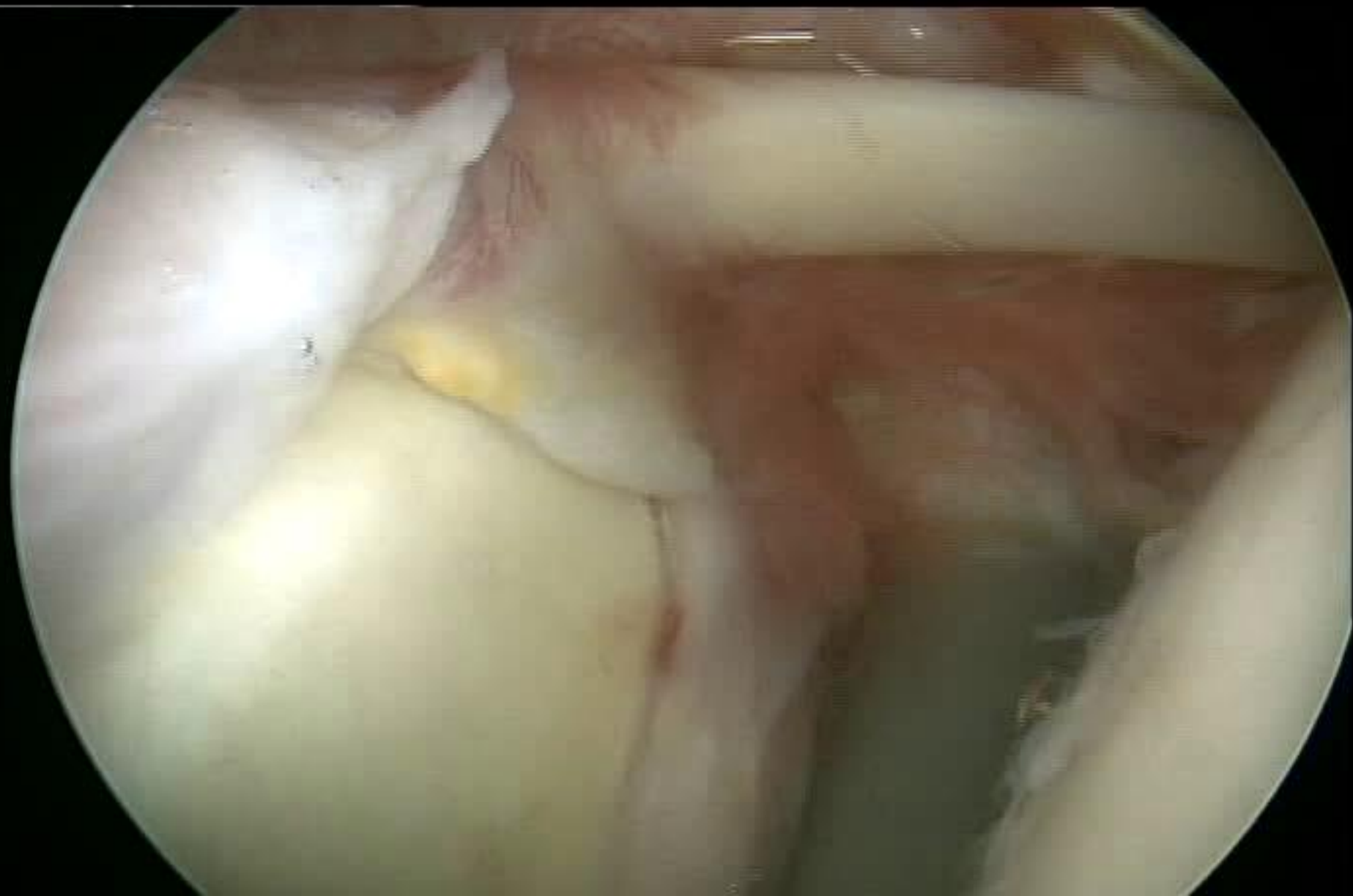


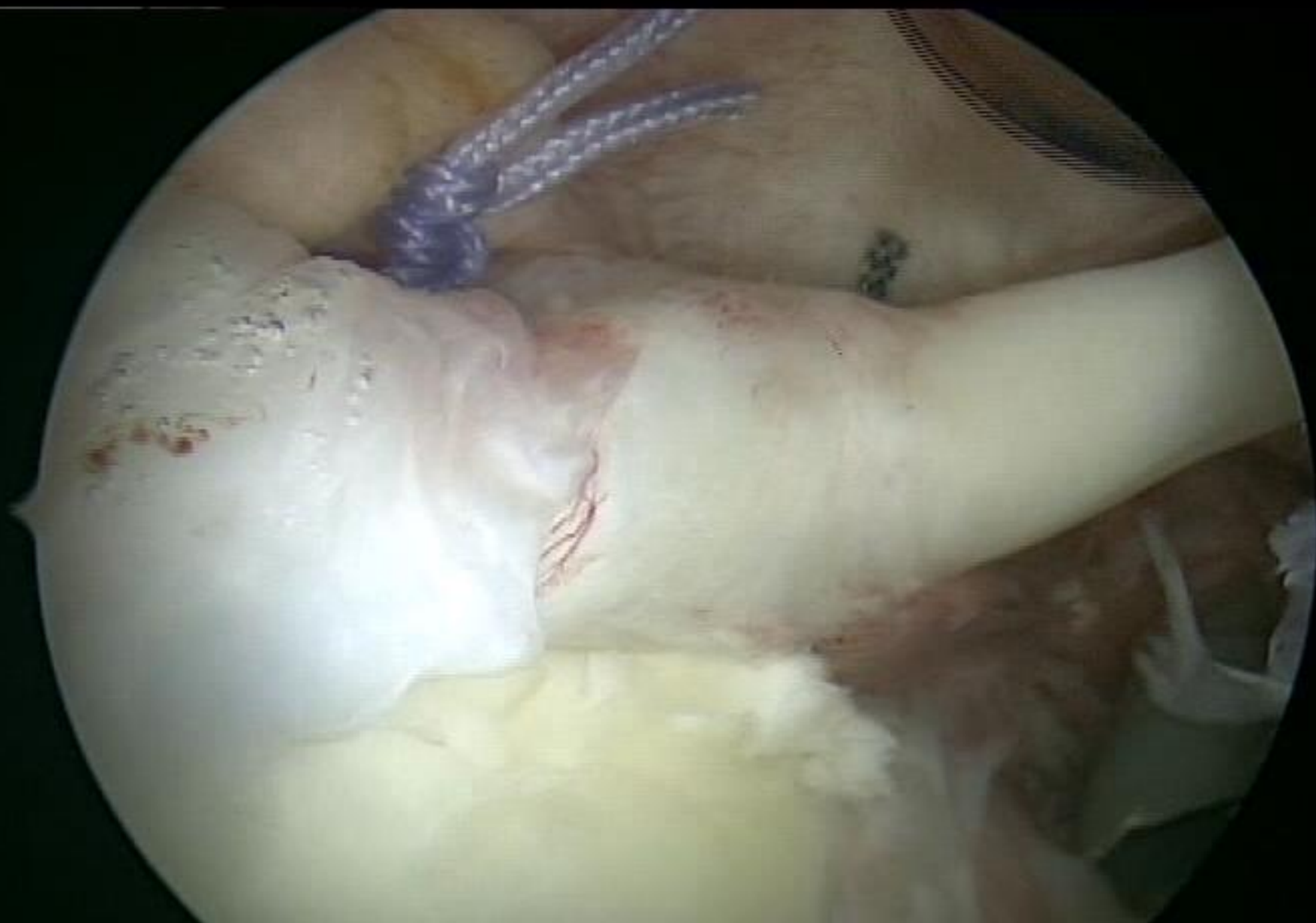












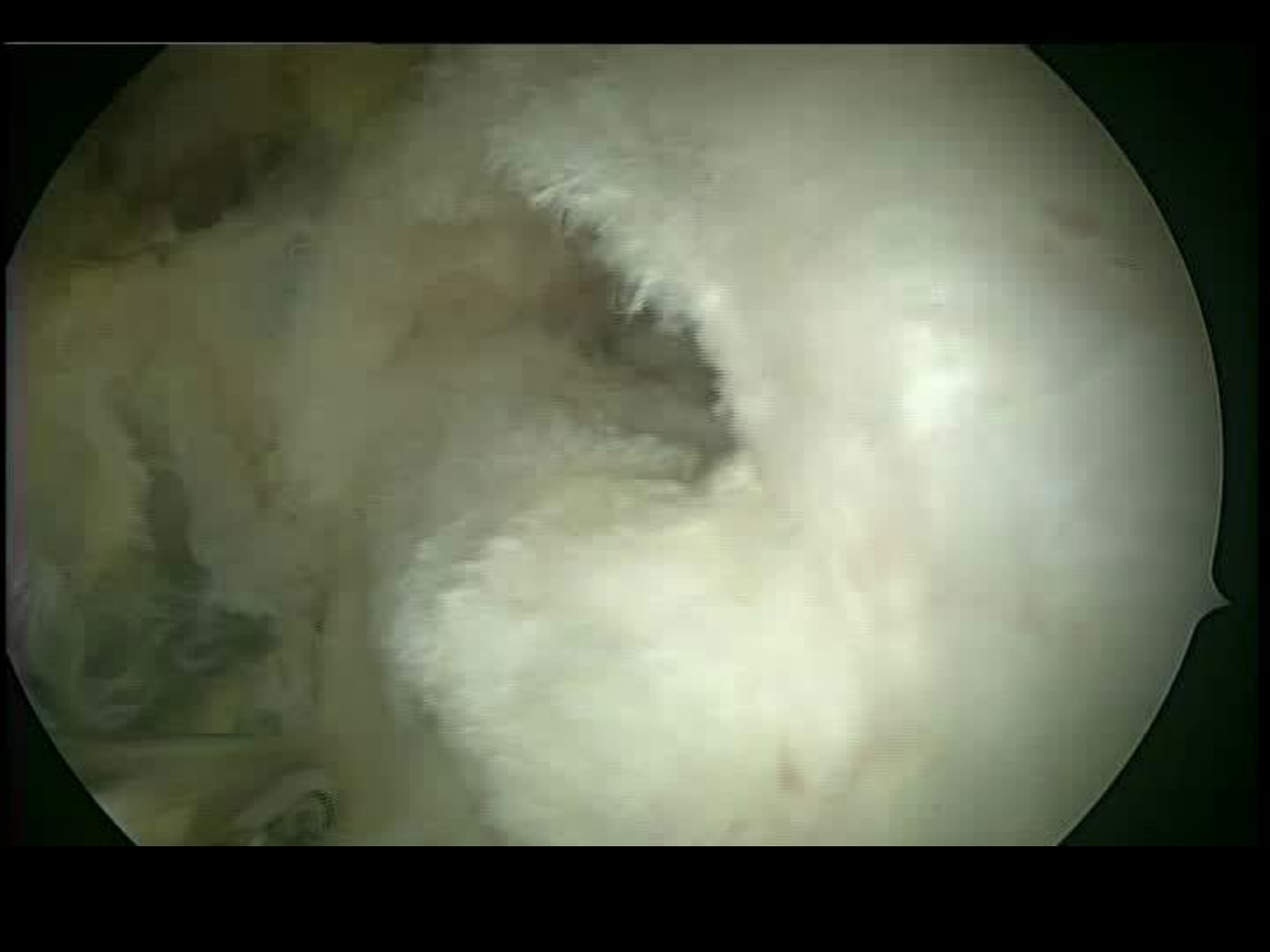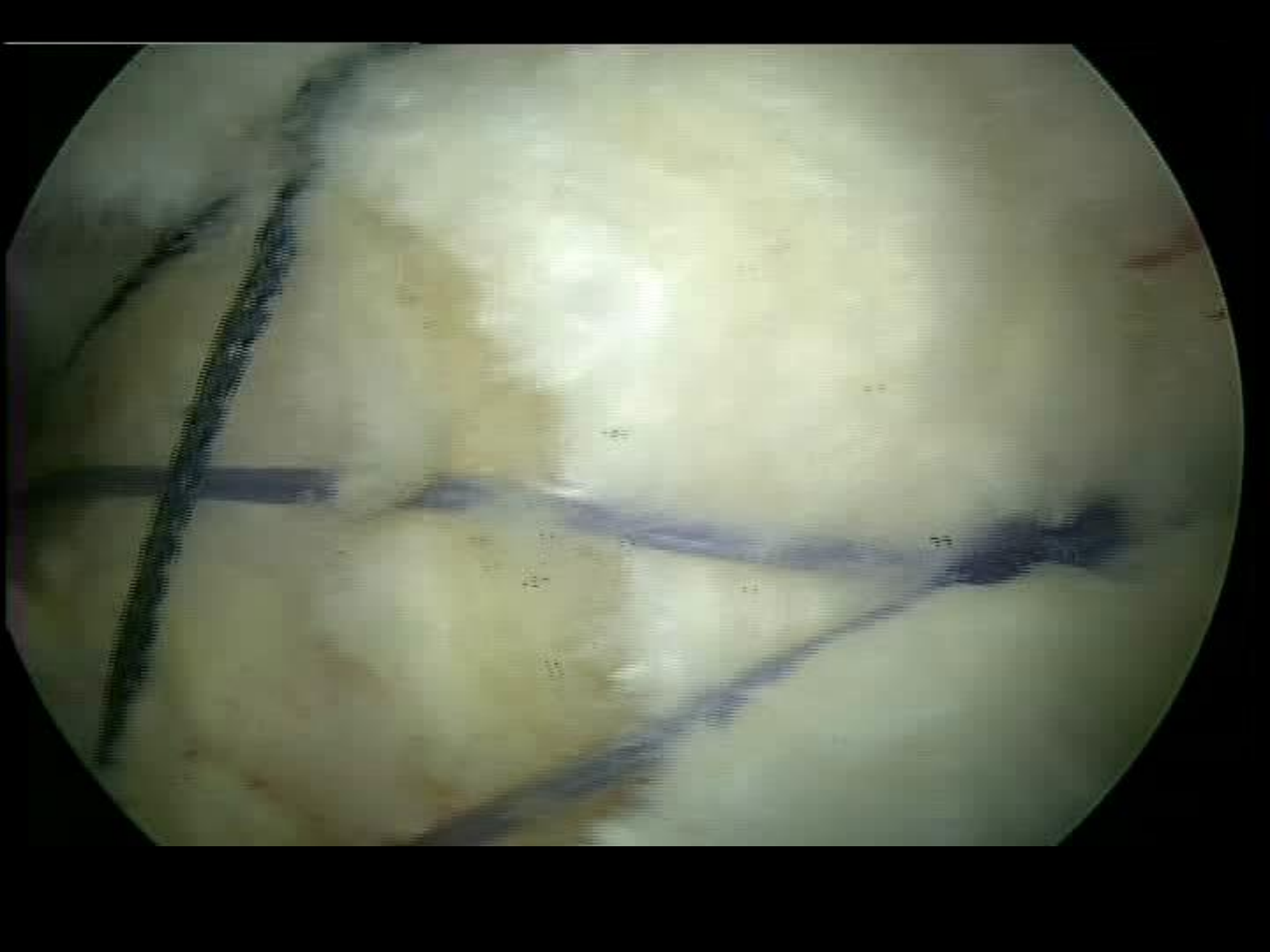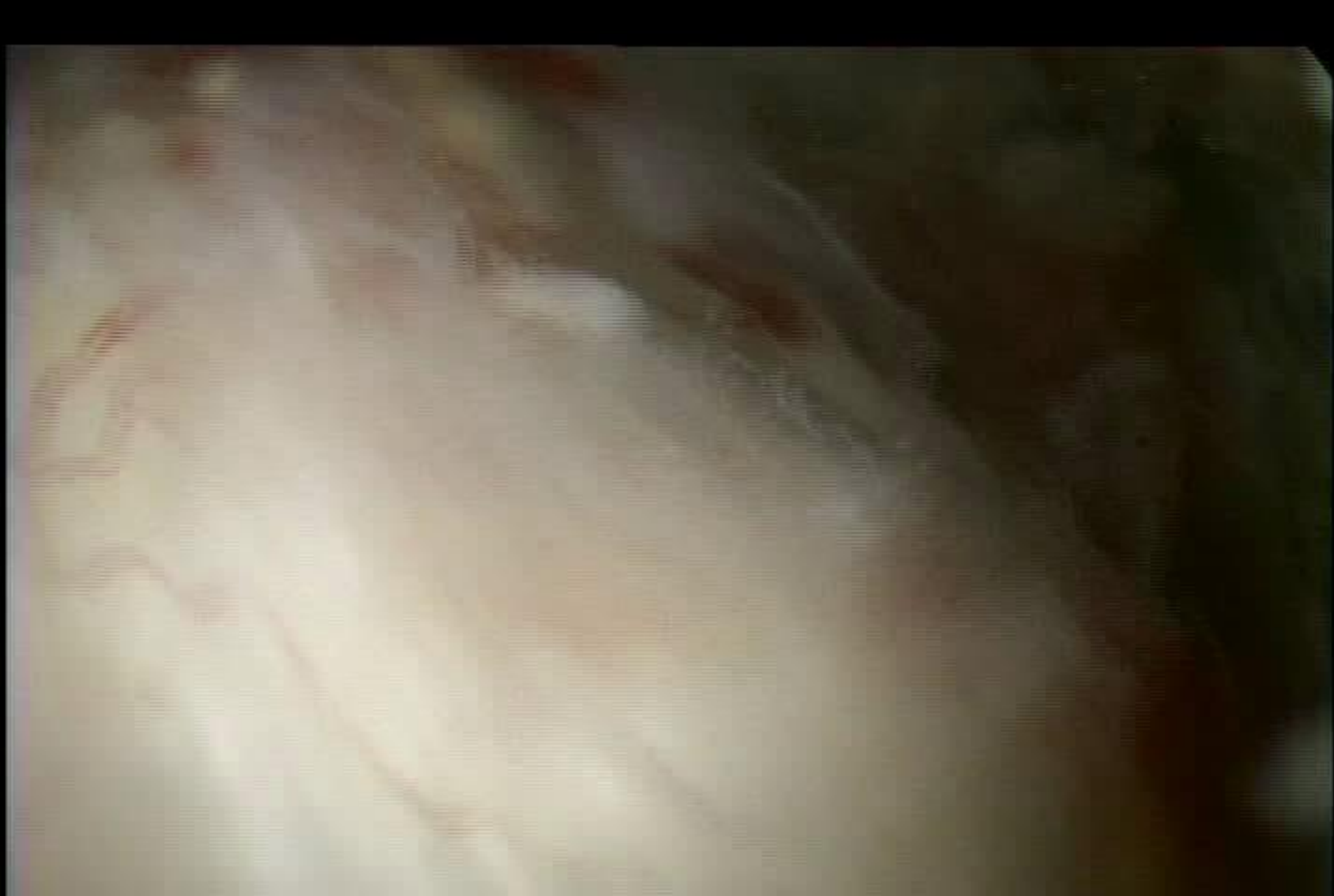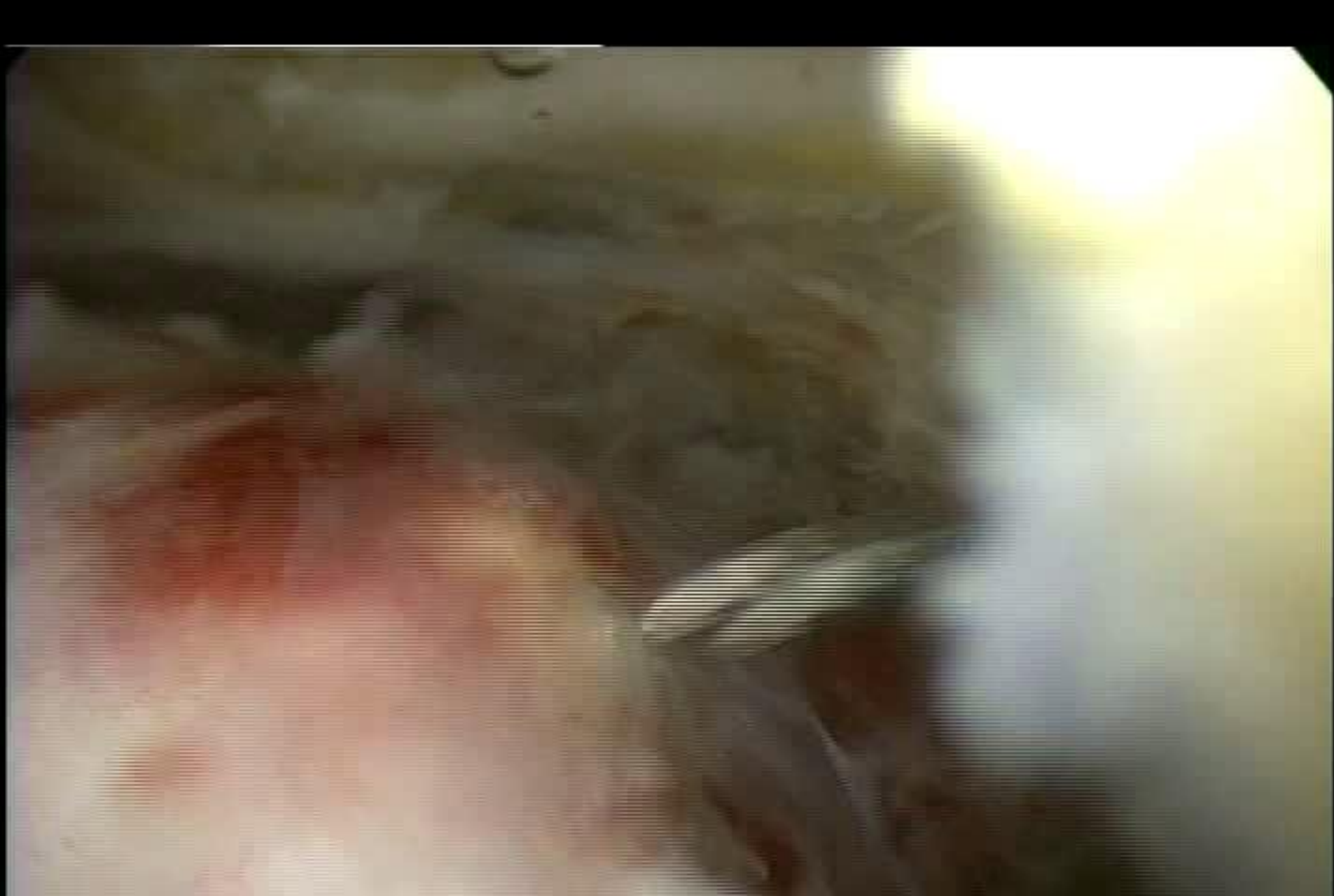


Age 2 - Video









ARTHROSCOPY TECHNIQUE SHOULDER

MARK D. MURPHEY, MD, FACR

Physician-in-Chief, AIRP

CHIEF, MUSCULOSKELETAL IMAGING