

II. REPORTING SYSTEM

A. REPORT ORGANIZATION ([Guidance chapter](#), see page 147)

The reporting system should be concise and organized using the following structure. A statement indicating that the current examination has been compared to previous examination(s) should be included (specify date[s]). If this is not included, it should be assumed that no comparison has been made, although it is preferable to indicate that no comparison was made.

Table 4. Report Organization

Report Structure
1. Indication for examination
2. Succinct description of the overall breast composition
3. Clear description of any important findings
4. Comparison to previous examination(s), if deemed appropriate by the interpreting physician
5. Assessment
6. Management

1. INDICATION FOR EXAMINATION

Provide a brief description of the indication for examination. This may be screening for an asymptomatic woman, recall of a screening-detected finding, evaluation of a clinical finding (specify the finding and its location), or follow-up of either a probably benign lesion or cancer treated with breast conservation. If an implant is present, both standard and implant-displaced views should be performed, and this should be stated in the mammography report.

2. SUCCINCT DESCRIPTION OF THE OVERALL BREAST COMPOSITION

This is an overall assessment of the volume of attenuating tissues in the breast, to help indicate the relative possibility that a lesion could be obscured by normal tissue and that the sensitivity of examination thereby may be compromised by dense breast tissue. A few coalescent areas of dense tissue may be present in breasts with as little as 10% dense tissue, whereas primarily fatty areas may be present in breasts with as much as 90% dense tissue.

Since mammography does not depict all breast cancers, clinical breast examination is a complementary element of screening. Findings at clinical breast examination should not be ignored and may have increased importance in the dense breast.

The available data do not support the use of mammographic breast density for determining screening frequency.

The following four categories of breast composition are defined by the visually estimated content of fibroglandular-density tissue within the breasts. Please note that the categories are listed as **a**, **b**, **c**, and **d** so as not to be confused with the numbered BI-RADS® assessment categories. If the breasts are not of apparently equal density, the denser breast should be used to categorize breast density. The sensitivity of mammography for noncalcified lesions decreases as the BI-RADS® breast density category increases. The denser the breast, the larger the lesion(s) that may be obscured. There is considerable intra- and inter-observer variation in visually estimating breast density between any two adjacent density categories. Furthermore, there is only

a minimal and insignificant difference in the sensitivity of mammography between the densest breast in a lower-density category and the least dense breast in the next-higher-density category. These factors limit the clinical relevance of breast density categorization for the individual woman.

Table 5. Breast Tissue

Breast Composition Categories
a. The breasts are almost entirely fatty
b. There are scattered areas of fibroglandular density
c. The breasts are heterogeneously dense, which may obscure small masses
d. The breasts are extremely dense, which lowers the sensitivity of mammography

a. The breasts are almost entirely fatty.

Unless an area containing cancer is not included in the image field of the mammogram, mammography is highly sensitive in this setting.

b. There are scattered areas of fibroglandular density (historically, there are scattered fibroglandular densities).

It may be helpful to distinguish breasts in which there are a few scattered areas of fibroglandular-density tissue from those in which there are moderate scattered areas of fibroglandular-density tissue. Note that there has been a subtle change in the wording of this category, to conform to BI-RADS® lexicon use of the term “density” to describe the degree of x-ray attenuation of breast tissue but not to represent discrete mammographic findings.

c. The breasts are heterogeneously dense, which may obscure small masses.

It is not uncommon for some areas in such breasts to be relatively dense while other areas are primarily fatty. When this occurs, it may be helpful to describe the location(s) of the denser tissue in a second sentence, so that the referring clinician is aware that these are the areas in which small noncalcified lesions may be obscured. Suggested wordings for the second sentence include:

“The dense tissue is located anteriorly in both breasts, and the posterior portions are mostly fatty.”

“Primarily dense tissue is located in the upper outer quadrants of both breasts; scattered areas of fibroglandular tissue are present in the remainder of the breasts.”

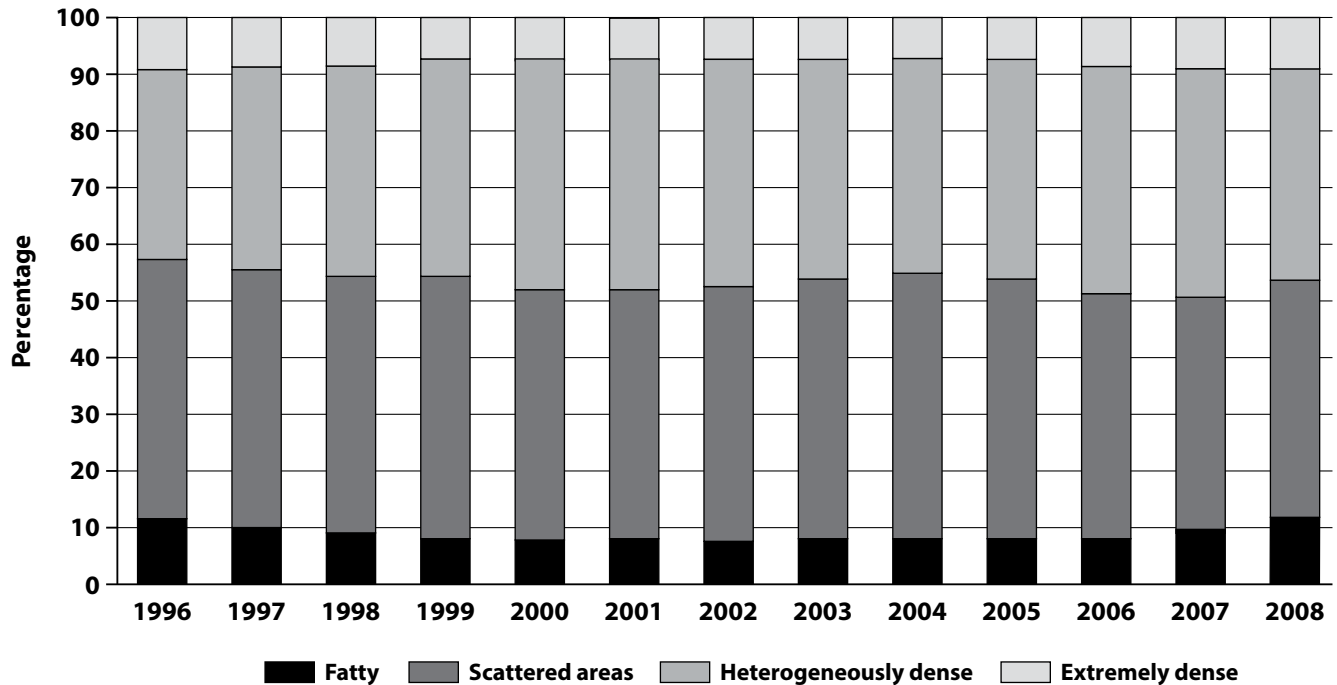
d. The breasts are extremely dense, which lowers the sensitivity of mammography.

The sensitivity of mammography is lowest in this density category.

The fourth edition of BI-RADS®, unlike previous editions, indicated quartile ranges of percentage dense tissue (increments of 25% density) for each of the four density categories, with the expectation that the assignment of breast density would be distributed more evenly across categories than the historical distribution of 10% fatty, 40% scattered, 40% heterogeneously, and 10% extremely dense. However, it has since been demonstrated in

clinical practice that there has been essentially no change in this historical distribution across density categories, despite the 2003 guidance provided in the BI-RADS® Atlas (Figure 149).

Figure 149 – U.S. Radiologists' Use of BI-RADS® Breast Density Descriptors, 1996–2008



Data from 3,865,070 screening mammography examinations interpreted by radiologists who participate in the Breast Cancer Surveillance Consortium (BCSC), a group of seven population-based mammography registries covering geographically, ethnically, and socioeconomically diverse areas of the United States. Data collection for this work was supported by the National Cancer Institute-funded BCSC cooperative agreement (U01CA63740, U01CA86076, U01CA86082, U01CA63736, U01CA70013, U01CA69976, U01CA63731, U01CA70040). We thank the BCSC investigators, participating women, mammography facilities, and radiologists for the data they have provided for this study. A list of the BCSC investigators and procedures for requesting BCSC data for research purposes are provided at: <http://breastscreening.cancer.gov/>.

The absence of change in clinical practice of the assignment of breast density across categories may reflect the reality that a few coalescent areas of dense tissue may be present in breasts with as little as 10% dense tissue, whereas primarily fatty areas may be present in breasts with as much as 90% dense tissue.

The fifth edition of BI-RADS® no longer indicates ranges of percentage dense tissue for the four density categories. This is done to emphasize the text descriptions of breast density, which reflect the masking effect of dense fibroglandular tissue on mammographic depiction of noncalcified lesions, because the Committee on BI-RADS® concludes that the association of subjectively estimated breast density with changes in the sensitivity of mammography is clinically more important than the relatively smaller effect of percentage breast density as an indicator for breast cancer risk.

The Committee on BI-RADS® indeed is aware of recent and continuing investigations of percentage breast density as an indicator for breast cancer risk, and by eliminating percentage ranges we do not intend to compromise or impede any such research. We simply recognize the reality that interpreting physicians will continue to use density categories in mammography reports as they have done over the past many years, independent of BI-RADS® guidance on percentage breast density. We further recognize that both subjective estimates and planimetry measurements of breast density based on area as depicted on (2-D) mammograms are imprecise indicators of the volume of dense tissue, which may be measured using (3-D) cross-sectional breast imaging modalities.¹ We await publication of robust volume-based breast density data, using validated percentage cut points (not necessarily quartiles) that are readily and reproducibly determined at imaging, before again indicating percentage ranges for BI-RADS® density categories. We also urge avoidance of numbers to classify breast density instead of BI-RADS® terminology in order to avoid confusion with BI-RADS® assessment categories, which are numbered.

Some breasts may appear more or less dense when imaged using full-field digital mammography compared to screen-film mammography. Superior depiction of the skin line by digital mammography provides the observer with a more accurate (and usually larger) estimate of the extent of the subcutaneous fat. However, no change in the distribution across density categories has been observed when comparing full-field digital mammography with screen-film mammography.²

BREAST COMPOSITION ILLUSTRATIONS

BREAST COMPOSITION ILLUSTRATIONS

a. The breasts are almost entirely fatty.

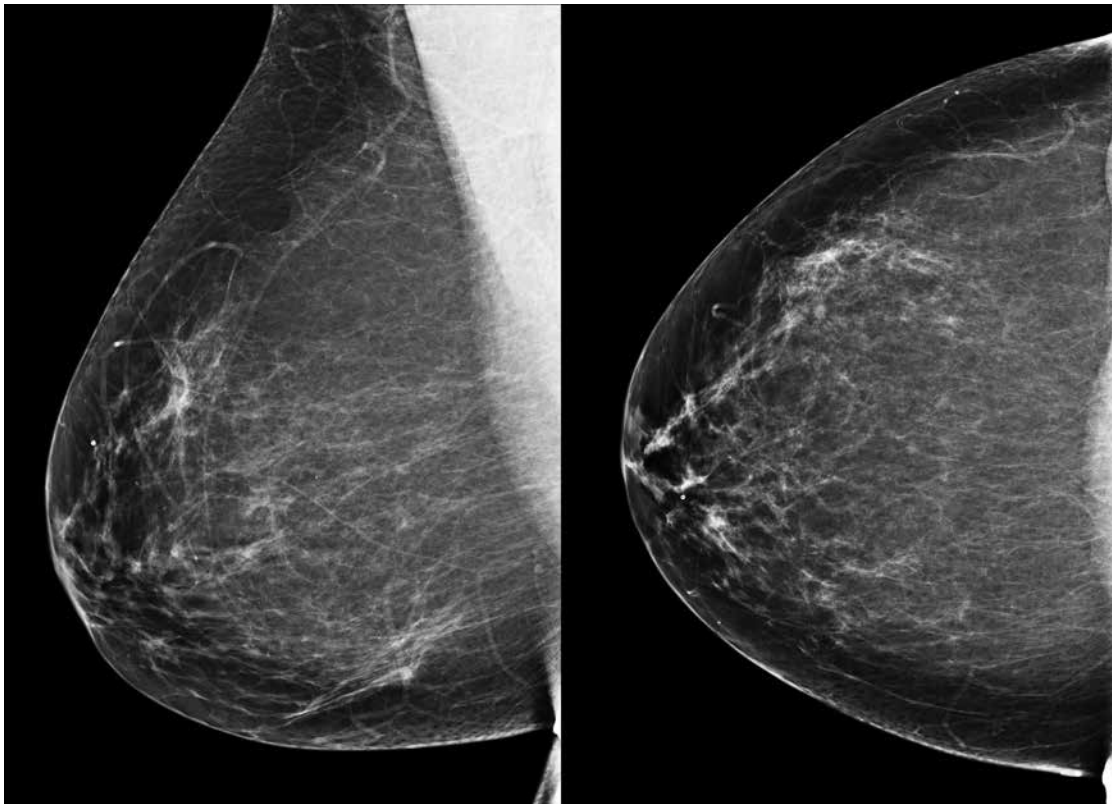


Figure 150 — The breasts are almost entirely fatty.

BREAST COMPOSITION ILLUSTRATIONS

b. There are scattered areas of fibroglandular density.

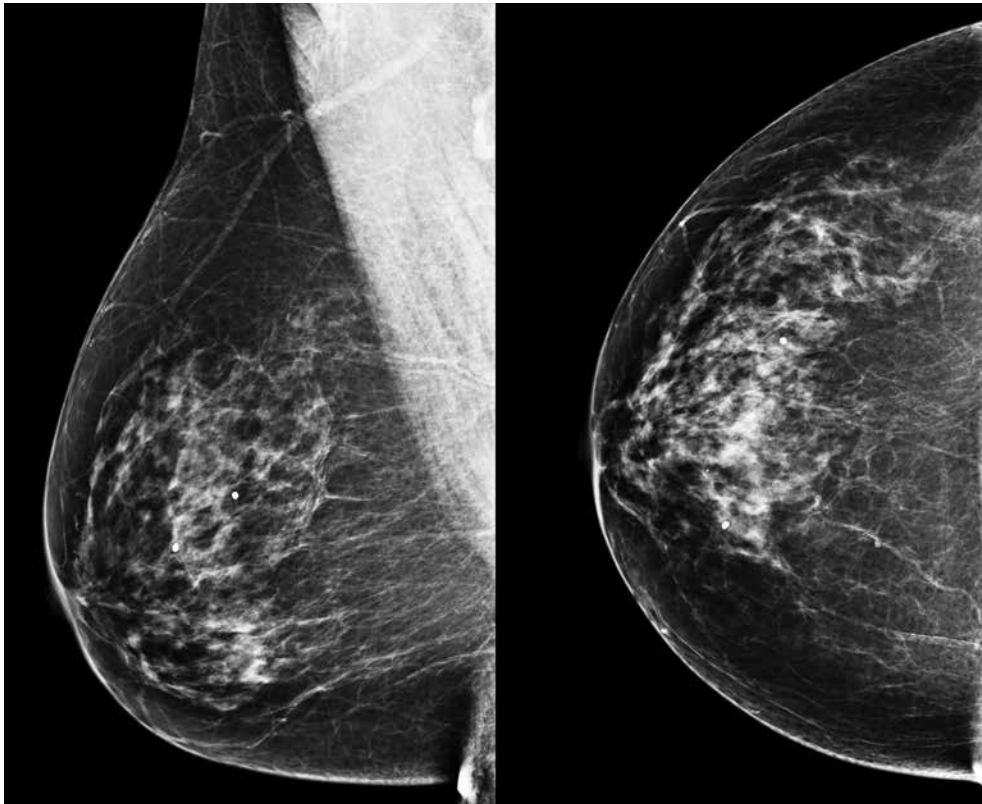


Figure 151— There are scattered areas of fibroglandular density.

BREAST COMPOSITION ILLUSTRATIONS

c. The breasts are heterogeneously dense, which may obscure small masses.

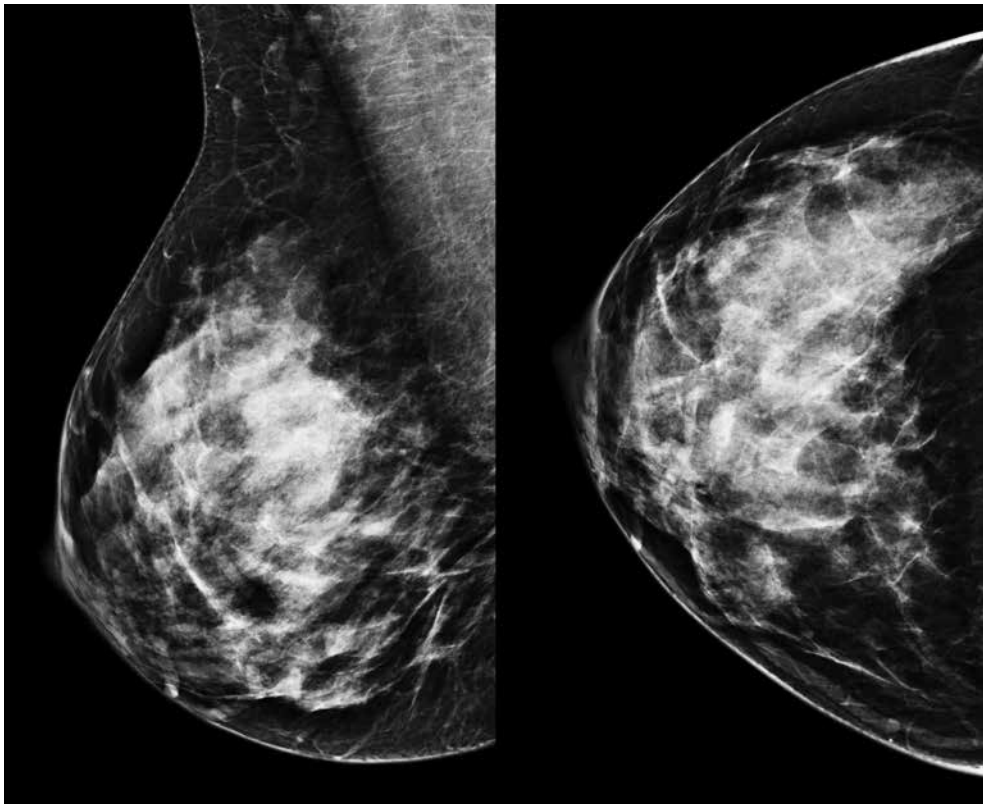


Figure 152 — The breasts are heterogeneously dense, which may obscure small masses.

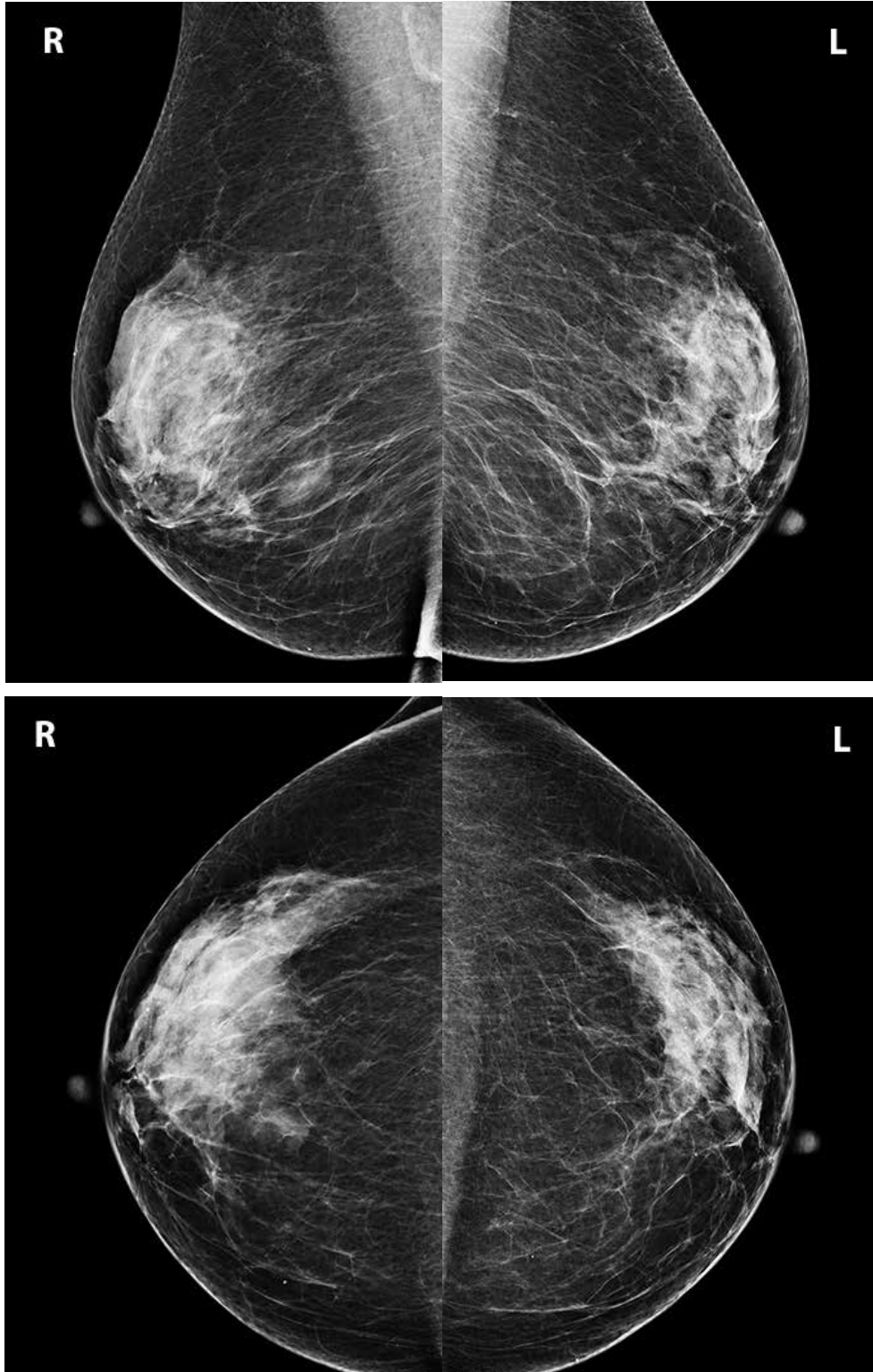


Figure 153 — Breast density is classified using the denser breast. In this case, because the fibroglandular tissue in the upper outer right breast is sufficiently dense to obscure small masses, the examination should be classified as HETEROGENEOUSLY DENSE, even though far less than 50% of the volume of this (denser) breast contains fibroglandular-density tissue.

BREAST COMPOSITION ILLUSTRATIONS

d. The breasts are extremely dense, which lowers the sensitivity of mammography.

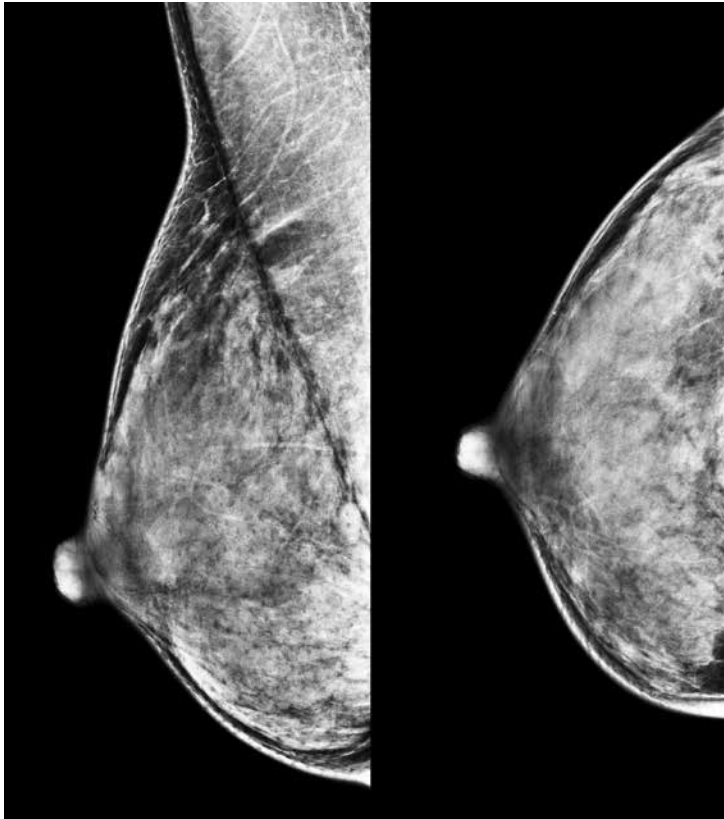


Figure 154 — The breasts are extremely dense, which lowers the sensitivity of mammography.

3. CLEAR DESCRIPTION OF ANY IMPORTANT FINDINGS

(It is assumed that most important findings are either of concern at screening, inherently suspicious, new, or seen to be larger/more extensive when compared to previous examination.)

a. **Mass:**

Size

Morphology (shape, margin)

Density

Associated calcifications

Associated features

Location

b. **Calcifications:**

Morphology — describe typically benign type or describe shape of particles

Distribution (may not be appropriate for typically benign calcifications)

Associated features

Location

c. **Architectural Distortion:**

Associated calcifications

Associated features

Location

d. **Asymmetries** (asymmetry, global asymmetry, focal asymmetry, developing asymmetry):

Associated calcifications

Associated features

Location

e. **Intramammary lymph node** (rarely important):

Location

f. **Skin lesion** (rarely important):

Location

g. **Solitary dilated duct** (rarely present):

Location

4. COMPARISON TO PREVIOUS EXAMINATION(S), IF DEEMED APPROPRIATE BY THE INTERPRETING PHYSICIAN

Comparison to previous examination may assume importance if the finding of concern requires an evaluation of change or stability. Comparison is not important when a finding has unequivocally benign features. Comparison may be irrelevant when the finding is inherently suspicious for malignancy.

5. ASSESSMENT

The incorporation of an assessment category in the overall summary of the mammography report is mandated by the Food and Drug Administration, Quality Mammography Standards; Final Rule.³ Whereas FDA-mandated assessments are not linked to management recommendations, BI-RADS® assessment categories are designed to be concordant with specific management recommendations. The linking of assessment categories with concordant management recommendations further enhances sound medical practice.

All final assessments (BI-RADS® categories 1, 2, 3, 4, 5, and 6) should be based on thorough evaluation of the mammographic features of concern or after determination that an examination is negative or benign.

An incomplete (category 0) assessment is usually given for screening examinations when additional imaging evaluation is recommended before it is appropriate to render a final assessment. There may be rare situations in the screening setting in which a category 4 or 5 assessment is used, but this practice is discouraged because it may compromise some aspects of outcome analysis.

A recall (category 0) assessment should include specific suggestions for the next course of action (spot-compression magnification views, US, etc.).

6. MANAGEMENT

If a suspicious abnormality is identified, the report should indicate that a biopsy should be performed in the absence of clinical contraindication. This is an assessment for which the interpreting physician has sufficient concern that biopsy is warranted based on imaging findings. The recommended language (“biopsy should be performed in the absence of clinical contraindication”) provides for the unusual circumstance in which either the patient or her physician might reasonably wish to defer a biopsy.

Interpretation is facilitated by recognizing that most examinations may be categorized under a few headings. These are listed in [Table 6](#) and numeric codes are included for computer use.

B. ASSESSMENT CATEGORIES

Table 6. Concordance Between BI-RADS® Assessment Categories and Management Recommendations

Assessment	Management	Likelihood of Cancer
Category 0: Incomplete – Need Additional Imaging Evaluation and/or Prior Mammograms for Comparison	Recall for additional imaging and/or comparison with prior examination(s)	N/A
Category 1: Negative	Routine mammography screening	Essentially 0% likelihood of malignancy
Category 2: Benign	Routine mammography screening	Essentially 0% likelihood of malignancy
Category 3: Probably Benign	Short-interval (6-month) follow-up or continued surveillance mammography (Figure 155 , see page 152)	> 0% but ≤ 2% likelihood of malignancy
Category 4: Suspicious Category 4A: <i>Low suspicion</i> for malignancy Category 4B: <i>Moderate suspicion</i> for malignancy Category 4C: <i>High suspicion</i> for malignancy	Tissue diagnosis	> 2% but < 95% likelihood of malignancy > 2% to ≤ 10% likelihood of malignancy > 10% to ≤ 50% likelihood of malignancy > 50% to < 95% likelihood of malignancy
Category 5: Highly Suggestive of Malignancy	Tissue diagnosis	≥ 95% likelihood of malignancy
Category 6: Known Biopsy-Proven Malignancy	Surgical excision when clinically appropriate	N/A

a. Mammographic Assessment Is Incomplete

Category 0: Incomplete — Need Additional Imaging Evaluation and/or Prior Mammograms for Comparison

For this assessment category, the text may be shortened to “Incomplete — Need Additional Imaging Evaluation” or “Incomplete — Need Prior Mammograms for Comparison”, as appropriate. Refer to [Table 9](#) (see page 168) in Frequently Asked Question #1 in the Guidance chapter for a listing of FDA-approved equivalent wording for assessment categories.

There is a finding for which additional imaging evaluation is needed. This is almost always used in a screening situation. Under certain circumstances this assessment category may be used in a diagnostic mammography report, such as when US equipment or personnel are not immediately available, or when the patient is unable or unwilling to wait for completion of a full diagnostic examination. A recommendation for additional imaging evaluation includes the use of spot-compression (with or without magnification), special mammographic views, and US. Category 0 should not be used for diagnostic breast imaging findings that warrant further evaluation with MRI. Rather, the interpreting physician should issue a final assessment in a report that is made before the MRI examination is performed. Refer to [Frequently Asked Question #8](#) (See page 162) in the Guidance chapter for further discussion.

In most circumstances and when feasible, if a mammography examination is not assessed as negative or benign, the current examination should be compared with prior examination(s). The interpreting physician should use judgment on how vigorously to attempt obtaining prior examinations, given the likelihood of success of such an endeavor and the likelihood that comparison will affect the final assessment. In this context, it is important to note that comparison with previous examination(s) may be irrelevant when a finding is inherently suspicious for malignancy.

Category 0 should be used for prior image comparison only when such comparison is required to make a final assessment. When category 0 is used in the context of awaiting prior examinations for comparison, there should be in place a tracking procedure guaranteeing with 100% reliability that a final assessment will be made within 30 days (preferably sooner) even if prior examinations do not become available. Some mammography practices may reasonably choose never to use category 0 in the context of awaiting prior examinations simply because they do not have a 100% reliable tracking procedure. If a mammography examination is assessed as category 0 in the context of awaiting prior examinations and then the prior examinations do become available, an addendum to the initial mammography report should be issued, including a revised assessment. For auditing purposes, the revised assessment should replace the initial assessment (see the Follow-up and Outcome Monitoring section).

b. Mammographic Assessment Is Complete — Final Assessment Categories

Category 1: Negative (see Guidance chapter)

There is nothing to comment on. This is a normal examination.

Category 2: Benign (see Guidance chapter)

Like category 1, this is a normal assessment, but here the interpreter chooses to describe a benign finding in the mammography report. Involuting calcified fibroadenomas, skin calcifications, metallic foreign bodies (such as core biopsy and surgical clips), and fat-containing lesions (such as oil cysts, lipomas, galactoceles, and mixed-density hamartomas) all have characteristically benign appearances and may be described with confidence. The interpreter may also choose to describe intramammary lymph nodes, vascular calcification, implants, or architectural distortion clearly related to prior surgery while still concluding that there is no mammographic evidence of malignancy. On the other hand, the interpreter may choose not to describe such findings, in which case the examination should be assessed as negative (category 1).

Note that both category 1 and category 2 assessments indicate that there is no mammographic evidence of malignancy. Both should be followed by the management recommendation for routine mammography screening. The difference is that category 2 should be used when describing one or more specific benign mammographic findings in the report, whereas category 1 should be used when no such findings are described (even if such findings are present).

Category 3: Probably Benign (see Guidance chapter, including [Figure 155](#))

A finding assessed using this category should have a $\leq 2\%$ likelihood of malignancy, but greater than the essentially 0% likelihood of malignancy of a characteristically benign finding. A probably benign finding is not expected to change over the suggested period of imaging surveillance, but the interpreting physician prefers to establish stability of the finding before recommending management limited to routine mammography screening.

There are several prospective clinical studies demonstrating the safety and efficacy of periodic mammographic surveillance instead of biopsy for specific mammographic findings.⁴⁻⁹ Three specific findings are validated as being probably benign (noncalcified circumscribed solid mass, focal asymmetry, and solitary group of punctate calcifications). All the previously cited studies emphasize the need to conduct a complete diagnostic imaging evaluation before making a probably benign (category 3) assessment; hence, it is recommended not to render such an assessment in interpreting a screening mammography examination. The practice of rendering category 3 assessments directly from screening examination also has been shown to result in adverse outcomes: 1) unnecessary follow-up of many lesions that could have been promptly assessed as benign, and 2) delayed diagnosis of a small number of cancers that otherwise may have been smaller in size and less likely to be advanced in stage.¹⁰ Also, all the previously cited studies⁴⁻⁹ exclude palpable lesions, so the use of a probably benign assessment for a palpable lesion is not supported by robust scientific data, although there are two single-institution studies that do report successful outcomes for palpable lesions.^{11,12} Finally, because evidence from previously cited studies indicates the need for biopsy rather than continued surveillance when a probably benign finding increases in size or extent,⁴⁻⁹ it is not prudent to render a category 3 assessment when a finding that otherwise meets “probably benign” imaging criteria is either new or has increased in size or extent.

Refer to [Figure 155](#) (see page 152) at the end of the Guidance chapter for an illustration of the recommended algorithm for follow-up examinations during the entire mammographic surveillance period. While the vast majority of probably benign findings are managed with an initial short-interval follow-up (6 months) examination followed by additional examinations until long-term (2- or 3-year) stability is demonstrated, there may be occasions in which a biopsy is done instead (patient preference or overriding clinical concern).

Category 4: Suspicious ([Guidance chapter](#), see page 153)

This category is reserved for findings that do not have the classic appearance of malignancy but are sufficiently suspicious to justify a recommendation for biopsy. The ceiling for category 3 assessment is a 2% likelihood of malignancy and the floor for category 5 assessment is 95%, so category 4 assessments cover the wide range of likelihood of malignancy in between. Thus, almost all recommendations for breast interventional procedures will come from assessments made using this category. By subdividing category 4 into 4A, 4B, and 4C, as recommended in Guidance chapter and using the cut points indicated therein, it is hoped that patients and referring clinicians will more readily make informed decisions on the ultimate course of action.

Category 5: Highly Suggestive of Malignancy ([Guidance chapter](#), see page 154)

These assessments carry a very high probability ($\geq 95\%$) of malignancy. This category initially was established to involve lesions for which 1-stage surgical treatment was considered without preliminary biopsy, in an era when preoperative wire localization was the primary breast interventional procedure. Nowadays, given the widespread acceptance of imaging-guided percutaneous biopsy, 1-stage surgery is rarely, if ever, performed. Rather, current oncologic management almost always involves tissue diagnosis of malignancy via percutaneous tissue sampling to facilitate treatment options, such as when sentinel node biopsy is included in surgical management or when neoadjuvant chemotherapy is administered prior to surgery. Therefore, the current rationale for using a category 5 assessment is to identify lesions for which any non-malignant

percutaneous tissue diagnosis is automatically considered discordant, resulting in the recommendation for repeat (usually surgical) biopsy.

Category 6: Known Biopsy-Proven Malignancy ([Guidance chapter](#), see page 155):

This category is reserved for examinations performed after biopsy proof of malignancy (imaging performed after percutaneous biopsy but prior to complete surgical excision), in which there are no mammographic abnormalities other than the known cancer that might need additional evaluation.

C. WORDING THE REPORT

The current examination should be COMPARED TO PRIOR EXAMINATION(S) when appropriate. The INDICATION FOR EXAMINATION, such as screening or diagnostic, should be stated. The report should be organized with a brief description of the COMPOSITION of the breast and any pertinent FINDINGS, followed by the ASSESSMENT and MANAGEMENT RECOMMENDATIONS. ***Any verbal discussions between the interpreting physician and the referring clinician or patient should be documented in the original report or in an addendum to the report.***

The report should be succinct, using terminology from the latest approved lexicon without embellishment. Definitions of lexicon terms for mammographic findings ***should not*** appear in the report narrative. Following the impression section and the (concordant) management recommendation section of the report, both the assessment category number ***and*** FDA-approved terminology for the assessment category should be stated. Other aspects of the report should comply with the [ACR Practice Guideline for Communication: Diagnostic Radiology](#).¹³

REFERENCES

1. Kopans DB. [Basic physics and doubts about relationship between mammographically determined tissue density and breast cancer risk](#). *Radiology* 2008; 246(2):348–353.
2. Harvey JA, Gard CC, Miglioretti DL, et al. [Reported mammographic density: film-screen versus digital acquisition](#). *Radiology* 2013; 266(3):752–758.
3. 21CFR Part 16 and 900: Mammography Quality Standards; Final Rule. Federal Register, Washington, DC: [Government Printing Office, 62: No. 208; 55851-55994](#), October 28, 1997.
4. Sickles EA. [Periodic mammographic follow-up of probably benign lesions: results in 3,184 consecutive cases](#). *Radiology* 1991;179(2):463–468
5. Varas X, Leborgne F, Leborgne JH. [Nonpalpable, probably benign lesions: role of follow-up mammography](#). *Radiology* 1992;184(2):409–414.
6. Wolfe JN, Buck KA, Salane M, Parekh NJ. [Xeroradiography of the breast: overview of 21, 057 consecutive cases](#). *Radiology* 1987;165(2):305–311.
7. Helvie MA, Pennes DR, Rebner M, Adler DD. [Mammographic follow-up of low-suspicion lesions: compliance rate and diagnostic yield](#). *Radiology* 1991; 178(1):155–158.
8. Vizcaíno I, Gadea L, Andreo L, et al. [Short-term follow-up results in 795 nonpalpable probably benign lesions detected at screening mammography](#). *Radiology* 2001;219(2):475–483.
9. Varas X, Leborgne JH, Leborgne F, Mezzera J, Jaumandreu S, Leborgne F. [Revisiting the mammographic follow-up of BI-RADS category 3 lesions](#). *AJR* 2002; 179(3):691–695.
10. Kerlikowske K, Smith-Bindman R, Abraham LA, et al. [Breast cancer yield for screening mammographic examinations with recommendation for short-interval follow-up](#). *Radiology* 2005; 234(3):684–692.
11. Graf O, Helbich TH, Fuchsjaeger MH, et al. [Follow-up of palpable circumscribed noncalcified solid breast masses at mammography and US: can biopsy be averted?](#) *Radiology* 2004; 233(3):850–856.
12. Harvey JA, Nicholson BT, LoRusso AP, Cohen MA, Bovbjerg VE. [Short-term follow-up of palpable breast lesions with benign imaging features: evaluation of 375 lesions in 320 women](#). *AJR* 2009; 193(3):1723–1730.
13. American College of Radiology. ACR Practice Guideline for Communication: Diagnostic Radiology. http://www.acr.org/~media/ACR/Documents/PGTS/guidelines/Comm_Diag_Imaging.pdf. Accessed November 4, 2013.