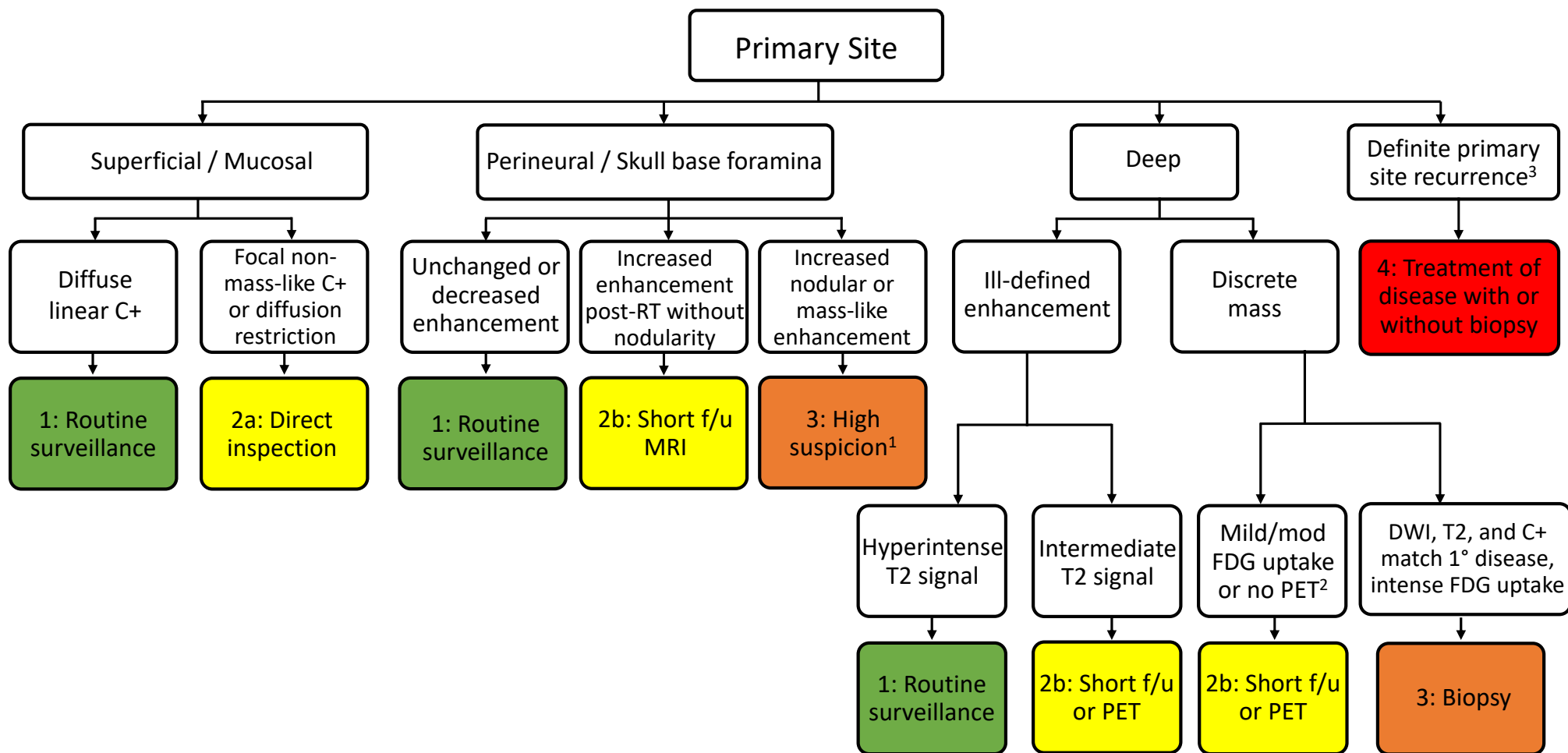


NI-RADS™ MRI v2025 Primary Site Assessment Categories – Algorithm



¹ Biopsy is commonly recommended for high suspicion findings but may not be feasible in many perineural locations. In such cases, multidisciplinary discussion to decide the best next step in management of the high suspicion imaging finding is often appropriate.

² Soft tissue with MRI features different from original tumor (DWI, enhancement, T1/T2 signal) is designated as 2b. Note that a flap may have different enhancement and signal characteristics from original tumor.

³ Based on pathologic confirmation or definitive radiologic progression. Biopsies may be needed so that patients can enroll in a trial or otherwise continue with treatment.