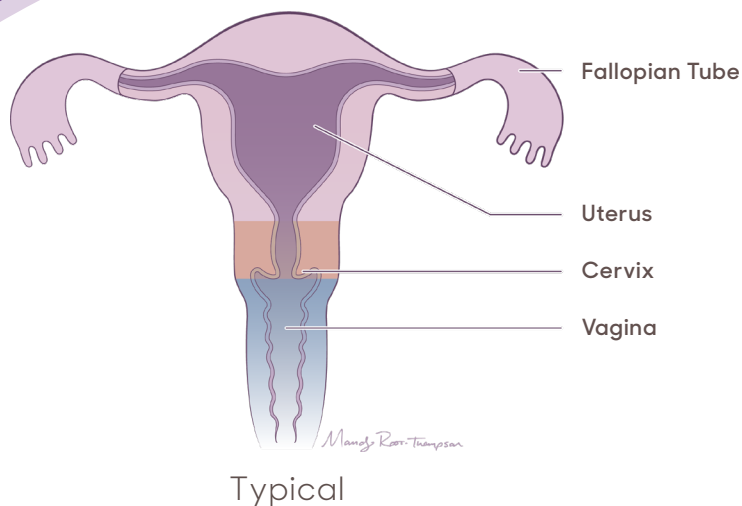
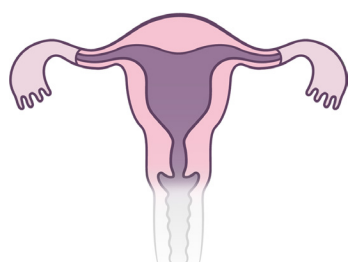


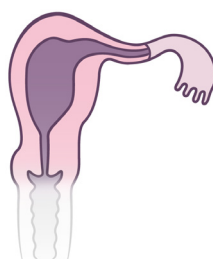MÜLLERIAN Anomalies



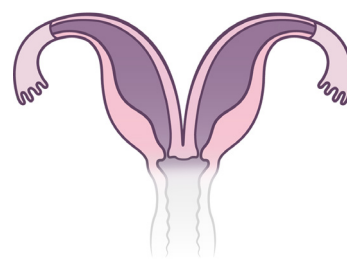
Fallopian tubes/Uterus



Single uterus



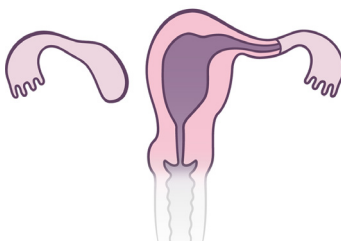Unicornuate uterus



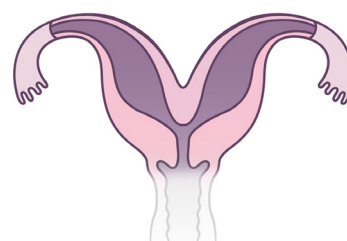
Uterus didelphys



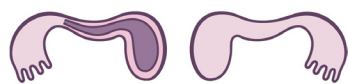
Müllerian agenesis



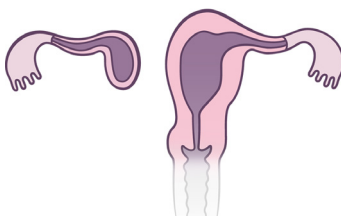
Unicornuate uterus with atrophic uterine remnant



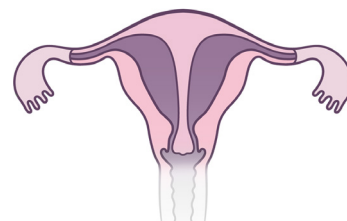
Bicornuate uterus



Müllerian agenesis with atrophic and/or functional uterine remnant



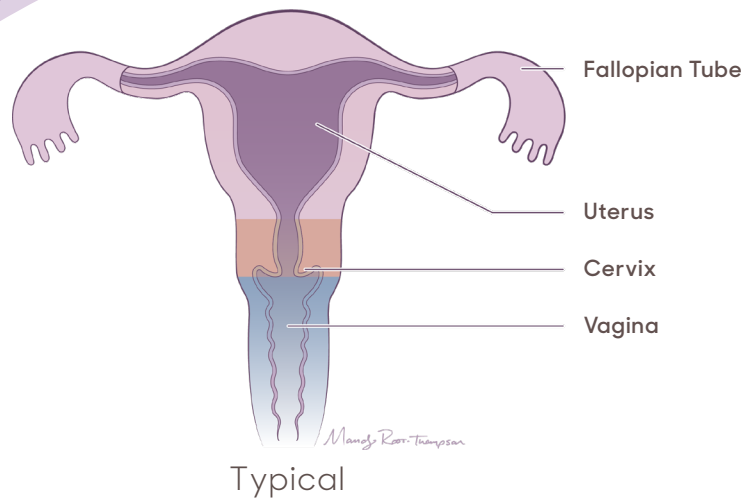
Unicornuate uterus with functional uterine remnant



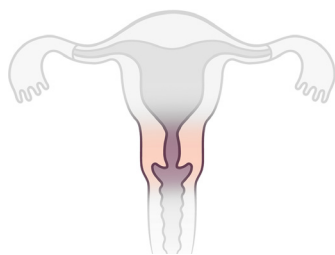
Complete septate uterus



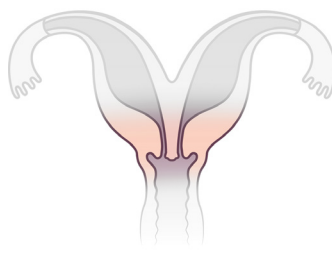
MÜLLERIAN Anomalies



Cervix

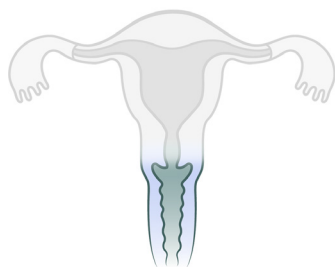


Single cervix

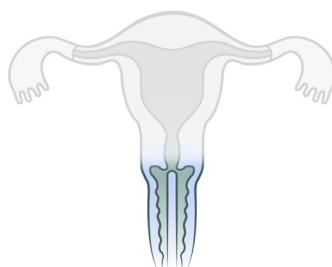


Duplicated cervix

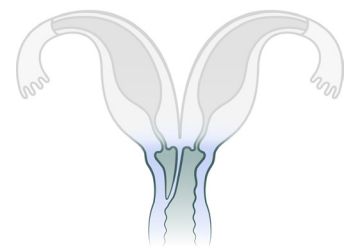
Vagina



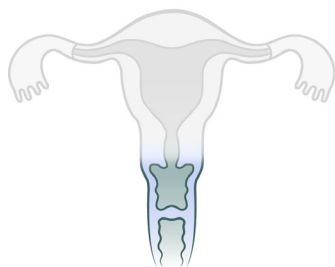
No septum



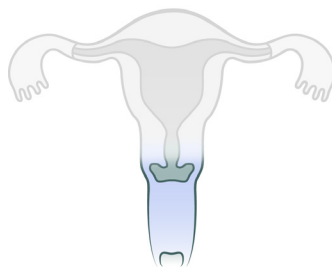
Longitudinal septum



Longitudinal septum
with obstructed
hemivagina



Transverse septum



Distal vaginal
agenesis (atresia)

